

Comparative Study Between Ligation Versus Clipping Methods of Appendicular Base in Laparoscopic Appendectomy

Abbas M* and Seleem A

Department of Surgery, Al-Azhar University, Egypt

*Corresponding author:

Mohammed Abbas,
Department of Surgery, Al-Azhar University,
Egypt, E-mail: karimabdel2013@outlook.com

Received: 12 Feb 2022

Accepted: 04 May 2022

Published: 12 May 2022

J Short Name: COS

Copyright:

©2022 Abbas M. This is an open access article distributed under the terms of the Creative Commons Attribution License, which permits unrestricted use, distribution, and build upon your work non-commercially.

Citation:

Abbas M. Comparative Study Between Ligation Versus Clipping Methods of Appendicular Base in Laparoscopic Appendectomy. Clin Surg. 2022; 7(10): 1-7

Keywords:

Ligation; Clipping; Laparoscopic appendectomy

1. Abstract

1.1. Background: Nowadays Laparoscopic approach for appendectomy is more used rather open approach for cases of acute appendicitis. Most surgeons preferred laparoscopic appendectomy as minimal access surgery. There are many methods for closing of appendicular stump as stapling, ligation and clipping.

1.2. Aim: This study is aimed to compare between two ligations and clipping techniques regarding its safety, operative time, post-operative outcome and complications.

1.3. Patients and Methods: A randomized prospective clinical trial study included 150 patients with acute appendicitis. The patients were randomly distributed into 2 main groups (A, B): In 75 patients we secured the base of the appendix by ligation method (group A) and in 75 patients by clip Application (group B).

1.4. Results: There was no significant statistical difference between the two groups as regard drain insertion or conversion to open appendectomy. Four patients within ligation group (A) had been converted to open due to presence of base gangrene while six patients within clipping group (B) had been converted to open due to gangrenous base and intra-operative bleeding. Two cases in clipping group (B) had been converted to ligation techniques due to wide base which can't be secured by clip application.

1.5. Conclusion: Both methods were effective, safe, and almost same in Complications rates. Clip application consumed less operative time cause of easy application so it doesn't require more experience or training.

2. Introduction

Acute appendicitis is considered one of most common causes of acute surgical abdomen worldwide. The exact cause of inflammation in acute appendicitis still not known but the most accepted theory is obstructive one which explained that the inflammation occurs secondary to the lumen obstruction (closed-loop obstruction) with accumulation of bacteria and inflammatory mediators.

Increasing in intra luminal pressure results in endothelial tear which allows invasion of the appendicular wall by bowel organisms leading to more inflammation of the wall [1]. When luminal pressure more increased, this leads to thrombosis of the venules and obstruction of lymph vessels that drain the appendix in spite of continued arteriolar flow which leads to vascular congestion and engorgement of the appendix. Lymphatic and venous drainages are impaired and ischemia develops [2].

Acute appendicitis commonly presented by acute right lower abdominal pain, nausea and or vomiting. During examination there is tenderness over right iliac fossa with rebound tenderness, rebound tenderness and rigidity.

Because of clinical presentation of acute appendicitis is usually conflicts with many causes of acute abdomen Several diagnostic scores have been developed to increase the diagnostic accuracy in acute appendicitis as Alvarado Score, RIPASA Score, Tzanakis Score, Lintula score and many other scores [3].

In addition to clinical diagnosis laboratory investigations as c.b.c and urine analysis can help in diagnosis.

Abdominal ultrasonography (U.S) using superficial probe and abdominal computerized tomography scanning (C.T) with contrast could be used in doubtful cases to ensure diagnosis.

The laparoscopic surgery allows a full exploration of the peritoneal cavity, so it is used as diagnostic tool in case of acute and complicated appendicitis [4].

When appendicular mass identified, there is debate if it should require early surgery, or, whether conservative treatment is most appropriate [5].

After conservative treatment a delayed appendectomy 6-8 weeks later, even if the mass resolved on conservative treatment. However, about 15 -20% of patients will be readmitted with similar symptoms before the interval appendectomy [6].

Urgent open appendectomy was the routine treatment of acute appendicitis for many years ago but nowadays after the era of laparoscopy most of both patients and surgeons preferred the laparoscopic approach in order to avoid complications of open method especially wound infection, seroma and muscle cutting with prolonged hospital stay and delayed return to daily activity.

There are many methods for securing the base of the appendix during laparoscopic appendectomy, some of which are expensive others are not available or technically demanding including stapling, clipping, extracorporeal or intra-corporeal ligation or ligation using endo-loop [7].

The aim of this study is to compare between two methods including ligation and clipping techniques regarding feasibility, safety, efficacy, operative time, postoperative outcome and complications.

3. Patients and Methods

A randomized prospective clinical trial study included 150 patients with acute appendicitis during the period from March 2017 to March 2020 in general surgery department BAB ALSHERIA hospital- ALAZHAR university.

The patients were randomly distributed into 2 main groups (A, B): group (A): Ligation Group included (75) patients, group (B): clipping Group included (75) patients.

This study included all cases of acute appendicitis with age between 14-40 years and candidate for laparoscopic appendectomy.

We excluded patients with Appendicular mass, Cases with perforation at the base or generalized peritonitis, Cases with Appendicular Abscess formation and Patients which are not fit for laparoscopic surgery.

Classic history taking and clinical examination done for all patients. Radiological investigation: abdominal ultrasonography was routinely done for confirmation of diagnosis in all patients. Abdominal CT with contrast was requested only when indicated in suspicion of complications. All patients received pre-operative prophylactic dose of 2 gm 1st generation cephalosporin one hour

before the operation.

4. Surgical Techniques

We used 3 ports; the first (optic port, 10mm) was inserted just above the umbilicus. We used 0 ° telescope. The second port (5mm) was inserted in the left iliac fossa through which we inserted a non-traumatic grasper to do manipulation of viscera to do diagnostic laparoscopy. The third port (5mm) was inserted in the suprapubic region as showed in (figure1). The patient position in the Trendelenberg position with slight tilt to the left side for good exposure of the caecum.

After insertion of ports and positioning of the patient we start to identify the cecum and appendix then we hold appendix up and dissect any adhesions then start devascularization of mesoappendix using ligasure or diathermy hook till the base in group A and B (figure 2).

Then in ligation group we used a ligature of Vicryl 2/0 intra corporeal Knots in 25 cases, extracorporeal ligature in 25 cases and Endoloop ligation in 25 cases (Figure 3).

In clipping group 2 or 3 Titanium clips applied on the base the size of clip is adjusted according to base diameter (Figure 4).

After division of appendix we used a collecting bag for extraction from umbilical port after changing the camera to the left iliac fossa port. Then deflation of gas and port site closure using vicryl 3/0 threads.

All patients admitted for one-day post operatively discharged on second day appointed for follow up in outpatient clinic after 7 days for stitch removal.

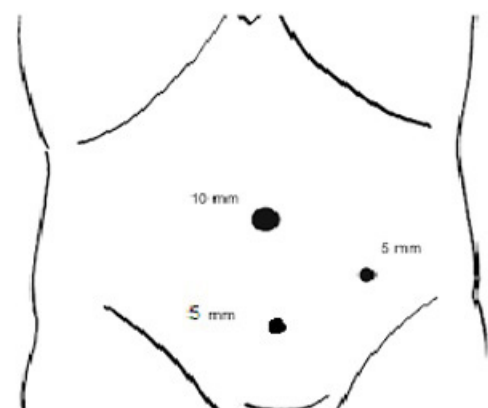


Figure 1: Showing the sites and sizes of ports used in laparoscopic Appendectomy.

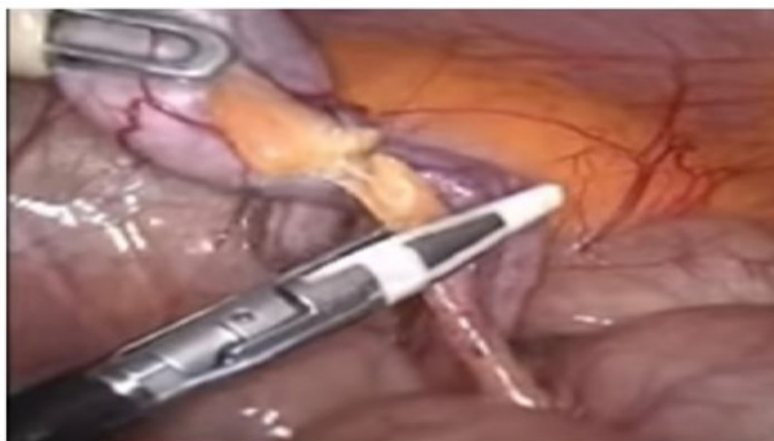


Figure (2A): Showing dissection of mesoappendix using ligasure device.

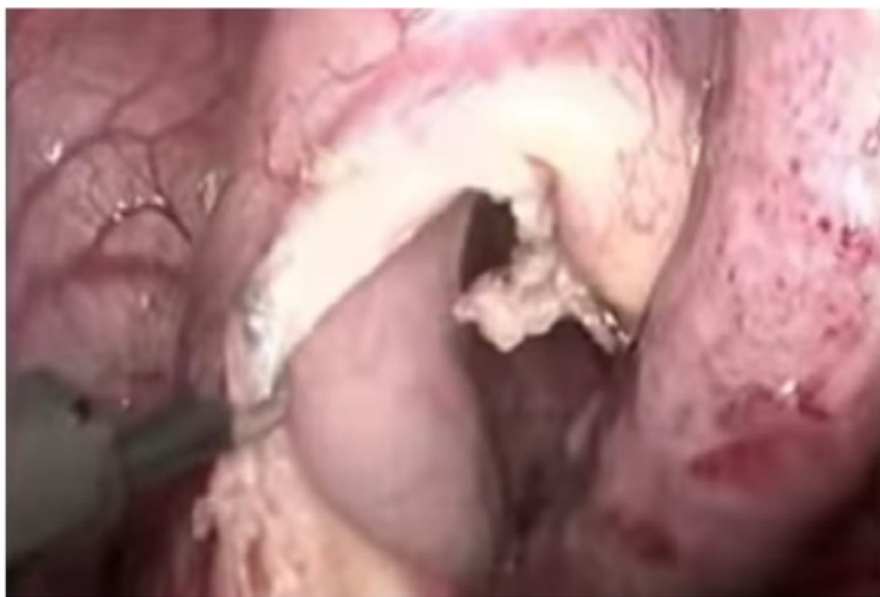

Figure (2B): Showing dissection of mesoappendix using hook instrument.

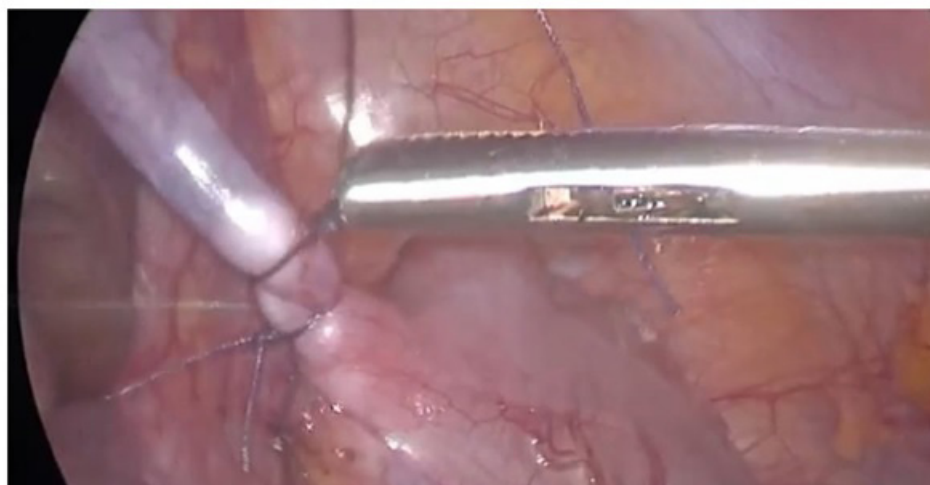


Figure (3A): Showing intracorporeal ligation of appendicular base using vicryl suture.

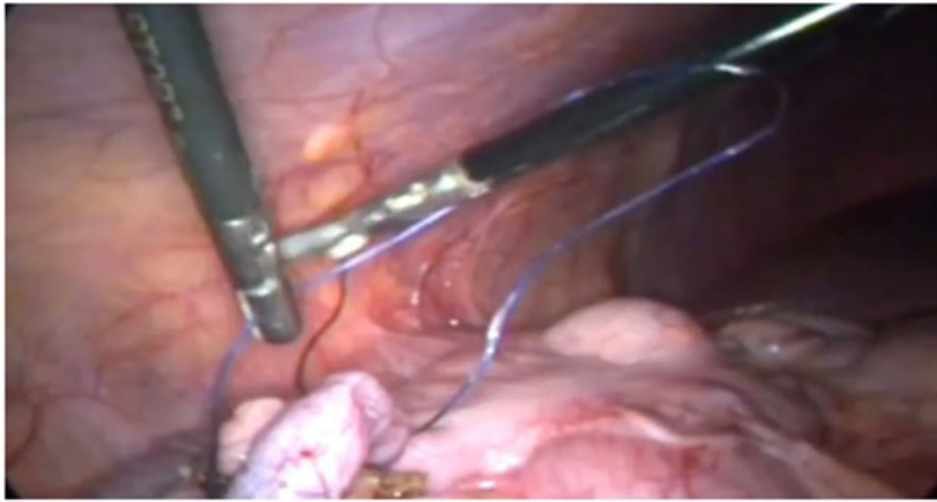


Figure (3B): Showing extracorporeal ligation of appendicular base.

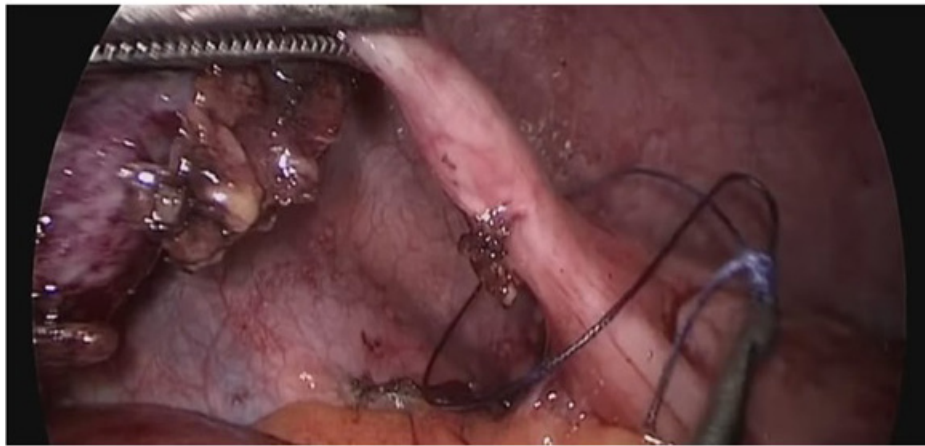


Figure (3C): Showing ligation of the appendicular base using vichryl endoloop.

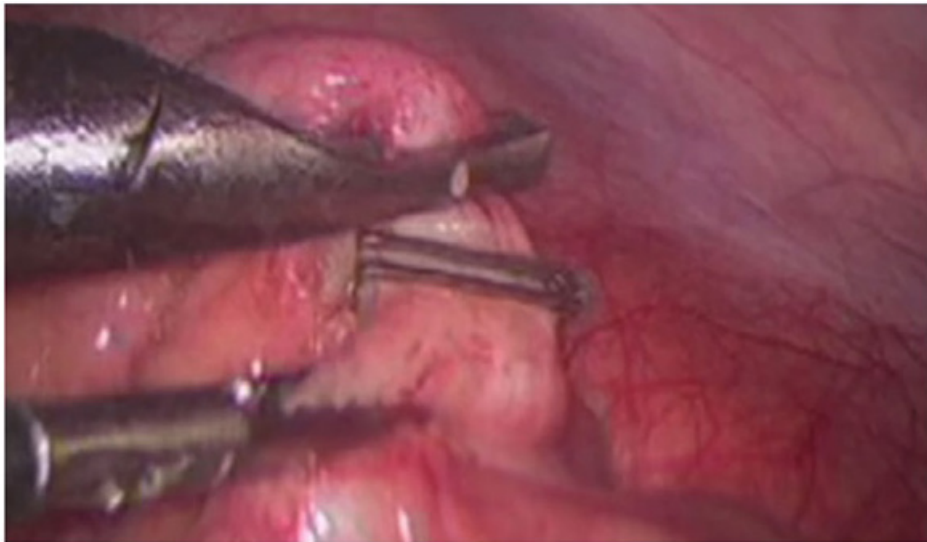

Figure 4: Showing closure of appendicular base using metallic titanium clips.

5. Statistical Review

The data collected and processed using the SPSS (Statistical Package for Social Sciences) version 21. Quantitative data was presented as mean \pm SD. Qualitative data was presented as number and percentages. P value $<$ 0.001 was considered to be statistically significant.

According to collected data there was no a significant statistical difference between both methods regarding demographic characteristics (Table 1).

There was a significant statistical difference between two groups as regarding operative time which was longer in ligation group A (Table 2).

There is statistically non-significant difference between both techniques as regarding the hospital stay (Table2).

There is statistically non-significant difference between patients underwent different surgical techniques as regarding application of peritoneal drain or conversion to open. Four patients within ligation group (A) had been converted to open due to presence of base gangrene while six patients within clipping group (B) had been converted to open due to gangrenous base and intra-operative bleeding.

Two cases in clipping group (B) had been converted to ligation techniques due to wide base which can't be secured by clip application (Table 3).

As regarding presence of postoperative complications as fever, post-operative collection, port site infection, bleeding, intestinal obstruction, there was no significant statistical difference (Table 4).

Table 1: Comparison of demographic distribution of patients in both groups.

		Group(A) Ligation N=75(%)	Group(B) Clipping N=75(%)	P value
Gender	Male	39(52)	42(56)	0.995
	Female	36(48)	33(44)	
Age	Mean \pm SD	25.2 \pm 9.36	26 \pm 10.42	0.678
	Range	15-52	14-55	

Table 2: comparison between two groups as regards operative time and hospital stay.

		Group(A) Ligation N=75(%)	Group(B) Clipping N=75(%)	P value
Operative Time	Mean \pm SD	40 \pm 11.5	20 \pm 8.2	$>$ 0.001
	Range	30-45	18-30	
Days of Hospital Stay	Mean \pm SD	1.11 \pm 0.15	1.32 \pm .2	0.678
	Range	1_3	1_2	

Table 3: comparison between two groups as regard conversion to open, conversion of clipping to ligation or application of intra peritoneal drain.

	Group(A) Ligation N=75(%)	Group(B) Clipping N=75(%)	P value
Application of peritoneal drain	5 (6.6)	6(8)	0.293
Conversion to open:	4(3)	6(4.5)	0.385
Conversion to ligation due to very wide base :		2(2.6)	

Table 4: Comparison between ligation (A) and clipping (B) techniques as regarding postoperative complications.

	Group(A) Ligation N=75(%)	Group(B) Clipping N=75(%)	P value
Fever	1(.75)	2(1.5)	0.561
Post operative collection	3(2.25)	2(1.5)	0.293
Bleeding	1(.75)	1(.75)	$>$ 0.999
port site infection	2(1.5)	3(2.25)	0.293

6. Discussion

Proper Closure of appendicular base before division of appendix is very important step to avoid major post-operative complications such as peritonitis, faecal fistula formation, and peritoneal sepsis. In laparoscopic appendectomy, ligation of the appendicular base can be difficult because intracorporeal ligation needs more laparoscopic training and the surgeon may be doubt about the reliability of the knot, So, many surgeons searching for other simple and safe methods for appendicular stump closure [7].

Many methods of closure are tried and used for example extracorporeal ligation, end-loop, titanium clips, stapler and handmade loops. The most appropriate method still remains to be a controversy [8].

In our study, we compared between two methods for closure of the appendicular base (ligation and clipping) as regard safety, competence and complications related to each technique. In current study, male represented 56% and female represented 44% of the operated patients by titanium clipping. In Dixit and Gogate study where male represented 63.3% and female represented 36.7% of the operated patients [9].

In our study, male represented 55.6% and female represented 44.4% of the operated patients by polymeric clips. Also, this in agreement with Reinke and colleagues study where male represented 44% and female represented 56% of the operated patients [10].

In this study the mean operative time was 40 minutes among patients operated by ligation. In another study of Sheishaa and colleagues the mean operative time was 54.6 minutes [11].

In our study, the mean operative time among patients operated with polymeric clip application was 25 minutes. In Reinke and colleagues study the mean operative time was 45 minutes [10].

Our study concurs with Kiudelis and others which revealed that intra-corporeal ligation is a safe technique, and cheaper than end loops but it needs more training for beginners. Compared with laparoscopic staplers, end loops have an advantage as they are cheaper than stapling device [12].

Also, our results confirmed by a study of Deans and others reported that using absorbable clip can achieve a high degree of intraluminal pressure and lowering the cost, beside their use is acceptable for securing the appendicular stump [13].

Our study matched with results of other studies, that using of metallic clips for appendicular stump closure is safe with less operative time due to simple application of the clip in laparoscopic appendectomy and also it provides a useful alternative of intra-corporeal ligation [14].

In addition, the ideal suture material should be biocompatible and react less to tissue. The ideal method for appendix stump closure in laparoscopy should be technically easy to use, safe, readily acces-

sible, and reliable, with less operative duration and less cost [7].

In our current study, the gangrene and or friability of the base in some cases is considered as limitation for both techniques which may lead us to open appendectomy to ensure safe stump closure to avoid post-operative stump leakage or fistula.

7. Conclusion

Both Ligation and clipping of appendicular base were effective, safe, feasible and the same in complications rate. Ligation method is related to more operative time and needs more training than clipping method which is easier and simpler for trainers.

References

- Horton LW. "Pathogenesis of acute appendicitis" *British Medical Journal*. 1977; 2: 1672-73.
- Abbas PI, Zamora IJ, Elder SC, Brandt ML, Lopez ME, Orth RC, et al., "How Long Does It Take to Diagnose Appendicitis? Time Point Process Mapping in the Emergency Department". *Pediatric Emergency Care*. 2018; 34: 381-84.
- Chong CF, Thien A, Mackie AJ, Tin AS, Tripathi S, Ahmad MA, et al., "Comparison of RIPASA and Alvarado scores for the diagnosis of acute appendicitis". *Singapore Med J*. 2011; 52: 340-5.
- Schwartz S. "Appendix. Cited by Seymour, I. Schwartz. Principles of surgery". 17th edition. McGraw Hill Inc; 2012; 2: 1315-26.
- Minutolo V, Licciardello A, Di Stefano B, Arena M, Arena G, Antonacci V. Outcomes and cost analysis of laparoscopic versus open appendectomy for treatment of acute appendicitis: 4-years' experience in a district hospital. *BMC Surgery*. 2014; 14: 14.
- Daniel R, Courtney M, Mark B, et al., "Sabiston textbook 19th edition" chapter. 2017; 51: 1279 – 91.
- Palanisamy V, Vinoth S, Rajan V, Ramanathan M. Review of techniques in occluding appendicular stump during laparoscopic appendectomy. *J Surg (Jurnalul de chirurgie)*. 2019; 15: 1-4.
- Sahm M, Kube R, Schmidt S, Ritter C, Pross M, Lippert H. "Current analysis of endoloops in appendiceal stump closure". *Surg Endosc*. 2011; 25: 124–9.
- Dixit N, Gogate AS. "A comparison of titanium clips versus Roeder's knot tying suture in laparoscopic appendiceal stump closure". A 1-year randomized controlled trial study in KLES Dr. Prabhakar Kore Charitable Hospital, Belgaum. *Indian j health sci*. 2016; 9: 49-55.
- Reinke C, Tabone L, Fong P, Yoo JS, Park CW. "Safety and Efficacy of Polymeric Clips for Appendiceal Stump Closure". *Journal of the Society of Laparoendoscopic Surgeons*. 2016; 20: 45.
- Abou-Sheishaa M, Negm A, Abdelhalim M, Abbas A, Ibrahim M, Elghadban H, et al., "Ligation versus Clipping of the Appendicular Stump in Laparoscopic Appendectomy: A Randomized Controlled Trial". *Ann Emerg Surg*. 2018; 3: 1029.
- Kiudelis M, Ignatavicius P, Zviniene K, Grizas S. Analysis of Intracorporeal knotting with invaginating suture versus endoloops in Appendiceal stump closure. *WideochirInne Tech. MaloInwazyjne*.

2013; 8: 69-73.

13. Deans GT, Wilson MS, Brough WA. The ability of laparoscopic clips to with stand high intraluminal pressure. Arch. Surg. 1995; 130: 439-41.
14. Ates M, Dirican A, Ince V, Ara C, Isik B, Yilmaz S. comparison of intra-corporeal knot-tying suture (polyglactin) and titanium endoclips inlaparoscopic appendiceal stump closure: A prospective randomized study. Surg. Laparosc. Endosc. Percutan. Tech. 2012; 22: 226- 31.