

# Trigonocephalia a Curable Craniosynostosis. Case Report

Luces OAR<sup>1\*</sup>, Luces OR<sup>2</sup>, Millian C<sup>3</sup>, Lara G<sup>4</sup>, Mejias W<sup>5</sup>, Perdomo Y<sup>6</sup> and Dumoulins W<sup>7</sup>

<sup>1</sup>Specialist in general surgery and laparoscopy and General urologist of the Venezuelan Institute of Social Security (IVSS), Universidad de Oriente, Barcelona, Anzoátegui - Venezuela

<sup>2</sup>Pediatric surgery specialist, Physician of the State Institute of Sports of Anzoátegui (IDEA), Universidad de Oriente, Barcelona, Anzoátegui - Venezuela

<sup>3</sup>Specialist in Pediatric Neurosurgery or Children, Doctor of the Venezuelan Institute of Social Security (IVSS), Dr. Cesar Rodríguez Rodríguez Hospital, Puerto la Cruz – Venezuela

<sup>4</sup>Specialist in Pediatric Neurosurgery or Children, Dr. J. M. de los Ríos Children's Hospital I, Caracas - Venezuela

<sup>5</sup>Specialist in Pediatric Neurosurgery or Children, Dr. Jose Maria Vargas Hospital, Caracas – Venezuela

<sup>6</sup>Postgraduate resident of general surgery, Hospital Dr. José Ignacio Baldo, Caracas – Venezuela

<sup>7</sup>Specialist in general surgery and laparoscopy, Head of the surgery service, Doctor of the Venezuelan Institute of Social Security (IVSS), Dr. Cesar Rodríguez Rodríguez Hospital, Puerto la Cruz - Venezuela

<sup>8</sup>Medical surgeon - biostatist, Puerto la Cruz - Venezuela

Volume 2 Issue 3- 2019

Received Date: 03 Dec 2019

Accepted Date: 20 Dec 2019

Published Date: 30 Dec 2019

## 2. Key words

Trigonocephaly treatment; Craniosynostosis; Metopic suture; Invasive surgical technique

## 1. Trigonocephalia A Curable Craniosynostosis. Case Report

The Trigonocephaly is premature fusion of the metopic suture (part of the frontal suture which joins the two halves of the frontal bone of the skull) in which a V-shaped abnormality occurs at the front of the skull. It is characterized by a triangular prominence of the forehead and eyes close together, has implications for neurological injury secondary variables to the deformity. The reasons for the anterior fossa surgery are reduced in size and orbits with abnormal spatial arrangement leads secondarily to disturbances in vision (strabismus) and intracranial hypertension. We want to describe a clinical case of Trigonocephaly from the Neurosurgery Service of the IVSS Hospital Dr. Cesar Rodríguez, describes the case of an 11-month-old patient, Male sex with no history of illness, siendo un primer pregnancy, controlled, simple eutocic delivery without complications, who entered the outpatient service in November. The physical examination presents good general condition, after having suffered frequent crying and irritability for 2 months. The purpose of surgery is to perform a complete orbitofrontal osteotomy in addition to resection of the metopic suture, which includes both orbital roofs and the pterional region, resulting in remodeling of the front. Trigonocephaly is a type of craniosynostosis, must have an early surgical treatment. The immediate postoperative changes are satisfactory, in the immediate postoperative period their appreciation for the aesthetic appearance, about 24 to 48 hours has a progressively diminishing facial edema, also fixes harmonious and spontaneous intracranial hypertension.

## 3. Introduction

The pediatrician needs to be able to differentiate true craniosynostosis that affect the surgical treatment of positional deformities. The premature fusion of one or several skull sutures produces well-recognized patterns of deformity, both cranial and facial, in which, in addition to the child's deformity, serious

functional complications sometimes arise related to breathing, feeding and vision [1]. Craniosynostosis has variable implications for neurological injury secondary to deformity. Current studies have shown the presence of alterations in the cerebral cortex underlying the fused suture by magnetic resonance imaging. However, there are discrepancies as to whether this is the consequence of the

*\*Corresponding Author (s): Odionnys Antonio Ramos Luces, Specialist in general surgery and laparoscopy and General Urologist of the Venezuelan Institute of Social Security (IVSS), Universidad de Oriente. AV. University, Anzoátegui-Venezuela, Tel: (0058) 02812682809; 04265808668, E-mail: odywan66@yahoo.es*

premature fusion of the suture or simply the cause of the fusion. Some authors carried out psychological tests in order to know how the development of patients affected by a simple craniostenosis was and found that the percentage of patients with a psychomotor development index below normal was higher in patients with craniostenosis than in the normal population [2]. It is a relatively common birth defect with an estimated incidence of 1 / 2,100-1 / 2,500 children [3].

Trigonocephaly within all craniosynostosis occur in approximately 18% of cases, with a clear predominance of scaphocephaly (35%); Brachycephaly (24.9%) and Plagiocephaly (21.6%) and lastly, Oxycephaly (11.6%). It occurs in the same proportion between both sexes. Very little is known about the etiology. So far, the arguments to prove autosomal recessive inheritance are not convincing. Although trigonocephaly is a fundamental characteristic of the 9p-7-9 syndrome, it can also appear in other chromosomopathies such as 6q+, 7p-, 13q+, 14p+ and 18p [3]. This consists of the early closure of the metopic suture. It is a relatively rare craniostenosis. However, the frontal deformity - keel skull - with the prominence in the midline corresponding to the sinostotic suture allows it to be easily identified. The degree of deformity can be variable, from a purely cosmetic defect caused by the prominence of the midline, to accentuated defects with retrusion of the superior and external flanges of the orbit, hypotelorism and axis of the oriented orbit from inferolateral to superomedial and with Posterolateral rotation of the orbit [4]. The reasons for the indication for surgical treatment are decreased anterior fossa and orbits with anomalous spatial arrangement, which will lead secondarily to vision disorders (strabismus). In accordance with the above, the surgery will consist of the remodeling of the frontal shell with elimination of the prominence of the metopic suture and advancement of the superoexternal flange of both orbits with placement of a bone graft at the level of the skull base in order to eliminate the hypotelorism.

#### 4. Case Report

It is presented under the signature of responsibility of the informed consent of their parents, an 11-month-old male patient, without a history of illness, whose parents were adolescents of 17 years in 2010, child product of the first pregnancy, fully controlled pregnancy with 8 controls prenatal, simple eutocic delivery without complications, birth weight of 2640 grs and height at

birth of 49 cms. In September, at 7 months of age, he attended Dr. Luis Ortega de Porlamar hospital, Nueva Esparta, where he was diagnosed with trigonocephaly type craniosynostosis and was immediately referred to Dr. Cesar Rodríguez IVSS hospital in Puerto La Cruz-Anzoátegui, entered the neurosurgery service of the mentioned hospital in November. In good general condition after having suffered frequent crying for two months, that after evaluating the case a possible surgical treatment is suggested. He was hospitalized in December where he shows up. The neurological examination shows wakefulness, spontaneous activity, attention to the environment, reactivity, response to stimuli. Behavior, activity, affectivity, communication, interest in the environment, neck reflex and pressure preserved, sensitivity preserved (Figure 1).

The admission laboratory test showed a hematocrit of 31.3%, hemoglobin at 10.1g / dl, leukocytes 8800, segmented 50%, lymphocytes 45%, platelets 162,000, glycemia 91 mg / dl, urea 20.4 and creatinine in 02, blood group O, Rh negative factor, with normal thromboplastin and thrombin time. Skull X-rays were performed where no fracture traces are observed as well as lytic or blastic lesions, partial sinostosis is seen that compromises the sagittal suture in its anterior portion and the coronal suture, with normal orbital ridges and normal facial massif bone structures (Figure 2, Figure 3). The simple brain CT (Figure 4) in which deformity characterized by pointed frontal region was evidenced, trigonocephaly type craniosynostosis is observed as a result of the early closure of the mitotic suture, prominence of the ventricular system, with no evidence of hypodense areas that suggest ependymal transduction of the cerebrospinal fluid, normal anatomic variant in infants, left temporobasal extracerebral hypodense area compatible with arachnoid cyst.

#### 5. Surgical Treatment

Surgical treatment after anesthetic induction, the patient is intubated orotracheally and placed in a neutral supine position. The objective of the surgery is to perform a complete fronto orbital osteotomy in addition to the resection of the metopic suture, which includes the orbital ceilings and the pterional region, a remodeling of its forehead originates (Figure 5), the adjustment in two halves of this, and interposition of a graft taken from the posterior flange of the craniectomy to annul the keel, through a bicoronal access, a soft flap is made towards the face, parasagittal and paratemporal

holes are made (Figure 6), a frontal bone craniotomy, plus a classic caudal lateral advance. An attempt is made to raise the fronto-orbital bar to the level of the lateral margins of the orbit, to avoid entering the temporal fossa, which is partially achieved. The advance is also achieved and the frontal bone is replaced, molded and interposed. Once the advance is achieved, the frontal bone is left floating (Figure 7), the hemostasis is checked and the portovac drained, then an operative wound synthesis is performed by planes (Figure 8). The patient receives a 300 cc globular concentrate during surgery.

The patient evolved favorably, a febrile, recovering spontaneous activity, attention to the environment, reactivity conserved, response to stimuli. Behavior, activity, affectivity, communication, e interest in the environment adecuad (Figure 9-10), remain hospitalized for 10 days with medical treatment with cefazidal (30 mg / kg / day).

## 6. Discussion

The closure of the metopic suture begins in normal conditions around the end of the first year of life and is the first of the large sutures to close towards the end of the second year 6. When an early closure of the same occurs, usually in the intrauterine period, a characteristic craniofacial malformation called trigonocephaly occurs [7]. This is considered a relatively frequent type of craniosynostosis and is considered to be approximately 10% of all patients treated in a Craniofacial Surgery Unit [5-8]. Although the trigonocephaly classically has been classified in the group of simple craniosynostosis, the resulting deformity responds to a broad phenotypic spectrum depending on the extent and the time at which the closure of the metopic suture begins. The milder forms of trigonocephaly have only a slight crest in the midline of the frontal region, and do not usually require surgical correction, except for aesthetic reasons. In the most severe cases there is an affection of the anterior chondrocranial structures that give rise to the characteristic "keel" front, with retrusion and obliqueness of both frontal bones, disappearance of the frontal eminences, hypoplasia of both supraorbital ridges that are also found destroyed, epicanth fold and hypoteleorbitism [6, 9].

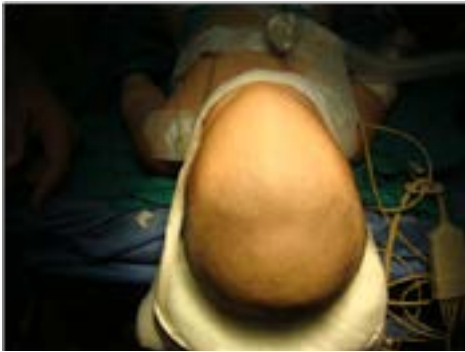It is precisely these last deformities that are the most characteristic and that determine the final aesthetic result in most cases [10, 11]. A wide variety of techniques have been used for the surgical treatment of trigonocephaly, all of them with very satisfactory

result [5, 9, 12-14]. The classic approach consists of a complete frontoorbital remodeling by bifrontal craniotomy followed by orbital osteotomies, with or without disassembly and remodeling of the frontoorbital bar, and "tongue-in-groove" advancement or at least expansion of both pterional regions [6, 14]. All these techniques have achieved very good results in terms of the immediate correction of the deformities while remaining stable over time. However, the need for a bicoronal incision, subperiosteal exposure, wide osteotomies and bone mobilizations involve a considerable approach, with long surgical times, blood losses that often require transfusions in the surgical act or in the immediate postoperative period, and a prolonged hospital stay mainly due to soft tissue inflammation caused by the wide detachment of the structures of the operative field. In the current state of craniofacial surgery, the emphasis of the postoperative results has been deposited not only in the correction of the deformity and release of the intracranial organs and systems "incarcerated" by the sinostosis (cerebral parenchyma, CSF, airway, vision) but mainly in the aesthetic aspect after the intervention and the maintenance of the favorable results in the long term. This is more true in so-called "simple" craniosynostosis or in milder ones, in which there is a "single" affected suture.

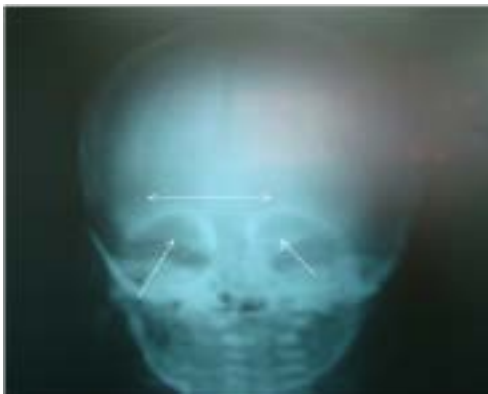
## 7. Conclusion

Trigonocephaly is a type of craniostenosis that, depending on the degree of structural compromise, has implications for psychic development as well as important morphological type of frontonasal type causing hypotelorism, so early surgical treatment is essential where in addition to fracturing the frontal for remodeling and rotation it is necessary release the supra orbital bar, advance it by bone grafts, leave the floating forehead, and thus release the pressure on the frontal lobes and correct the hypotelorism. The immediate post-surgical changes are very satisfactory, in the immediate postoperative period there is a pleasure on the part of the parents for the aesthetic appearance achieved, it should be noted that around 24 to 48 hours they will present an important facial edema that progressively decreases between 4 to 7 days In addition, this surgical act is allowed to correct, harmonic and spontaneously, endocranial hypertension. At present we must think that with the appearance of multidisciplinary teams in the Craniofacial Surgery Units that have allowed a considerable reduction in the incidence of morbidity and mortality even in the

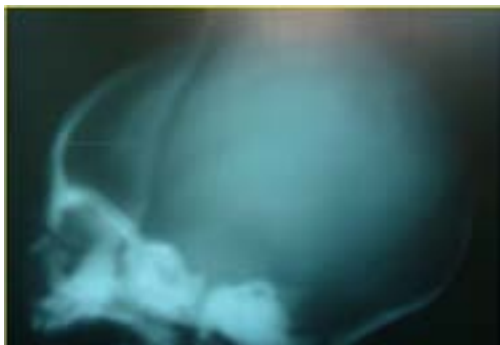case of more complex craniofacial syndromes, in the possibility of offering minimally invasive techniques through endoscopically assisted osteotomies for some of these malformations it allows reducing the number of complications, as well as shortening the surgical time, blood loss and postoperative hospital stay compared to conventional craniofacial surgery techniques.



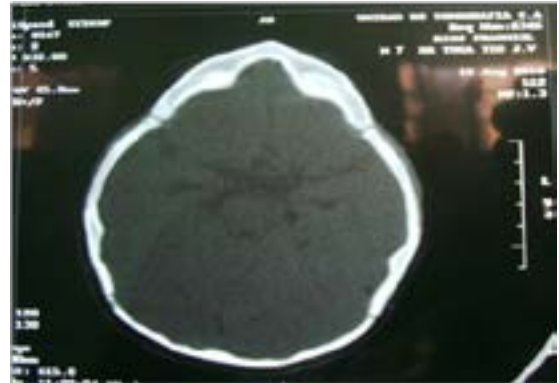**Figure 1:** Patient in an operative bed shows an inverted V-shaped abnormality in the front of the skull.



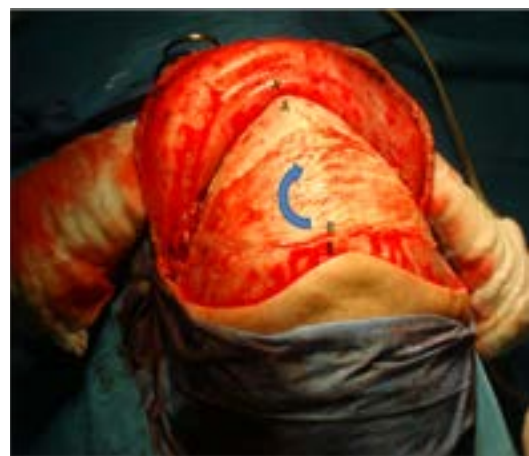**Figure 2:** Partial sinostosis that involves the sagittal suture in its anterior portion and the coronal suture, with normal orbital ridges.



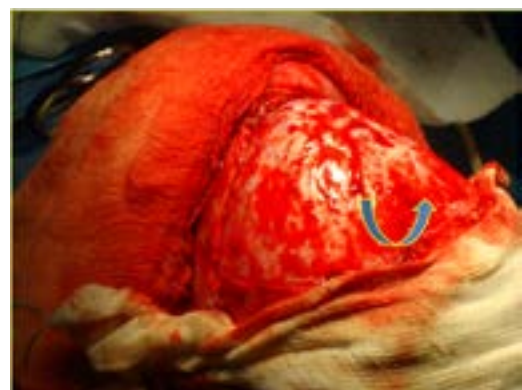**Figure 3:** Bone structures in normal facial massif.



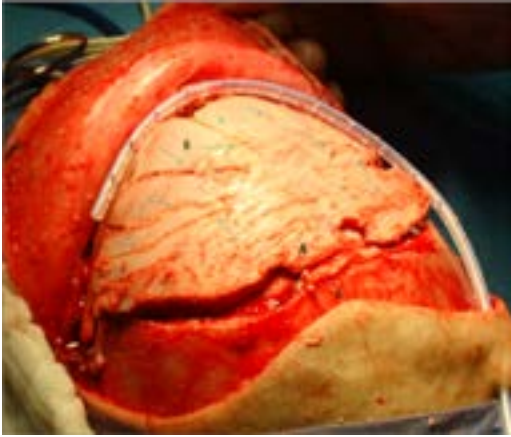
**Figure 4:** Deformity characterized by pointed frontal region was evidenced.



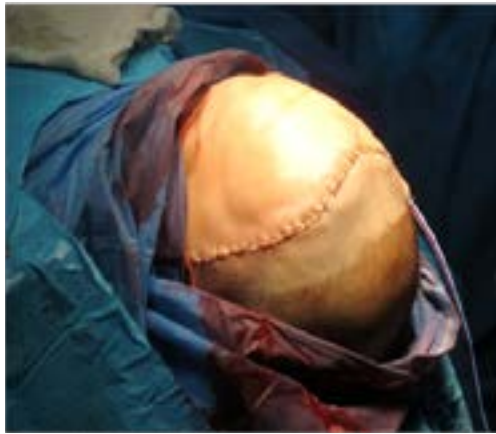**Figure 5:** The surgery is to perform a complete frontoorbital osteotomy in addition to the resection of the metopic suture, which includes both orbital ceilings and the pterional region, a forehead remodeling occurs.



**Figure 6:** Soft flap towards the face, holes of parasagittal and paratemporal trepans are made.



**Figure 7:** Replace, mold and interpose the frontal bone, leave the frontal bone floating, check hemostasis and leave portovac drain.



**Figure 8:** Performs synthesis of operative wound by planes.



**Figure 9 and 10:** Patient before the operation where triangular prominence of the forehead and eyes are shown very close together, and one month after the surgery, he evolved favorably, recovering spontaneous activity, attention to the environment, reactivity, response to stimuli. Behavior, activity, affectivity, communication, interest in the environment, in addition to the facial molding of the forehead.

## References

1. Thompson D, Malcolm G, Jones B, Harkness W, Hayward R. Intracranial ressure in single-suture craniosynostosis. *Pediatr Neurosurg.* 1995; 22: 235-240.
2. Panchal J, Amirsheibany H, Gurwitch R, Cook V, Francel P, Neas B, et al. Neurodevelopment in children with single suture craniosynostosis and plagiocephaly without synostosis. *Plast Reconstr Surg.* 2001; 108: 1492-99.
3. Muenke M, Gripp K, Mc Donald-McGinn D, Gaudenz K, Whitaker L, Bartlett SP, et al. A unique point mutation in the fibroblast growth factor receptor 3 gene (FGFR3) defines a new craneosynostosis syndrome. *Am J Genet.* 1997; 60: 555-564.
4. Havlik R, Azurin D, Barlett S, Whitaker L. Analysis and treatment of severe trigonocephaly. *Plast Reconstr Surg.* 1999; 103: 381-90.
5. Collman H, Sorensen N, Krauf J. Consensus: Trigonocephaly. *Child's Nerv Syst.* 1996; 12: 664-668.
6. Hinojosa J, Esparza J, Muñoz MJ, Salván R, Romance A, Alén JF, et al. Surgical treatment of trigonocephalies and associated hypoteleorbitism. *Neurocirugía.* 2003; 13: 447-45.
7. Genitori L, Caveiheiro, Lena G, Dollo C, Choux M. Skull base in trigonocephaly. *Pediatr Neurosurg.* 1992; 17: 175-181.
8. Lajeunie E, Le Merrer M, Bonaiti-Pellie C, Marchac D, Renier D. Genetic study of nonsyndromic coronal craniosynostosis. *Am J Med Genet.* 1995; 55(4): 500-504.
9. Goodrich JT, Craig DH. Surgical management of trigonocephaly. *En Techniques in Neurosurgery* 1997; 3(3): 190-197.
10. Friede H, Alberius P, Lilja J, Lauritzen C. Trigonocephaly: clinical and cephalometric assesment of craniofacial morphology in operated and nontreated patients. *Cleft Palate J.* 1990; 27: 362-367.
11. Esparza J, Hinojosa J, Muñoz MJ. Operative treatment of the anterior synostotic plagiocephaly: analysis of 45 cases. *Child's Nerv Syst.* 1998; 14: 448-454.
12. Czorny A, Forlodou P, Stricker M, Ricbourg B. es cranes triangulaires. A propos de 87 cas de trigonocéphalies. *Neurochirurgie.* 1994; 40: 209-221.
13. Di Rocco C, Velardi F, Ferrario A, Marchese E. Metopic synostosis: in

favour of a “simplified” surgical treatment. *Child’s Nerv Syst.* 1996; 12: 654-663.

14. Muñoz MJ, Esparza J, Hinojosa J, Salván R, Romance A, Muñoz A. Fronto-orbital remodeling without orbito-naso-frontal bandeau. *Child’s Nerv Syst.* 2003; 19: 353-58.