

Late Presentation of Left Ventricular Outflow Tract Obstruction due to Sub-aortic Membrane

Mastroiacovo G^{*}, Marco Gennari M¹, Ali SG¹, Polvani G^{1,2} and Agrifoglio M^{1,3}

¹Centro Cardiologico Monzino, IRCCS, Milan, Italy

²Department of Cardiovascular Sciences and Community Health, University of Milan, Italy

³Department of Biomedical Surgical and Dental Sciences, University of Milan, Italy

Volume 3 Issue 3- 2020

Received Date: 14 Sep 2020

Accepted Date: 24 Sep 2020

Published Date: 28 Sep 2020

1. Abstract

Left Ventricular Outflow Tract (LVOT) obstruction is caused by a wide range of different anatomical lesions referred to as Sub-aortic Stenosis (SS). SS can be isolated or associated with other heart defects; and tends to evolve and progress over time even though the speed of its progression is very variable and difficult to predict. We present a case of a patient affected by sub-aortic membrane undergone to surgical procedure.

2. Keywords

Sub-aortic Stenosis; Left Ventricle Outflow Tract Obstruction; Congenital Heart Disease; Cardiovascular Pathology

3. Clinical Image

Left ventricular outflow tract (LVOT) obstruction is caused by a wide range of different anatomical lesions, which are collectively referred to as sub-aortic stenosis (SS). SS can be isolated or associated with other heart defects; in the most dramatic cases it can be part of a syndrome that includes several obstructive lesions of the left heart, called the Shone complex. Isolated SS can be caused by several factors: displacement of the mitral papillary muscle, displacement of the infundibular septum, abnormal insertion of the mitral valve or presence of exuberant fibrous tissue [1].

Sub-aortic stenosis tends to evolve and progress over time even though the speed of its progression is very variable and difficult to predict. In addition to the risk of progression, patients with sub-aortic stenosis face two other types of problems: an increased risk of infectious endocarditis and aortic valve insufficiency if the fibrous strands extend below the aortic valve cusps. The aortic valve may be normal or stenotic. Sub-aortic stenosis, leading to a LVOT obstruction, causes an increase in post-loading determining a concentric ventricular hypertrophy, especially at the septal insertion of the membrane [1].

SS is usually suspected in young adults when the valve anatomy is not clearly stenotic, whereas Doppler examination reveals high trans-aortic pressure gradient [2].

Concerning the surgical treatment of SS, many dilemmas still remain open; it is uncertain which is the right timing and the type of procedure, although it has been noted that an early intervention decreases the risk of valve failure, even if the risk of stenosis recur-

rence remains high in the long term period.

We report images from a case of sub-aortic stenosis in a 72 years old woman referring to our Institution for exertional dyspnea (NYHA III). The patient was successfully operated of sub-aortic membrane removal and septal myectomy according to Morrow, the aortic valve was not surgically treated as it was neither stenotic nor insufficient (Figure 1). The course in the operating theatre was regular, the weaning from extracorporeal circulation did not require any inotropic support. Respiratory weaning and extubation occurred in the first few hours after arrival in the ICU. The rest of the hospitalization in intensive care and cardiac surgery ward was regular and free from major cardio vascular events. The patient was discharged to a rehabilitation center on the fifth post-operative days completely asymptomatic for anger and dyspnea (NYHA I).

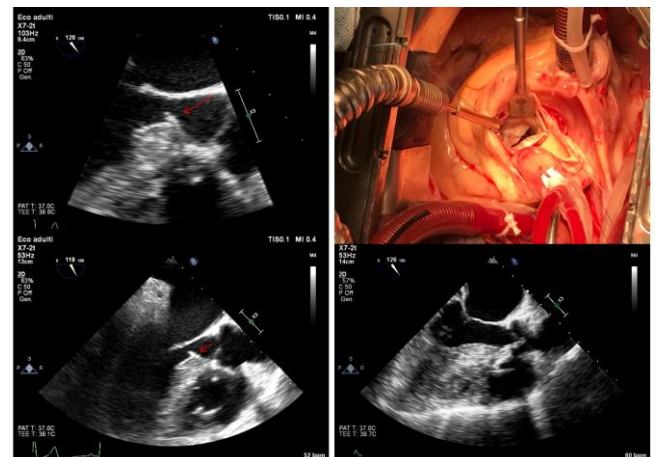


Fig 1. A, B: subaortic membrane at TEE; C: intraoperative image of the subaortic membrane; D: TEE after subaortic membrane removal.

*Corresponding Author (s): Giorgio Mastroiacovo, IRCCS Centro Cardiologico Monzino, Via Parea 4 - 20138, Milan, Italy, Tel: +39 3337043598, E-mail: gio.mastroiacovo@hotmail.it

References

1. Alain Serraf MD Joy Zoghby MD et al. Surgical treatment of subaortic stenosis: A seventeen-year experience. *The Journal of Thoracic and Cardiovascular Surgery* Volume 117, Issue 4, April 1999, Pages 669-678.
2. Sylvestre Maréchaux, François Juthier et al. Illustration of the echocardiographic diagnosis of subaortic membrane stenosis in adults: surgical and live three-dimensional transoesophageal findings. *European Journal of Echocardiography*, Volume 12, Issue 1, January 2011, Page E2.