

## Digestive Manifestations During Infection with COVID-19: Experience of A Moroccan Health Center

Berraida R<sup>1\*</sup>, Zinbi A<sup>2</sup>, Ouzaa R<sup>4</sup>, Fatouhi A<sup>3</sup>, El aissat M<sup>2</sup>, Elokti SI<sup>1</sup>, Ouahid T<sup>1</sup>, Addajou<sup>1</sup>, Azali Y<sup>1</sup>, Osman Guelleh M<sup>1</sup>, Mrabti S<sup>1</sup>, Seddik H<sup>1</sup>, Benkirane A<sup>1</sup> and Elbaaj M<sup>2</sup>

<sup>1</sup>Hepato-gastroenterology department II, Mohammed V. Rabat military training hospital

<sup>2</sup>Department of Internal Medicine Moulay Ismail Meknes military hospital

<sup>3</sup>Served as otho-rhino-3laryngology Hospital military instruction mohammed V. Rabat

<sup>4</sup>Orthopedic trauma service II, Mohammed V. Rabat military training hospital, Faculty of Medicine and Pharmacy of Fez, USMBA, Morocco

### \*Corresponding author:

Reda Berraida,  
Hepato-gastroenterology department II,  
Mohammed V. Rabat military training hospital,  
USMBA, Morocco,  
E-mail: rberraida@gmail.com

Received: 04 Nov 2020

Accepted: 23 Nov 2020

Published: 27 Nov 2020

### Copyright:

©2020 Berraida R et al. This is an open access article distributed under the terms of the Creative Commons Attribution License, which permits unrestricted use, distribution, and build upon your work non-commercially.

### Citation:

Berraida R, Digestive Manifestations During Infection with COVID-19: Experience of A Moroccan Health Center. Clinics of Surgery. 2020; 4(2): 1-3.

### Keywords:

Covid-19; Pandemic; digestive manifestations

## 1. Abstract

COVID-19 due by the new SARS-CoV-2 coronavirus, is responsible for the current pandemic. If respiratory symptoms are in the foreground and condition the prognosis of the disease, the gastrointestinal symptoms initially described as rare are reported more and more frequently in the latest studies.

Those studies suggest that they are a sign of a favorable environment for an aggravation of the disease, probably in connection with the development of inflammation. Inevitably, the influence of the gut microbiota is suspected.

The aim of our work and is to report the digestive manifestations during a covid-19 infection through a series of cases.

## 2. Introduction

Covid-19 infection is often accompanied by digestive problems, which can precede the onset of respiratory symptoms. The latter suggest that they are the sign of a favorable ground for a worsening of the disease, probably linked to the development of inflammation. Inevitably, the influence of the gut microbiota is suspected.

We report, through a series of cases, the digestive manifestations during infection by covid-19

## 3. Materials and Methods

This was a single-center descriptive prospective study that took place over a period of 5 weeks from May 3, 2020 to June 9, 2020 in a field hospital located in the city of Fez in Morocco. We included in our study all patients presenting general and / or digestive symptoms and in whom the PCR test for SARS-CoV2 was positive. The agreement of the ethics committee was not necessary given the observational nature of the study. Patients were registered as they were admitted to the hospital.

All our patients have undergone a careful clinical examination, and laboratory examinations. All the data were collected using an operating sheet showing the epidemiological, clinical, biological, electrical and pulmonary imaging parameters as well as serological monitoring with twice-daily monitoring of clinical parameters. All of the data was entered on an Excel table, then analyzed by this same software.

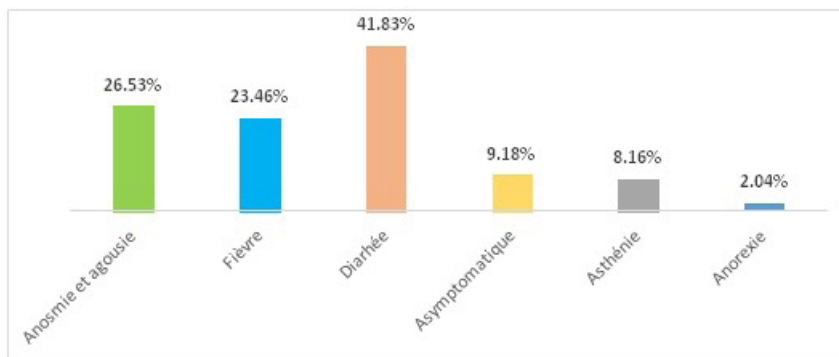
## 4. Results

We recruited 98 patients with general and / or digestive symptoms with a positive RT-PCR test for SARS-COV2.

All of our patients were male. The average age was 35.68 years

with extremes ranging from 24 years to 54 years. No history of chronic inflammatory bowel disease or other digestive pathologies has been reported. Unbalanced diabetes with a fasting blood sugar of 4g/dl was found in one patient. Among the patients, there was a case of history of pulmonary tuberculosis with the notion of hemoptysis and a patient followed for a depressive syndrome stable under treatment.

The reason for consultation was represented by: fever at 38° C in 23 patients or 23.46%, asthenia in 8 patients or 8.16%, pharyngeal pain in 6 patients or 6.12%, diarrhea in 41 patients in 41.83% of cases. We also noted anosmia and ageusia in 26 patients, i.e. 26.53%, anorexia in 2 patients and 9 patients were asymptomatic, i.e. 9.18% (Figure 1)



**Figure 1:** Symptoms and reason for consultation

Paraclinical explorations were normal apart from a CT scan which showed bronchial dilation in a patient who had hemoptysis. All our patients were put on Hydroxychloroquine in combination with Azithromycin in addition to vitamin C, vitamin D and enoxaparin. A control PCR was negative on D6 of treatment in 25 patients, i.e. 25.51% of cases.

## 5. Discussion

SARS-CoV-2 is responsible for a polymorphous digestive symptomatology that may precede the onset of respiratory symptoms. Several studies have recently converged to describe the presence of digestive signs in SARS-CoV-2 infection. In the cohort of 552 Chinese hospitals comprising 1,099 patients, the authors observed nausea or vomiting in 5% of cases and diarrhea in 3.8% of cases [1]. More recent cohorts suggest that diarrhea can be observed in 2 to 10% of cases, or even up to 39% in a cohort of 140 patients, while nausea or vomiting was reported in 1 to 17% of cases [2, 3]. In our series, no patient presented with nausea or vomiting. Chinese researchers recently analyzed digestive symptoms in patients with Covid-19 admitted to three hospitals in Hubei province. It turns out that Covid-19 patients may present with diarrhea as the first symptom of the disease. In rare cases [4], a patient can even present digestive symptoms in the absence of respiratory symptoms and this is the case for our patients.

Diarrhea is generally scanty and short-lived, not exceeding 3-4 stools per day, which is in agreement with our study, with a frequency varying from 2 to 39% [2]

A Chinese retrospective series of 1,141 confirmed cases of COVID-19, 16% of patients had isolated digestive symptoms [4], it was diarrhea in 37% of cases and abdominal pain in 25% of

cases. In another study of 204 patients, 51% had digestive impairment including diarrhea in 34% of cases [5]. Patients with digestive symptoms had a longer hospital stay compared to those without digestive symptoms. The authors also observed a correlation between the severity of respiratory involvement and the intensity of digestive symptoms. These elements are confirmed by a study of 651 patients, of whom 11.4% had at least one digestive symptom. Patients with digestive symptoms had more severe disease ( $p < 0.001$ ) [6].

There is a correlation between the severity of respiratory involvement and the intensity of digestive symptoms

Anorexia seems frequent and it was noted in 40 to 50% of cases [2, 3] and digestive bleeding was reported in 4 to 13.7% of cases [2, 3]. In our study, only 2 patients had anorexia.

For patients with diarrhea, they are admitted to the intensive care unit (ICU) less than patients with respiratory distress syndrome: [7] in our series for patients with diarrhea, no case has been referred to the intensive care unit.

Another study involving 200 patients [8] found that many patients had digestive symptoms as the main complaint, confirming that digestive symptoms, such as diarrhea, may be a clinical feature of COVID-19 presentation, and that the index of suspicion may need to be increased earlier in these cases rather than waiting for respiratory symptoms to appear.

It is important to take these digestive disorders into account in patients treated with hydroxy chloroquine, whether or not associated with azithromycin. In our series, 66 patients had diarrhea secondary to hydroxychloroquine, i.e. 67.34%, which was easily resolved by taking probiotics.

The frequency of digestive manifestations during SARS COV infection could be explained by the fact that SARS-CoV-2 shares 80% of the genomic sequences of the SARS coronavirus (SARS-COV). Both viruses have an affinity for angiotensin-converting enzyme 2 (ACE2) receptors in human cells. The virus seems to use them to attach to and enter the cell. The ACE2 receptor is present in the alveolar cells but also in the digestive tract. Indeed, it is observed at the level of the upper part of the esophagus, but also at the level of the enterocytes of the ileum and of the colonocytes. In addition, SARS-COV has also been identified at the hepatic and pancreatic level [9].

SARS-CoV-2 can also damage, directly or indirectly, the digestive system through the body's inflammatory response. Several studies have also shown the presence of the virus' genetic material in the stool (up to 53% of patients analyzed). [2, 3].

Another systematic review and meta-analysis of 60 studies involving 4,243 patients showed that the median fecal viral load was higher in patients with diarrhea than in patients without diarrhea (5.1 log copies / ml vs. 3.9 log copies / ml;  $P = 0.06$ ) [10]. The same authors showed that RNA from the virus was detected in stool samples from 48% of patients, concluding that stool samples are highly contagious in patients with COVID-19 even after recovery.

Finally, it is possible that the presence of the coronavirus disrupts the intestinal microbiota. Studies to analyze the impact of SARS-CoV-2 on the intestinal bacterial flora are underway.

Liver test abnormalities have also been described in COVID-19 patients. The frequency of cytolysis varies according to the series between 14.8 to 53.1%; the elevation of transaminases remaining moderate in the majority of cases [2, 11]. In a series of 56 patients, gamma-glutamyl transferase (GGT) was elevated in 54% of cases. Abnormalities in liver function tests are usually mild and transient. They seem more intense in severe COVID-19. Thus, in a cohort of 99 patients included in Wuhan, 43 had hepatic cytolysis including one patient who had severe respiratory impairment and an elevation of ALT to 7,590 U / L. It was not specified whether it was hypoxic hepatitis or an attack directly related to COVID-19.

The abnormalities of the hepatic tests are probably multiple causes, being able to be the consequence of a direct attack of the virus - the SARS-COV being able to bind to the cholangiocyte and the hepatocytes via the ACE2 receptor or lesions of dysimmunity origin, of drug-induced hepatitis or hypoxic hepatitis in the most severe patients.

For pancreatic manifestations, a study was conducted in 52 patients with confirmed SARS-CoV-2 infection in a Chinese hospital over a 5-week period by monitoring the level of pancreatic enzymes. An increase in amylase ( $> 90$  U / L) or lipase ( $> 70$  U / L) was observed in 9 (17%) patients [9]. >> No information was available regarding possible CT abnormalities. It should be noted

that patients with elevated pancreatic enzymes had more severe respiratory disease.

In our series, no case of hepatic or pancreatic damage was mentioned.

## 6. Conclusion

In this endemic context, the diagnosis of COVID-19 should be considered for patients with gastrointestinal symptoms. This will help prevent the transmission of the virus in the hospital environment, in particular to health professionals and not delay the management of patients with gastrointestinal manifestations. Diarrhea is the main gastrointestinal symptom and appears to be present in half of patients with COVID-19. These data must be disseminated in the medical community and must be confirmed by further studies.

## References

1. Guan W, Ni Z, Hu Y, Liang W, Ou C, He J, et al. Clinical Characteristics of Coronavirus Disease 2019 in China. *N Engl J Med.* 2020; 382: 1708-20.
2. Wong SH, Lui RN, Sung JJ. Covid-19 and the Digestive System. *Journal of Gastroenterology and Hepatology.* 2020; 35: 744-48.
3. Tian Y, Rong L, Nian W, He Y. Review article: gastrointestinal features in COVID-19 and the possibility of faecal transmission. *Aliment Pharmacol Ther.* 2020; 51(9): 843-51.
4. Luo S, Zhang X, Xu H. Don't overlook digestive symptoms in patients with 2019 novel coronavirus disease (COVID-19). *Clin Gastroenterol Hepatol.* 2020; 18: 1636-7.
5. Pan L, Mu M, Yang P, Sun Y, Wang R, Yan J, et al. Clinical characteristics of COVID-19 patients with digestive symptoms in Hubei, China: a descriptive, cross-sectional, multicenter study. 2020; 115: 766-73.
6. Jin X, Lian JS, Hu JH, et al. Epidemiological, clinical and virological characteristics of 74 cases of coronavirus-infected disease 2019 (COVID-19) with gastrointestinal symptoms. 2020; 69: 1002-09.
7. Li XY, Dai WJ, Wu SN, Yang XZ, Wang HG. The occurrence of diarrhea in COVID-19 patients. *Clin Res Hepatol Gastroenterol.* 2020; 44: 284-5.
8. Pan Lei Pan, MD, PhD, Mi Mu, MD, Clinical Features of COVID-19 Patients with Digestive Symptoms in Hubei, China: A Descriptive, Cross-sectional, Multicenter Study. *Am J Gastroenterol.* 2020; 115: 10.
9. Wang F, Wang H, Fan J, Zhang Y, Wang H, Zhao Q. Pancreatic injury patterns in patients with COVID-19 pneumonia. *Gastroenterology.* 2020; 159: 367-70.
10. Cheung KS, Hung IF, Chan PP, Lung KC, Tso E, Liu R, et al. Gas-manifestations of SARS-CoV-2 infection and virus load in fecal samples from the Hong Kong cohort and systematic review and meta-analysis. *Gastroenterology* 2020; 159: 81-95.
11. Sun J, Aghemo A, Former A, Valenti L. COVID-19 and liver disease. *Foie.* 2020.