

A Discussion On Microwave Therapy for Bromhidrosis

Ho WT*

Department of Dermatology, Ho Wen Tsao Skin Clinic, No.179, Sec.2, Wenhua 3rd Rd, Linkou District, New Taipei City, Taiwan

***Corresponding author:**

Wen-Tsao Ho,
Department of Dermatology,
Ho Wen Tsao Skin Clinic, No.179, Sec.2,
Wenhua 3rd Rd, Linkou District,
New Taipei City, Taiwan, ROC,
Tel: +886 933486423,
E-mail: varec.clinic@gmail.com

Received: 08 Dec 2020
Accepted: 23 Dec 2020
Published: 28 Dec 2020

Copyright:

©2020 Ho WT et al. This is an open access article distributed under the terms of the Creative Commons Attribution License, which permits unrestricted use, distribution, and build upon your work non-commercially.

Citation:

Ho WT, COVID-19 and Testis: A Systematic Review. Clinics of Surgery. 2020; 4(4): 1-2.

1. Letter to Editor

Microwave therapy is an effective alternative in the permanent treatment of axillary hyperhidrosis, which produced the highest satisfaction among treated patients. As there is not much literature relating to therapies to reduce bromhidrosis [1], we would like to present in this paper our own data on the usage of liquid chromatography-mass spectrometry (LC-MS) to evaluate the effect before and after the treatment of bromhidrosis in our practice. (Table 1) presents the data of chemical secretion of patients treated with microwave therapy for bilateral axillary bromhidrosis with the liquid chromatography-mass spectrometry technique [2]. The chemical secretion, 3M3SH-Cys-Gly, 3M2H-Gln and HMHA-Gln, in the sweat of bromhidrosis patients were monitored before and after the procedure.

The results showed a marked reduction in sweat secretion after microwave therapy. However, there is a disparity in the magnitude of reduction of secretion depending on the severity of hyperhidrosis. After treatment, the chemical reading on the side with the more severe case of bromhidrosis was reduced by 25-46%, whereas, on the side with a moderate case of bromhidrosis, by 63-75%. It is inferred that the side with stronger offensive odor might have thicker or more abundant glands. Since microwave energy is supplied only to the immediate area, this may indicate that microwave treatment is less efficient among patients who have a severe condition of bromhidrosis.

Axillary swelling and pitting edema were commonly observed following administration of microwave treatment, and the duration lasted up to 1-3 months long. Removal of apocrine glands and fluids were performed to determine the cause. The removed samples

were placed in a household microwave oven at 2.45 GHz, 800W, for 20 seconds and found a marked swelling and expansion of 2-3 times the volume (Figure 1). This could explain the reason for the prolonged swelling and edema, which usually persists beyond 1 week.

Microwave therapy is used to treat hepatocellular carcinoma and prostate hyperplasia leading to coagulative necrosis in cells [3, 4]. Histologically, coagulative necrosis is also seen in microwaved apocrine glands (Figure 2). We consider microwave therapy can potentially be useful to treat bromhidrosis, but with a risk of relapse in 2-3 months' time due to regrowth of the apocrine glands. Further studies in the usage of microwave therapy would increase the field of knowledge in this procedure.



Figure 1: Apocrine glands illustrated immediately after home microwave oven at 2.45 GHz,800W, for 20 seconds

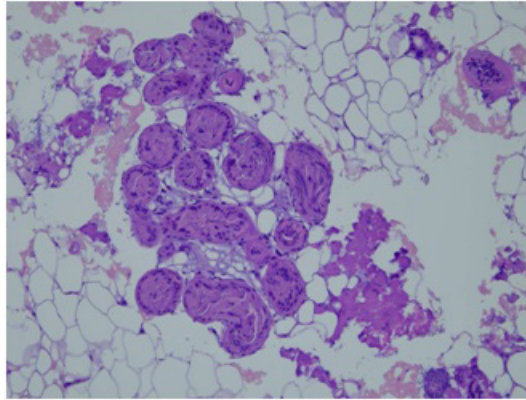


Figure 2: Coagulative necrosis found in microwaved apocrine cells.

Table 1

Date	Molecule		3M3SH-Cys-Gly (cps)	3M2H-Gln(cps)	HMHA-Gln(cps)
	Left	Right			
Before tx	Left		5808.93	9119.25	76308.26
	Right		2193.30	4282.07	37381.77
3 months after tx	Left		4332.08	5360.13	41248.45
	Right		791.27	1258.13	9718.23
Molecular reduction	Left		25.42%	41.22%↓↓	45.94%↓↓
	Right		63.92%	70.61%↓	75.44%

(cps) counts per second

References

1. Yagerman S, Brauer JA, Geronemus RG. Retrospective Multistudy Analysis of Axillary Odor Reduction After Microwave Treatment. *Dermatol Surg.* 2018; 44: 1362-3.
2. Ho WT, Lee LJ, Pan JY. Following Changes in the Axillary Secretions of Two Patients Before and After Bromhidrosis Surgery Using Liquid Chromatography-Mass Spectrometry. *Dermatol Surg.* 2017; 43: 459-62.
3. Yamashiki N, Kato T, Bejarano PA, Berho M, Montalvo B, Shebert RT, et al. Histopathological changes after microwave coagulation therapy for patients with hepatocellular carcinoma: review of 15 explanted livers. *Am J Gastroenterol.* 2003; 98: 2052-9.
4. Bartoletti R, Cai T, Tinacci G, Longo I, Ricci A, Massaro MP, et al. Transperineal microwave thermoablation in patients with obstructive benign prostatic hyperplasia: a phase I clinical study with a new mini-choked microwave applicator. *J Endourol.* 2008; 22: 1509-17.