

Treatment of Traumatic Joint Instability with Bipolar Radial Head Prosthesis: A Medium-Long Term Follow-Up

Odorizzi G^{1*}, Odorizzi M², Berger W¹, Musetti A³ and Papadia D³

¹Department of Orthopedic and Traumatology Surgery, Franz Tappeiner Hospital, Meran, Italy

²Department of Orthopedic and Traumatology Surgery, San Giovanni Hospital, IPSI, Bellinzona, Switzerland

³Department of Orthopedic and Traumatology Surgery, Santa Chiara Hospital, Trento, Italy

*Corresponding author:

Gianni Odorizzi,
Resident at the Orthopedic and Traumatology
Department, Franz Tappeiner Hospital, Meran,
Italy, Per Villamontagna Street n. 51, 38121,
Trento (Tn), Italy,
E-mail: odorizzi.gianni@gmail.com

Received: 18 Jan 2021
Accepted: 08 Feb 2021
Published: 14 Feb 2021

Copyright:

©2021 Odorizzi G, et al. This is an open access article distributed under the terms of the Creative Commons Attribution License, which permits unrestricted use, distribution, and build upon your work non-commercially.

Citation:

Odorizzi G, Treatment of Traumatic Joint Instability with Bipolar Radial Head Prosthesis: A Medium-Long Term Follow-Up. Clin Surg. 2021; 4(8): 1-6.

Author Contributions:

Odorizzi M: assistant author and researcher, Berger W: assistant author and Reviewer, Musetti A: assistant author and Reviewer
Papadia D: Operating Surgeon, Research Supervisor, conceptualization, drafting and review

1. Abstract

1.1. Introduction

The treatment of proximal radial head fractures is to recreate and restore articular stability of the elbow joint. There are various options of radial head prosthesis when native bone is not salvageable. We report our findings of a retrospective clinical and radiological analysis of patients who underwent bipolar modular radial head prosthesis.

1.2. Materials and Methods

We included all patients who underwent bipolar modular anatomic radial head prosthesis from August 2009 to September 2016, following an unstable elbow fracture associated with radial head fracture (Mason III, IV). The patients were radiographically evaluated considering radiolucency, heterotopic ossification and osteoarthritis, and clinically with the Mayo Elbow Performance Index (MEPI) and Quick Dash scores with a minimum follow-up of 15 months.

This investigation was approved by the IRB of the Authors affiliated institutions.

1.3. Results

Our study population included nine patients (three males, six females) with patient demographics resulting homogenous, a mean

age of 53.8 years and mean follow-up period of 62 months. At the end of the observational period no revisions were necessary and the clinical outcomes based on MEPI were optimal. Radiographically, two patients (33%) developed bone reabsorption at the level of the radial prosthesis neck, while remaining clinically asymptomatic. Four patients (67%) developed heterotopic ossification and five (83%) a diffuse osteoarthritis.

1.4. Conclusions

Prosthetic replacement represents the treatment of choice for radial fractures that are not salvageable and have an associated unstable elbow joint injury. The present study has several limits, even though no significant complications were observed. Our experience demonstrates an excellent survival rate at a medium-long term with excellent functional outcomes. The radiographic aspect of the reabsorption, at the moment, doesn't have any clinical complication.

1.5. Level of Evidence: Therapeutic Level III.

2. Introduction

Over the last few decades, the use of radial head replacement has become the treatment of choice for radial head fractures that are not salvageable through osteosynthesis and when there is joint instability [1-6].

The radial head is a secondary stabiliser and when the primary stabilisers are torn, it assumes a key role for the stability of the elbow joint [1-6].

Surgeons can choose among various prosthetic designs, such as monopolar vs bipolar, anatomic vs non anatomic, cemented vs press-fit. The literature does not demonstrate any evidence of superiority when comparing prosthetic types; we have chosen a bipolar modular anatomic radial head replacement.

To our knowledge, only one study has described the clinical and radiographic outcomes on long term follow-up [7].

The purpose of this study was to evaluate the clinical and radiographic outcomes at a medium and long term follow-up as to date it is an under reported cohort.

3. Materials and Methods

Between August 2009 and September 2016 we undertook nine bipolar prostheses due to an unstable elbow with a radial head fracture (Mason III and IV).

All patient data is reported in table 1. At the time of follow-up, thanks to an informed consent, every patient was aware of the modality of the study.

Six patients were females (67%) and three males (37%) and the average age was 53,8 years (range 37-81 years).

We replaced the native radial head with an anatomic, modular and bipolar design, using the “rHead Recon” of Small Ball Innovations.

Eight patients were treated for an acute trauma with a comminuted radial head fracture and a dislocation of the elbow reported clinically and on X-ray and in six cases with CT (e-scan 3-D). The radial head fractures were classified according to the Mason classification. The prosthetic implant was applied only when radial head repair was no longer feasible.

In the three cases of the “Terrible Triad” fracture (elbow dislocation, a radial head fracture and a coronoid process fracture as reported by Hotchkiss) the coronoid fracture was classified according to the O’Driscoll classification.

All cases were treated within 4 days, a part from one case which was treated one-month post trauma due to an initially unrecognized postero-lateral instability with recurring elbow dislocation.

The surgical access approach was the Kocher postero-lateral approach, performed in all nine cases by the same surgeon [DP].

In the case of the prosthesis implant for “Terrible Triad” repair (33% of cases), radial head prosthetic implant was undertaken with osteosynthesis of the coronoid process using a Herbert screw. In one case we reported intraoperative a secondary instability, for this reason, we took a two-step approach: initially with the use of a cemented stem, and then, at roughly 7 days’ post-op, we performed a surgical revision with iliac crest homologous grafting for the cor-

onoid process.

Once we have implanted the prosthetic design, we have evaluated intraoperative the elbow stability with a varus-valgus stress test under fluoroscopy. In a patient with a risk of stem mobilisation reported intraoperative, we have used a biphasic bone substitute (Cerament™) in order to increase prosthetic and therefore joint stability.

In eight cases it was necessary to perform the reconstruction of the lateral ligament, which was performed using a trans-osseous reconstructive suture in 7 patients and a mini-anchorage technique in one. The collateral medial ligament was reconstructed in one patient, because there was a tendency for dislocation at 30-45° degree in extension.

The elbow joint was immobilized for a week after surgery and then the plaster cast was replaced with an articular brace for another 4 weeks, in order to facilitate early mobilization, rehabilitation and avoid articular stiffness.

All patients were re-evaluated one month and one year after the surgery. At the time of the final follow-up two patients were lost and one patient denied to take part in our study. The mean follow-up was 62 months (range 15-100 months).

We have first evaluated the traumatic mechanism that caused the fracture and the presence of pain and/or the feeling of joint instability. We have used three different rating systems: Mayo Elbow Performance Index (MEPI), The disability of the Arm, Shoulder and Hand Score (QuickDASH Score) and VAS (pain analogic scale). Particularly, we used the scores, asking the patient some simple questions, with the purpose of assessing pain, Range of Motion (ROM), articular stability and functionality.

The exam was performed following this procedure:

1. Clinical examination of the elbow joint, particularly the surgery scar;
2. Evaluation of the Rom with a goniometry;
3. Evaluation of the articular stability with varus and valgus stress-test;
4. Photography of the patient in Anterior and Lateral projection in order to document the Range of Motion.

Then, we required a radiographic evaluation, which was compared to the pre- and post-operative images for the evaluation of radiographic complications. The radiographic exam was conducted with the arm in neutral position in lateral, oblique and anterior-posterior projection. The comparative analysis aimed to point out the most frequent radiographic complications, with the purpose of finding the radiographic outcomes and verifying a possible clinical correlation:

- degenerative arthritis of the joint (Broberg and Morrey scale) [8];

- mobilization/subluxation of the implant in the endomedullary canal;
- heterotopic bone ossification (Hastings and Graham scale) [9];
- periprosthetic reabsorption zone (defined by Grewal) [10].

4. Results

4.1. Clinical Outcomes

The demographic data and the clinical results are represented in the Table 1 and Figure 1. The radial head fractures concerned the dominant arm in four patients (67%) and the non-dominant arm in two (33%).

No patient had referred pain at the time of the clinical inspection (VAS:0). The mean value for the MEPI was 99,2 (range 95-100) and the mean value for the QuickDASH score was 8,42 (range 0-25) (Figure 1).

The outcomes (Figure 1) obtained according to the MEPI were excellent in 100% of the cases, the QuickDASH score has pointed out an absence of disability in two patients, and a minimum dis-

ability for the remaining four cases.

The ROM of the upper arm compared to the contralateral was decreased regarding the extension-flexion (125° (range 102-167) vs. 146° (range 122-170)), pronation (70° (range 31°-86°) vs. 84° (range 78°-89°)), supination (74° (range 55°/87°) vs. 85° (range 78-90)) and the pronation-supination (144° (range 86°-173°) vs 169° (range 163°-174°)). None of the patients complained of instability at the time of the follow-up interval of 6 and 12 months.

4.2. Radiographic Outcomes

The outcomes are listed in the Figure 2.

A significant reabsorption of the neck prosthesis was seen on X-ray evaluation in two patients (33%), zone 1 and 7 defined from Grewal, and was totally asymptomatic [10].

Heterotopic ossification was observed in four patients (67%), three included in the class II (2 cases in IIa, and 1 case in IIc), and the fourth included in the class I [9].

The presence of osteoarthritis was seen in five patients (83%), three grade II and two grade I defined by Broberg and Morrey (Figure 2) [8].

Table 1: in this table is listed the sample of the study; particularly, it's described the type of fracture, the associated injuries and the follow-up express in month.

Patients	Sex	Age (years)	Type of Fracture (Mason C.)	Associated injuries	Follow-up (months)
1.	F	42	IV	LCM and LCL	100
2.	F	54	III	Instability of DRUJ	lost
3.	M	51	IV	Terrible Triad	78
4.	F	47	IV	LCL	65
5.	M	54	IV	LCL	60
6.	F	67	IV	Terrible Triad Fracture of the Proximal Humerus	54
7.	M	37	IV	Terrible Triad	lost
8.	F	51	IV	LCL	denied
9.	F	81	IV	Terrible Triad	15
Average	67% F 37%M	53,8			62

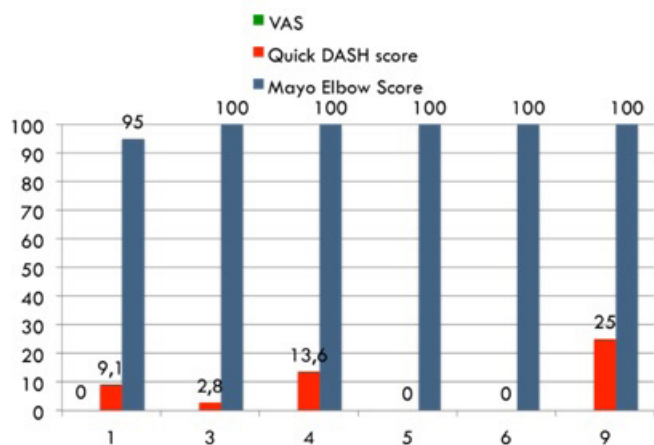


Figure 1: it shows the clinical outcomes of the single patient according to the three different rating systems used in the study.

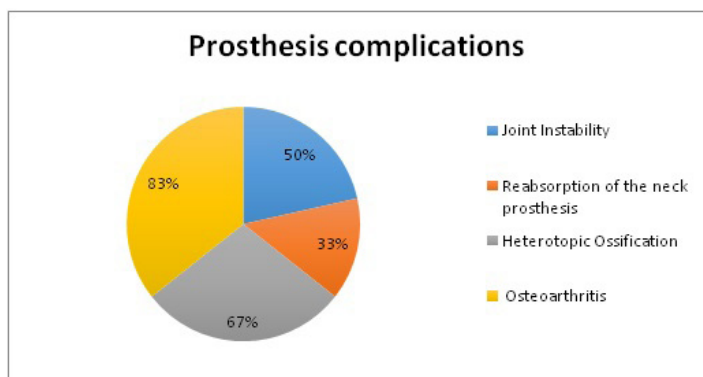


Figure 2: Complications reported in the study after implantation of radial head prosthesis.

4.3. Surgical Complications

During the surgery, particularly after the stability test or in the immediate post-operative time, we have observed three cases of articular instability (50%) with a different aetiology. In one patient the instability occurred due to the lack of the coronoid process, the anterior buttress, after the excision of the fractured fragment. Two weeks following surgery, the patient was reoperated, with a bone grafting from the iliac crest implanted at the site of the lesion of the coronoid process and temporarily stabilised with a K wire and a cannulated screw.

In the second case, due to the irregularity of the radial rim of the diaphysis, the instability was diagnosed during the operation. To achieve stability, we used a biphasic bone substitute (Cerament™), with a transosseous loop suture at the level of the neck prosthesis.

The third patient presented a fracture-luxation treated initially with a conservative approach; one month later, on radiographic follow-up, the elbow appeared unstable, with an irreducible and inveterated fracture-luxation. For this reason, we decided to treat

it with a radial head replacement prosthesis with a suture of the lateral collateral ligament. Three days post-op, the elbow continued to dislocate posteriorly. The patient was, therefore, retreated using a K wire aligned with the humeral axis, in order to guarantee stability, with plaster cast immobilisation. Two of the three articular instabilities were retreated surgically (33%), while the third was treated at the same surgical time.

5. Discussion

The use of radial head implant is the treatment of choice when the radial head fracture is not feasible with ORIF and when the role of radial head is essential as secondary stabilization [1-6]. Nowadays, the use of bipolar or monopolar implant remains controversial. The bipolar design has several advantages such as: the reduction of bone erosion at the humeral condyle, the reduction of stress shielding between bone and implant, bone and cement, cement and implant and the increased alignment between radius and humeral condyle [11]. Additionally, the use of a press-fit implant has been recently used in order to stimulate the biological growth around the implant to permit an optimal long-term attachment [12]. The use of bipolar implant has also several disadvantages such as the increased rate of disassembly of the prosthetic design, due to the modularity and the rotational freedom that exist between the head and the neck of the prosthesis [11].

At the end of the follow-up no revision for a disassembly of the prosthesis, for subluxation or mobilization, was necessary. The survival rate was 100%.

Overall, the clinical and radiographic evaluation could be considered excellent, considering both the four principal functional parameters (stability, range of motion, pain and strength) and the incidence of radiographic complications comparing to the recent studies.

We have to notice that the severity of the trauma has a primary role, because it has influenced the functional results. This observation is supported from other studies conducted by different authors [13, 14].

The study presents several limits. It is a retrospective study in its nature, there is a variability regarding the associated injuries, the length of follow-up and the age of patients. Moreover, the sample of the study is too small to offer complete results. The radiographic image in the AP projection of the operated elbow was not compared with the contralateral image in order to evaluate the presence of overstuffing. This complication was evaluated only according to the radiographic images of the injured elbow.

Popovic et al [14] have reported the presence of radiographic modifications around the bipolar prosthetic design. They have observed, particularly, the presence of three different periprosthetic type of radiolucency: complete or incomplete radiolucent lines, balloon-shaped radiolucent zones, and proximal bone reabsorption

at the radial neck. For these authors, the radiographic modifications are caused by the mechanism of stress-shielding [2, 14-17].

In our study we haven't seen any line or zone of radiolucency, while the reabsorption areas around the neck of the prosthesis, zone 1 and 7 defined by Grewal, were presented in two patients (33%), without any clinical or functional impairment. Similar results can be found in literature; Popovic et al [4] have reported a moderate incidence (31%) of radial head reabsorption after the implant of a bipolar radial head prosthesis.

Even though several studies [15, 18-20] performed on different prosthetic designs have demonstrated that the progression of these lines/zones of periprosthetic radiolucency stabilized after two years from the operation, we advised a strictly radiographic control of the patients, that have shown this complication, in order to prevent an aseptic mobilization of the prosthesis.

The heterotopic bone ossification, mostly asymptomatic, was observed after the implant of bipolar design with a variable incidence rate (0-76%) by different authors [14, 18, 21-25].

In our study we have observed four cases (67%) of heterotopic ossification at the volar and dorsal surface of the elbow joint. Despite this slight functional limitation, none of the patients has complained about feeling pain or articular stiffness due to this complication. For one patient it was, however, difficult to objectify the functional limitation only due to the heterotopic ossification, because the primitive trauma has caused an associated injury of the humeral head. The compensation of the pronation and supination, obtained thanks to the action of the proximal tract of the superior arm, has guaranteed a normal life activity and independence.

In five patients (83%) we have observed osteoarthritis completely asymptomatic, at the ulno-humeral and humeral-radial joint, three of grade III and two of grade I according to the Broberg and Morrey Classification. This result was widely predictable considering the age of the patients and the entity of the primitive trauma.

As we know, the study of Rotini et al [25] is the only study in literature that analyses the clinical and radiographic results after the implantation of the same prosthesis used in our study. The outcomes obtained from a medium follow-up of 24 months (range 13-36 months), according to the MEPI were excellent for the 67,1% of the cases, good for the 25,8% and poor for the 6,8%. Compared to this, our study presents excellent results for all cases at a medium-long term (the average follow-up was 62 months, range 15-100 months). If we compared the radiographic complications, the two studies show similar results regarding the bone reabsorption at the level of the neck of prosthetic design (29% Rotini's study vs 33% our study), while our study presents an increased incidence of heterotopic ossification (67% vs 46,7% presents in Rotini's study) and secondary osteoarthritis (83% vs 39,7% in Rotini's study). Lastly, the presence of radiolucency zone is increased in the Ro-

tini's study (34% vs none cases in our study). It is important to underline that the study of Rotini has analysed the outcomes after the implantation of both monopolar and bipolar prosthesis, while on the other hand our study has only analysed the clinical and radiographic outcomes after the implantation of a bipolar prosthesis.

6. Conclusions

The use of radial head prosthesis represents the treatment of choice when the radial head fracture is not feasible, associated with important joint instability. As described in literature the radial head has a key role as secondary stabilizer, moreover, in that type of fracture it becomes a crucial stabilizer because the entire primary stabilizers are torn. Although the sample of the patients recruited was limited and had a wide age range, the results of the study show an adequate survival of the prosthesis at a medium-long follow-up with excellent functional results.

The only unpredictable complication of reabsorption pointed out thanks to the radiographic evaluation, has yet not been correlated to clinical complications.

Therefore, it is necessary to consider the use of a bipolar anatomic prosthesis for radial head fractures that are not feasible or for post-traumatic injuries, because it could represent a valid solution for certain patients.

References

1. Holmenschlager F, Halm JP, Piatek S, Schubert S, Winkler S. Comminuted radial head fractures. Initial experience with a Judet radial head prosthesis. *Unfallchirurg*. 2002; 105: 344-52.
2. Judet T, Garreau de Loubresse C, Piriou P, Charnley G. A floating prosthesis for radial head fractures. *The Journal of Bone and Joint Surgery*. 1996; 78 (2): 244-9.
3. Popovic N, Djekic J, Lemaire R, Gillet P. A comparative study between proximal radial head morphology and the floating radial head prosthesis. *The Journal of Shoulder and Elbow Surgery*. 2005; 14 (4): 433-40.
4. Popovic N, Gillet P, Rodriguez A, Lemaire R. Fracture of the radial head with associated elbow dislocation: results of treatment using a floating radial head prosthesis. *J Orthop Trauma*. 2000; 14 (3): 171-7.
5. Smets S, Govaers K, Jansen N, Van Riet R, Schaap M, Van Glabbeek F. The floating radial head prosthesis for comminuted radial head fractures: A multicentric study. *Acta Orthopaedica Belgica*. 2000; 66 (4): 353-8.
6. Van Riet RP, Van Glabbeek F, Morrey BF. Radial Head Fracture. In Morrey B.F. *SSJ. The elbow and its disorders*. Fourth edition ed. Philadelphia: Saunders Elsevier; 2009. 359-88.
7. Sershon AR, Lucchetti JT, Cohen MS, Wysocki RW. Radial Head Replacement with a bipolar system: an average 10-year follow-up. *J Shoulder Elbow Surg*. 2018; 27 (2), 38-44.
8. Broberg MA, Morrey BF. Results of treatment of fracture-dislocations of the elbow. *Clin Orthop Relat Res*. 1987; 216: 109-19.

9. Hastings H, Graham TJ. The classification and treatment of heterotopic ossification about the elbow and forearm. *Hand Clin.* 1994; 10(3): 417-37.
10. Grewal R, MacDermid JC, Faber KJ, Drosdowech DS, King GJW. Comminuted radial head fractures treated with a modular metallic radial head arthroplasty. Study of outcomes. *The Journal of Bone and Joint Surgery.* 2006; 88(10): 2192-200.
11. Heijink A, Kodde IF, Mulder PGH, Niek Van Dijk C, Eygendaal D. Cemented bipolar radial head arthroplasty: midterm follow-up results. *J Shoulder Elbow Surg.* 2016; 25(11): 1829-38.
12. Kodde IF, Heijink A, Kaas L, Mulder PGH, Niek Van Dijk C, Eygendaal D. Press-fit bipolar radial head arthroplasty, midterm results. *J Shoulder Elbow Surg.* 2016; 25(8): 1235-42.
13. Moro JK, Werier J, Macdermid JC, Patterson SD, King GJ. Arthroplasty with a metal radial head for unreconstructible fractures of the radial head. *The Journal of Bone and Joint Surgery.* 2001; 83(8): 1201-11.
14. Popovic N, Lemaire R, Georis P, Gillet P. Midterm results with a bipolar radial head prosthesis: radiographic evidence of loosening at the bone-cement interface. *The Journal of Bone and Joint Surgery (Am).* 2007; 89(11): 2469-76.
15. Chanlailit C, Shukla DR, Fitzsimmons JS, An Kai-Nan, O'Driscoll SW. Stress shielding around radial head prosthesis. *J Hand Surg Am.* 2012; 37(10): 2118-25.
16. Johnson JA, Beingesser DM, Gordon KD, Dunning CE, Stacpoole RA, King GJ. Kinematics and stability fo the fractured and implant-reconstructed radial head. *J Shoulder and Elbow Surg.* 2005; 14(1 Suppl S): 195S-201S.
17. Liew VS, Cooper IC, Ferreira LM, Johnson JA, King GJ. The effect of metallic radial head arthroplasty on radiocapitellar joint contact area. *Clin Biomech.* 2003; 18(2): 115-8.
18. Berschback JC, Lynch TS, Kalainov DM, Wysocki RW, Merk BR, Cohen MS. Clinical and radiographic comparisons of two different radial head implant designs. *J Shoulder Elbow Surg.* 2013; 22 (8): 1108-20.
19. Gauci MO, Winter M, Dumontier C, Bronsard N, Allieu Y. Clinical and radiologic outcomes of pyrocarbon radial head prosthesis: midterm results. *J Shoulder Elbow Surg.* 2016; 25 (1): 98-104.
20. Shore BJ, Mozzon JB, MacDermid JC, Faber KJ, King GJ. Chronic posttraumatic elbow disorders treated with metallic radial head arthroplasty. *The Journal of Bone and Joint Surgery (Am).* 2008; 90 (2): 271-80.
21. Brinkman JM, Rahusen FT, de Vos MJ, Eygendaal D. Treatment of sequelae of radial head fractures with a bipolar radial head prosthesis: good outcome after 1-4 years' follow-up in 11 patients. *Acta Orthop.* 2005; 76 (6): 867-72.
22. Burkhart KJ, Mattyasovszky SG, Runkel M, Schwarz C, Kuchle R, Hessman MH, Rommens PM, Lars MP. Mid-to long-term results after bipolar radial head arthroplasty. *J Shoulder Elbow Surg.* 2010; 19 (7): 965-72.
23. Celli A, Modena F, Celli L. The acute bipolar radial head replacement for isolated unreconstructable fractures of the radial head. *Musculoskelet Surg.* 2010; 94(Suppl 1): S3-9.
24. Dotzis A, Cochu G, Mabit C, Charissoux JL, Arnaud JP. Comminuted fractures of the radial head treated by the Juder floating radial head prosthesis. *The Journal of Bone and Joint Surgery.* 2006; 88 (6): 760-4.
25. Rotini R, Martinelli A, Guerra E, Bettinelli G, Cavaciocchi M. Radial head replacement with unipolar and bipolar SBi system: a clinical and radiographic analysis after a 2-year mean follow-up. *Musculoskelet Surg.* 2012; 96(Suppl 1): S69-79.