

Pulsus Paradoxus in A 30 Year Old Patients with Cardiac Tamponade

Farooq MS* and Barnett CF

Department of Surgery, New York University School of Medicine, New York, USA

***Corresponding author:**

Mohammad Saad Farooq,
Department of Surgery, New York
University School of Medicine, New York, USA,
E-mail: saadfaruk@hotmail.com,
saad.farooq@medstar.net

Received: 20 Mar 2021

Accepted: 02 Apr 2021

Published: 07 Apr 2021

Copyright:

©2021 Farooq MS, et al. This is an open access article distributed under the terms of the Creative Commons Attribution License, which permits unrestricted use, distribution, and build upon your work non-commercially.

Citation:

Rout SK, Pulsus Paradoxus in A 30 Year Old Patients with Cardiac Tamponade. Clin Surg. 2021; 5(5): 1-1

Clinical Image

A 30-year-old male with a history of trisomy 21, unrestricted VSD, Eisenmenger's syndrome with pulmonary arterial hypertension presented with increasing shortness of breath. A transthorac-

ic echocardiogram revealed a massive pericardial effusion with resulting cardiac tamponade. An arterial line showed significant drop in his systolic blood pressures during inspiration which is shown in the image below.

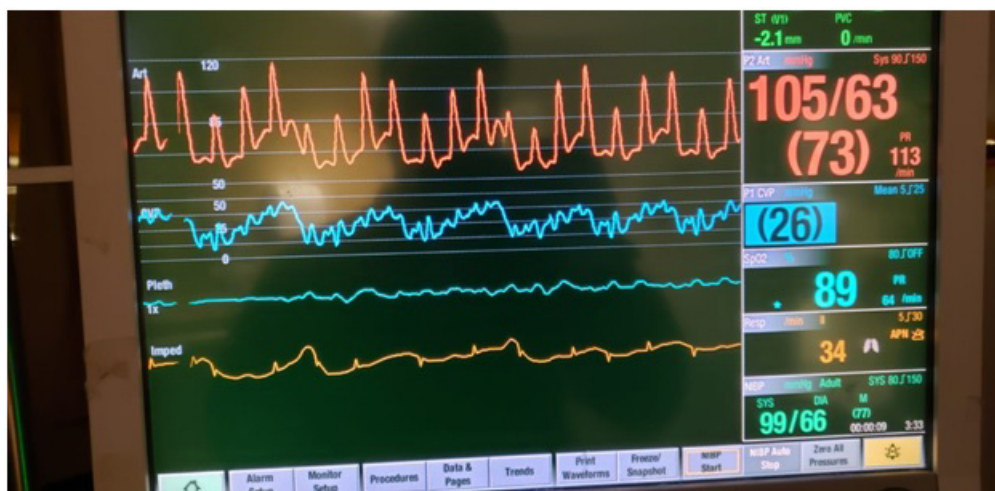


Figure 1: Pulsus Paradoxus in a 30-year-old Patient