

Von Recklinghausen's Disease Associated with Pheochromocytoma and Gastrointestinal Stromal Tumors: A Case Report

Buils F^{1,2*}, Bartra E¹, Domenech J^{1,2}, Sanchez JJ^{1,2}, Prieto R^{1,2}, Homs E¹, Martinez P¹, Garcia MA¹, Sanchez A^{1,2} and Del Castillo D^{1,2}

¹Department of General and Digestive Surgery. Sant Joan University Hospital, Reus, Tarragona, Spain

²Rovira I Virgili University, Faculty of Medicine and Health Sciences, Surgery Unit, Tarragona, Spain

*Corresponding author:

Buils Vilalta Francisco J,
Department of General and Digestive Surgery,
Sant Joan University Hospital,
Av. del Dr. Josep Laporte, Reus, Tarragona,
Spain, E-mail: clinicsurg@gmail.com

Received: 22 June 2021

Accepted: 12 July 2021

Published: 17 July 2021

Copyright:

©2021 Buils F, et al. This is an open access article distributed under the terms of the Creative Commons Attribution License, which permits unrestricted use, distribution, and build upon your work non-commercially.

Citation:

Buils F. et al., Von Recklinghausen's Disease Associated with Pheochromocytoma and Gastrointestinal Stromal Tumors: A Case Report. Clin Surg. 2021; 5(14): 1-4

Keywords:

Neurofibromatosis type 1; Gastrointestinal stromal tumor; Pheochromocytoma; Von Recklinghausen disease

1. Abstract

Neurofibromatosis type-1 is a rare autosomal dominant disorder, caused by a mutation in the tumor suppressor gene NF1 which leads to a decreased production of the protein neurofibromin. We present a 59-year-old female with a history of von Recklinghausen's disease under study for symptoms of toxic syndrome accompanied by anemia and melena. The abdominal Computed Tomography (CT) scan revealed confirmed a tumor of the left adrenal gland, 6 cm in diameter and images compatible with GIST in the small intestine affecting several intestinal loops. The study is completed with the performance of colonoscopy and PET/CT. After preoperative preparation with α - and β -adrenoreceptor blockade, both adrenal tumor and ileoterminal GIST were resected. There were no post-surgical complications and the patient was released 10 days after the procedure.

2. Introduction

Neurofibromatosis type-1 (NF1), which is also known as von Recklinghausen's disease, is a rare autosomal dominant disorder, caused by a mutation in the tumor suppressor gene NF1 which leads to a decreased production of the protein neurofibromin and subsequently to the risk of developing benign or malignant tumors with a variety of clinical symptoms [1]. Malignancies are found in 3% to 15% of patients. Genetically it is caused by a mutation at the NF1 gene located on chromosome 17q11.2. [2] Functionally neurofibromin reduces cell proliferation by accelerating the

inactivation of the proto-oncogene p21-ras, which plays a cardinal role in mitogenic intracellular pathways [3]. Although genetic mutations have been described and the responsible gene product neurofibromin has been fully characterized, no frequently recurring mutation has been identified, and diagnosis is still based on established clinical criteria. The disease is characterized by skin lesions called café-au-lait spots cutaneous neurofibromas and neoplasms of the peripheral or central nervous system [4]. It is known that von Recklinghausen's disease is occasionally associated with pheochromocytoma development and also to a larger extent with GIST. The incidence of pheochromocytoma is 2-8 per 1,000,000 [5] and a total of 4-25% of patients with NF1 may also present with gastrointestinal stromal tumors (GIST) [6, 7]. In these patients, gastrointestinal stromal tumors are most frequently located along the small intestine, in contrast to gastrointestinal stromal tumors that occur sporadically or as part of other inherited syndromes [8]. The objective of this article is to report a rare entity; NF1 occurring in combination with pheochromocytoma and gastrointestinal stromal tumors (GIST) Written informed consent for publication of personal and medical information were obtained from the patient.

3. Case Report

A 59-year-old female, diagnosed of neurofibromatosis type 1 in youth with positive familiar history and poorly controlled hypertension was admitted to our hospital for symptoms of toxic syndrome accompanied by anemia and melena. She denied any aller-

gies and regularly used antihypertensive medication. Upon physical examination, the patient was found to have multiple, diffuse soft-tissue lesions measuring 1-4 cm in diameter located throughout her body, in addition to diffuse macules on the skin. Neither abdominal palpation mass nor percussion pain were observed on abdominal examination. A computed tomography (CT) disclosed a GIST- compatible images in the small intestine at the pelvic level that affects several intestinal loops (Figure 1). Also a 5.2 cm mass in left adrenal gland was observed (Figure 2). Previous prepara-

tion with alpha and beta-blockers as well as calcium antagonists for 1 week an ultrasound-guided biopsy of the pelvic mass is performed, confirming the GIST diagnosis. The study was completed with the performance of a colonoscopy (without pathological findings) and a PET/CT report of hypermetabolic left adrenal injury and hypermetabolic pelvic mass infiltrating intestinal loops with questionable involvement of the urinary bladder. Laboratory examination showed catecholamine elevation in serum and urine.

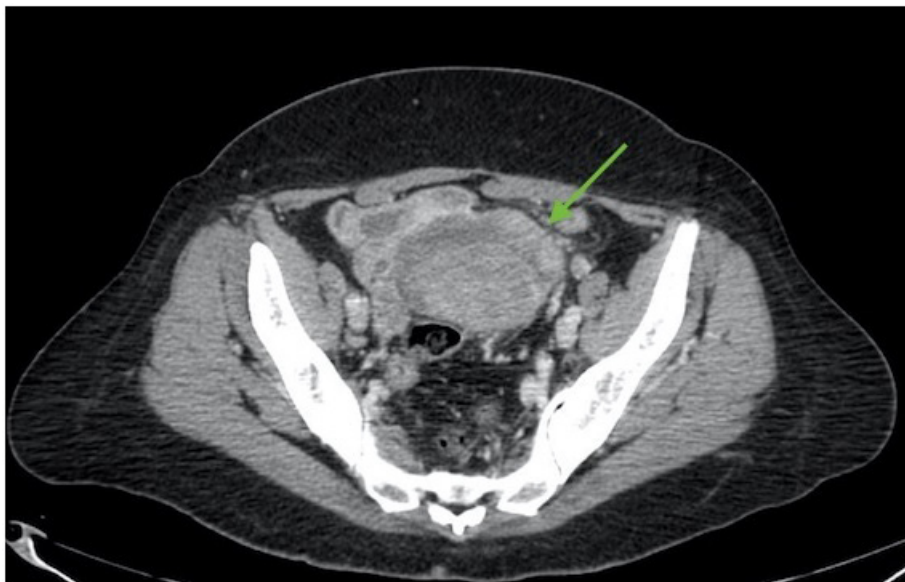


Figure 1: Abdominal CT: GIST in the small intestine at the pelvic level (green arrow)

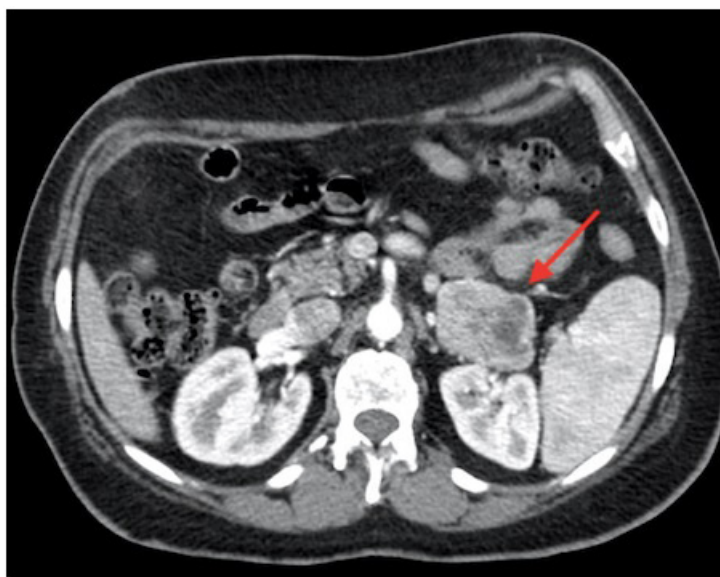

Figure 2: Abdominal CT: expansion of the left adrenal gland (red arrow)

According to the multidisciplinary (gastroenterologist, oncologist, radiologist, endocrinologist and surgeon) committee's decision, the patient was advised to undergo a surgical treatment. After preoperative preparation with α - and β -adrenoreceptor blockade, an open surgery was performed. Both adrenal tumor and approximately 70 cm of the small intestine was removed by resection of a

ileum segment, which contains at the central level a lesion greater than 90 mm, which produces adhesion of the loop and ulceration of the mucosa with central hemorrhage (Figure 3). In addition, multiple sub serous nodular lesions ranging from 1 to 30 mm were also resected (Figure 4).

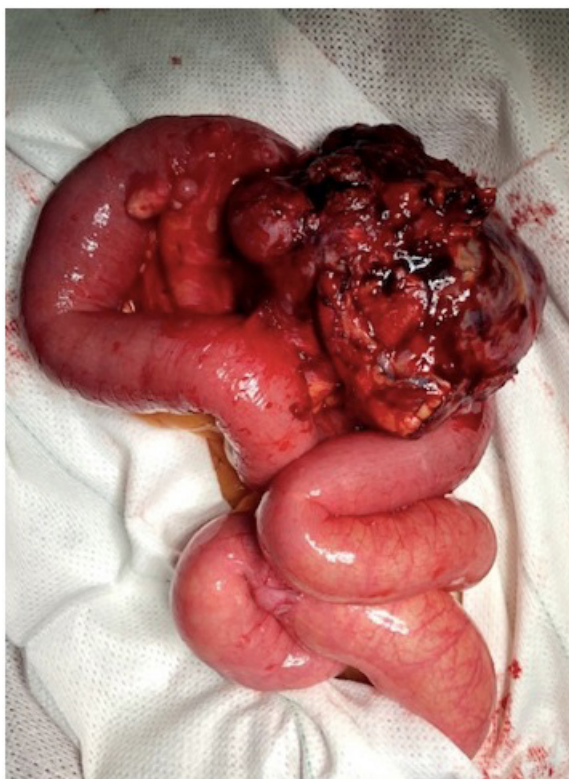

Figure 3: Large intestinal GIST

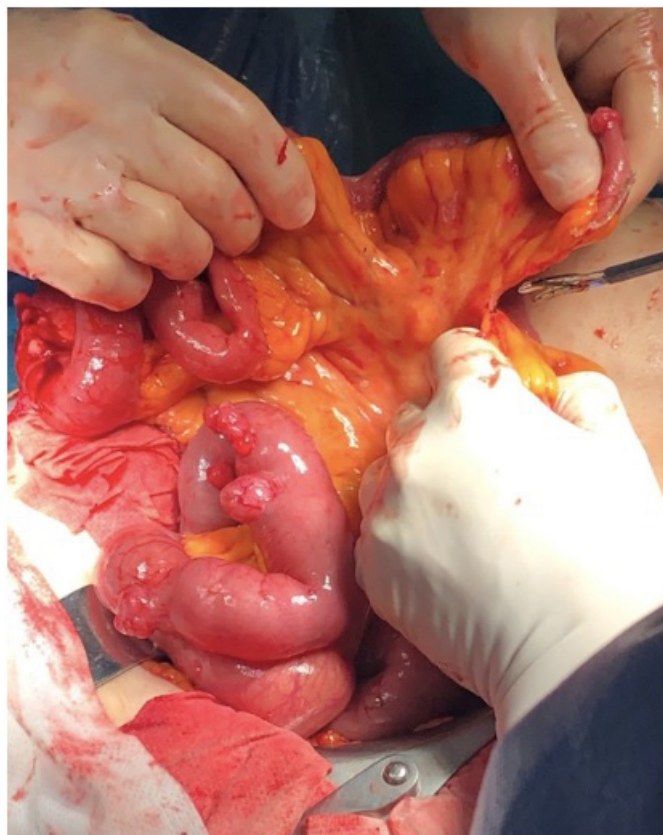

Figure 4: Several small ideal gastrointestinal stromal tumors

During preparation of the left adrenal gland a hypertensive crisis occurred resulting in hypotension after adrenalectomy. Both could be resolved by anesthesiological intensive care support. The resected tumor from the left adrenal gland had a maximum diameter of 5 cm (Figure 5). Microscopic and immunohistochemically examination confirmed pheochromocytoma with expression of both S100 protein and Chromogranin-A. All intestinal tumors proved to be gastrointestinal stromal tumors and established by positive staining to CD 117 and negative to S100. Molecular analysis of KIT (exons 9,11) and platelet-derived growth factor receptor-alpha (PDGFRA) revealed no somatic mutations. There were no post-surgical complications, except superficial infection of the surgical wound, and the patient was released 10 days after the procedure. Seven months after surgery, a routine control PET/CT scan showed nodular lesion in the jejuna loop wall, distal to the Treats angle without metabolic characterization.

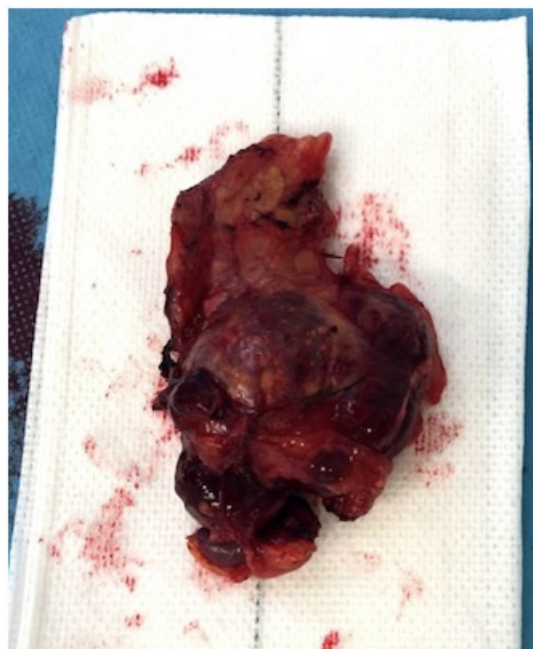

Figure 5: Resected left adrenal tumor

4. Discussion

According to the guidelines for the diagnosis and management of NF-1, the typical age of onset of the major clinical manifestations is in childhood or adolescence. The diagnosis can be made according to the clinical criteria as defined by the National Institutes of Health Consensus Stament [9]. The GISTs observed in NF1 patients are generally multiple in number and predominally located within the small intestine.

Most of these tumors cause no symptoms until they grow large in size, as in our case. However, making an early diagnosis of these lesions is important due to the risk of malignancy, systemic complications associated with pheochromocytoma and hemorrhagic obstructive complications associated with GISTs.

Despite certain radiologic differences with neurogenic neoplasm, a final diagnosis of gastrointestinal stromal tumor often is not obtained before surgery. If fine-needle aspiration in a patient with neurofibromatosis 1 is possible it offers a safe method for preoperative diagnosis of these tumors.

Because many gastrointestinal stromal tumors are located in or adjacent to the gastric or small intestinal wall, conventional endoscopy may not be feasible and gastrointestinal stromal tumors may be missed. Positron emission tomography scanning also has been suggested as a possible diagnostic technique [10].

However, it is very rare that these three disorders (NF1, GIST and pheochromocytoma) occur simultaneously. To the best of our knowledge, there have only been less than 20 documented cases of NF1 with concurrent pheochromocytoma and GIST lesions previously published in the literature.

In our case, due to the size and number of mitosis, she would have had to perform adjuvant treatment, since it is high risk according to Miettinen criteria. But due to the absence of mutations, it was decided not to carry out treatment, adopting an expectant attitude with a strict follow-up.

5. Conclusion

patients with von Recklinghausen neurofibromatosis the appearance of gastrointestinal symptoms should raise interest to search for gastrointestinal tumors because these patients are at risk for gastrointestinal neoplasms. Therefore, a pheochromocytoma should be excluded before a patient with neurofibromatosis 1 undergoes surgery for a gastrointestinal stromal tumor because an undiagnosed pheochromocytoma carries a high risk of life-threatening cardiovascular complications during surgery.

References:

1. Theos A, Korf BR. Pathophysiology of neurofibromatosis type 1. *Ann Intern Med.* 2006; 144: 842-9.
2. Kramer K, Hasel C, Aschoff A, Bruns HD, Wuerl P. Multiple gastrointestinal stromal tumors and bilateral pheochromocytoma in neurofibromatosis. *World J Gastroenterol.* 2007; 13: 3384-7.
3. Agaimy A, Vassos N, Croner R. Gastrointestinal manifestations of neurofibromatosis type 1 (Recklinghausen's disease): Clinopathological spectrum with pathogenetic considerations. *Int J Clin Exp Pathol.* 2012; 5: 852-62.
4. Dongfeng P, Peifeng L, Honggyan X. Neurofibromatosis type 1 associated with pheochromocytoma and gastrointestinal stromal tumors: A case report and literature review. *Oncology Letters.* 2016; 12: 637-43.
5. Poredska K, Kunovsky L, Prochazka V. Triple malignancy (NET, GIST and pheochromocytoma) as a first manifestation of neurofibromatosis type-1 in an adult patient. *Diagnostic Pathology.* 2009; 14: 77.
6. Fung MM, Viveros O H, O'Connor D T. Diseases of the adrenal medulla. *Acta Physiol.* 2008; 192: 325-35.

7. Miettinen M, Lasota J. Gastrointestinal stromal tumors: review on morphology, molecular pathology, prognosis, and differential diagnosis. *Arch Pathol Lab Med.* 2006; 130: 1466-78.
8. Kramer K, Hasel C, Aschoff AJ, Bruns HD, Wuerl P. Multiple gastrointestinal stromal tumors and bilateral pheochromocytoma in neurofibromatosis. *World J Gastroenterol.* 2007; 13: 3384-7.
9. Myrella V, Uta F, Lorenz C. Pheochromocytoma and gastrointestinal stromal tumors in patients with neurofibromatosis type I. *The American Journal of Medicine.* 2013; 126: 174-80.
10. Bummig P, Nilsson B, Sörensen J, Nilsson O, Ahlman H. Use of 2-tracer PET to diagnose gastrointestinal stromal tumour and pheochromocytoma in patients with Carney triad and neurofibromatosis type 1. *Scand J Gastroenterol.* 2006; 41: 626-30.