

## Deep Lateral and Endoscopic Inferomedial Orbital Decompression Combined with Injection of BTA for Extraocular Muscles in A Patient with TAO

Li Q\*, An N\*, Piao J, Wei Y, Zhu J and Liu J

Department of ophthalmology, Ningxia Eye Hospital, Peoples' Hospital of Ningxia Hui Autonomous Region, China

### \*Corresponding author:

Qian Li, Department of ophthalmology, Ningxia Eye Hospital, Peoples' Hospital of Ningxia Hui Autonomous Region, Ningxia Clinical Research Center on Disease of Blindness in Eye, First Affiliated Hospital of Northwest University for Nationalities, Yinchuan, Ningxia 750000, China, Tel: 86-18295211905; E-mail: 1801887056@qq.com

Received: 03 Aug 2021

Accepted: 14 Aug 2021

Published: 18 Aug 2021

### Copyright:

©2021 Li Q et al. This is an open access article distributed under the terms of the Creative Commons Attribution License, which permits unrestricted use, distribution, and build upon your work non-commercially.

### Keywords:

Endoscopic inferomedial orbital decompression; Deep lateral orbital decompression; Injection of BTA; TAO

### Citation:

Li Q. et al., Deep Lateral and Endoscopic Inferomedial Orbital Decompression Combined with Injection of BTA for Extraocular Muscles in A Patient with TAO. Clin Surg. 2021; 6(3): 1-6

### 1. Abstract

Thyroid Associated Ophthalmopathy (TAO) is a progressive and debilitating autoimmune disorder. Some patients would suffer expansion of extraocular muscles and orbital fat causing proptosis and diplopia, and compressive optic neuropathy causing vision loss. However, management for these severe cases remains a dilemma. Because it is difficult for traditional surgeries to simultaneously broaden orbital space, relieved pressure on optic nerve and eyeball, and shrink the enlarged extraocular muscles. This article presented a case of TAO with significant enlarged extraocular muscles and compressive optic neuropathy. We performed deep lateral and endoscopic inferomedial orbital decompression combined with directly injection of Botulinum Toxin A (BTA) in the belly of extraocular muscles for her. As a result, the afferent pupillary defect and optic disc edema was totally disappeared, the BCVA and visual field examination notably improved, and the intraocular pressure and proptosis returned normal after surgery. New-onset diplopia or worsening diplopia was not observed during follow-up. This case highlighted that adequate orbital decompression provides an added anatomical space for the expansion of enlarged extraocular

muscles, thereby extremely relieving pressure being exerted on the optic nerve. In addition, we postulated that extraocular muscles may shrink after repeated injection of high concentration of BTA. But the optimal patient selection, dosage, frequency, and main side effects of treating TAO with BTA injection still need further study.

### 2. Introduction

Thyroid Associated Ophthalmopathy (TAO) is a progressive and debilitating autoimmune disorder that results in orbital disfigurement, diplopia, and even vision loss [1]. The complex signs and symptoms differ in two clinical courses of TAO. The initial active phase is characterized by orbital inflammation and enlargement of orbital and periorbital tissues. The patients exhibit eyelid swelling, orbital pain, chemosis and conjunctival injection, proptosis, eyelid retraction, diplopia, strabismus, and even compressive optic neuropathy in this period. The disease subsequently passing into inactive phase and is characterized by orbital fibrosis [2].

The management of TAO remains a dilemma for us because of the variability of its clinical course. For mild active/inactive patients, supportive therapy is necessary. Active moderate-to-severe patients need pulsed steroid therapy, while inactive moderate-to-se-

vere patients with disfiguring proptosis or restricting diplopia requires rehabilitative orbital decompression or strabismus surgeries. However, an orbital decompression should also be performed in emergency especially for cases of optic neuropathy and extreme corneal exposure [3].

Compression of the optic nerve occurs in 3-5% of patients [4] and restrictive strabismus may occur in 17% of all patients with TAO [1]. Though the orbital decompression can remove orbital fat, expand orbital volume, decrease orbital pressure, and relieve apical compression, while also reduce proptosis [5], the expansion of extraocular muscles remains a significant problem. Is there exist a method which could shrink the enlarged extraocular muscles simultaneously during orbital decompression?

Botulinum toxin A (BTA) injection has been considered as a favorable procedure in treating benign masseteric hypertrophy because of its effective reduction of the volume of masseter muscle and with no significant side effects [6]. In fact, BTA injection in the extraocular muscles has also been suggested to provide temporary relief of diplopia in selected patients during the active phase of TAO. The patients with  $20\Delta$  or less of deviation achieved effective result in preventing surgery after BTA injection in the termination of the extraocular muscles [7]. However, the muscle bellies rather than starting and ending point of extraocular muscles obviously enlarged in patients with TAO.

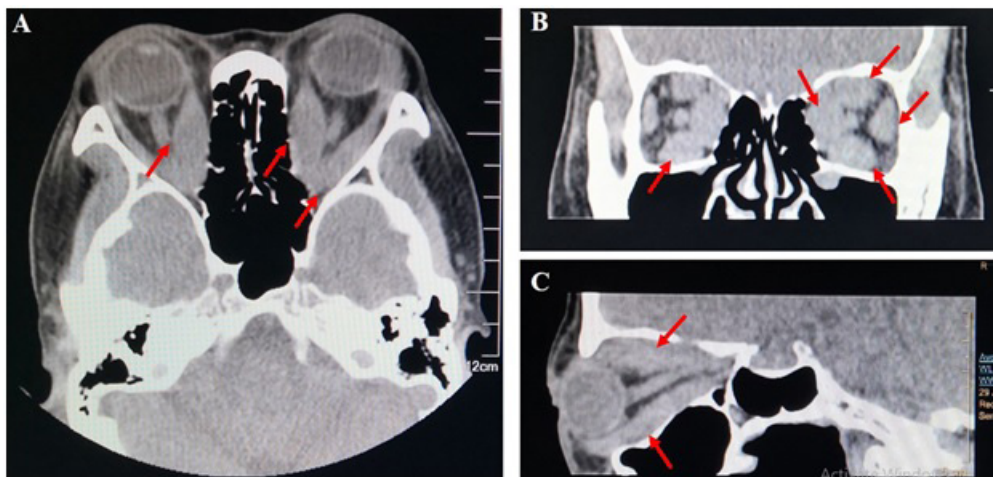
In order to solve these issues once, we attempted to perform deep lateral and endoscopic inferomedial orbital decompression combined with directly injection of BTA in the belly of extraocular

muscles for TAO patients with compression of the optic nerve and restrictive strabismus.

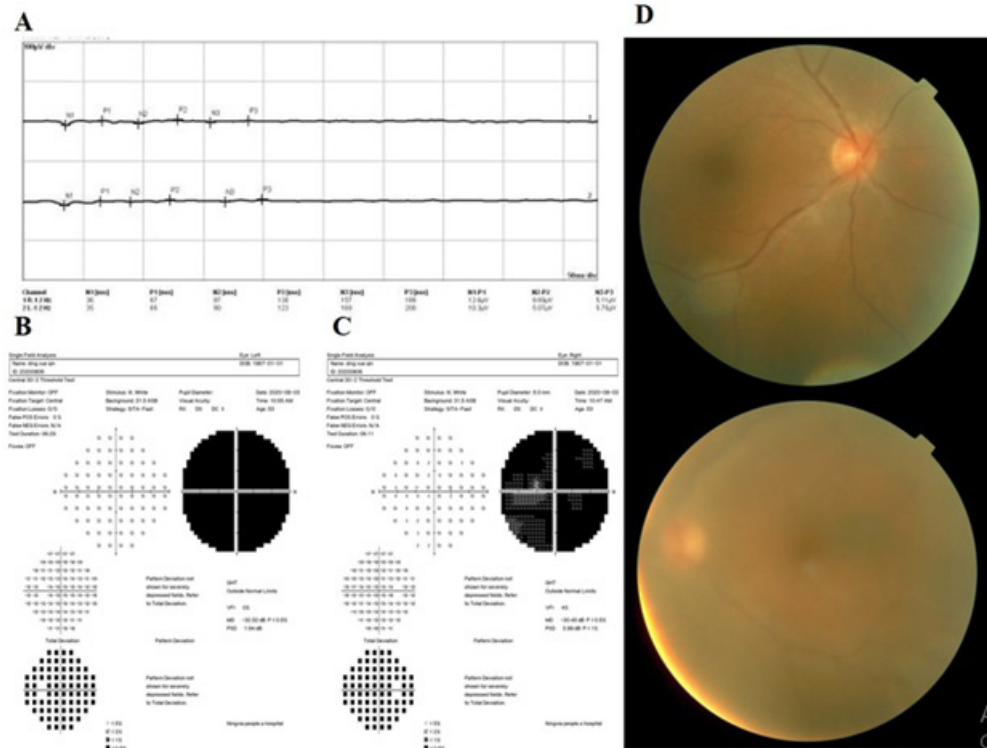
### 3. Materials & Methods

This study was approved by the Ethics Committee of Peoples' Hospital of Ningxia Hui Autonomous Region and conducted in accordance with the Declaration of Helsinki.

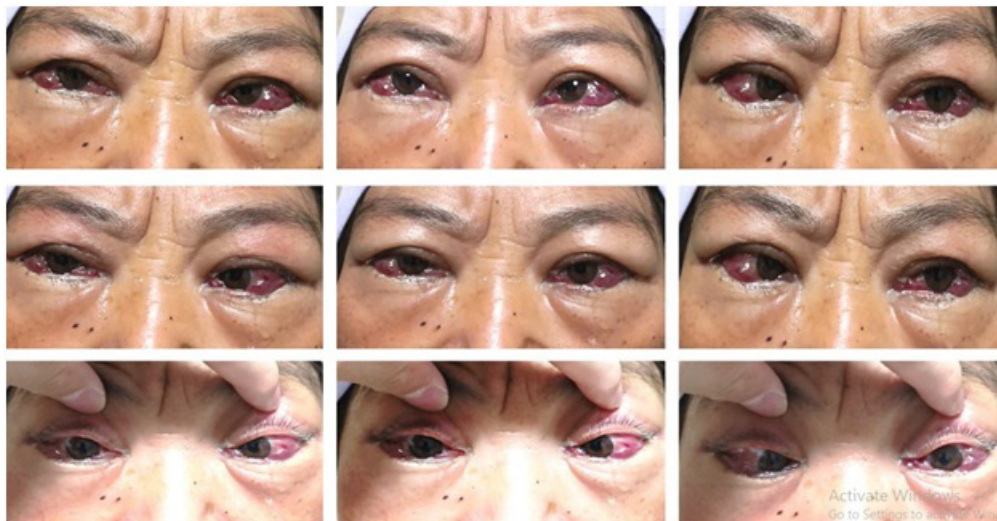A 53-year-old female was admitted to our hospital on August 3rd, 2020, complaining of binocular proptosis for 3 months. The patient had a history of Graves' disease for 3 months. Best-Corrected Vision (BCVA) was 2/20 OD and FC OS, with a left Relative Afferent Pupillary Defect (RAPD). Intraocular pressures were 20mmHg of two eyes. The proptosis was 22mm for right eye and 23mm for left eye, respectively. The patient had  $40\Delta$  left esotropia in primary position and significant limitation of movement in all directions expect inward movement. Slit lamp biomicroscopy showed conjunctival congestion and chemosis for both eyes, and lens opacity for left eye. Fundusoscopic examination demonstrated optic disc edema OS. Goldman visual field testing showed total vision defect OU with much more serious situation of left eye. Visual evoked potential amplitude decreased OS. Orbital CT demonstrated enlarged medial rectus, inferior rectus, and superior rectus of both eyes, and enlarged lateral rectus of left eye. The space of orbital apex was almost occupied by the extraocular muscles and the optic nerve was obviously compressed (Figure 1). (Figure 2) displayed the VEP, photograph of fundus and perimetry of the patient before surgery. (Figure 3) showed eye movement in nine directions of the patient.



**Figure 1:** Horizontal Orbital CT demonstrated expansion of medial rectus for both eyes and expansion of lateral rectus (red arrow) of left eye (A). The space of orbital apex was almost occupied by the enlarged extraocular muscles (red arrow) and the optic nerve was significantly compressed in coronal and sagittal scanning (B and C).



**Figure 2:** Preoperative VEP test showed visual evoked potential amplitude decreased OS (A). Goldman visual field testing showed total vision defect OU with much more serious situation of left eye (B, C). Funduscopic examination demonstrated optic disc edema OS (D).



**Figure 3:** Eye movement was almost totally limited in nine directions.

The patient received orbital surgery of left eye under general anesthesia on August 7th, 2020. A standard total intranasal endoscopic sphenoidectomy was carried out using a 4.0mm and 45° endoscopes (Karl Storz, Tuttlingen, Germany). The superior wall of maxillary sinus was removed to expose the inferior rectus. The medial part of the lesser wing of the sphenoid bone at the orbital apex was thinned using a microdrill (XPS3000, Medtronic, Jacksonville, FL). Then the thinned sphenoid bone and medial orbital wall were totally removed. The medial periosteum was incised to release orbital fat in muscle cones. The assistant gently pressed the globe to encourage further prolapse of fibroadipose tissue. The intraconal fat between the medial and inferior rectus was absorbed using a suction cutter. The orbital fat was excised until the clinicofsurgery.com

orbital pressure obviously decreased and the globe receded. BTA (Lanzhou, China) was prepared immediately prior to injection following standard procedures and diluent. The final concentration of 5U/0.1 cc was used. 20U of BTA was injected to the belly of medial rectus muscle and inferior rectus muscle, respectively. The transorbital deep lateral decompression began with exposure the periosteum of lateral orbital rim. Made an incision parallel to the axis of the orbit and elevated to develop a subperiosteal plane into the deep orbit. Then dissected posteriorly to expose the tip of the inferior and superior orbital fissures. Grinded the greater wing of the sphenoid anterior and superior to the tip of the inferior orbital fissure with the microdrill. Boney removal proceed until the inferior orbital fissure is skeletonized. The diploic space then be grinded

superiorly to the region of the superior orbital fissure. The pocket of thick bone extending anterior from the tip of the superior orbital fissure to the frontozygomatic suture was removed. Finally, the lateral rectus muscle was also injected with 20U of BTA. Same surgery was performed for right eye 1 week later except for injection of BTA to the lateral rectus.

#### 4. Results

First review was carried out 1 month later after surgeries. Ophthalmic examinations revealed BCVA of 5/20 OU, and intraocular pressure was 13mmHg of two eyes. The proptosis was 14mm for right eye and 15mm for left eye, respectively. The afferent pupillary defect had been resolved and optic disc edema was totally relieved. Goldman visual field testing showed enlargement of physiologic blind spot and downgrade of visual sensitivity OU. However, an increasing ratio of mistakes (45%), perhaps induced by asthenopia, crept into her visual field-testing process of right eye. The patient completed her last follow-up visit 1 year later after surgery. Visual evoked potential amplitude decreased OS. Goldman visual field testing demonstrated slightly decrease of visual sensitivity OS. Ophthalmic examinations revealed no obvious change compared with her first review except significant limitation of inward movement. The patient had 40 $\Delta$  esotropia of left eye in primary position. Orbital CT manifested mild diminution of extraocular muscles.

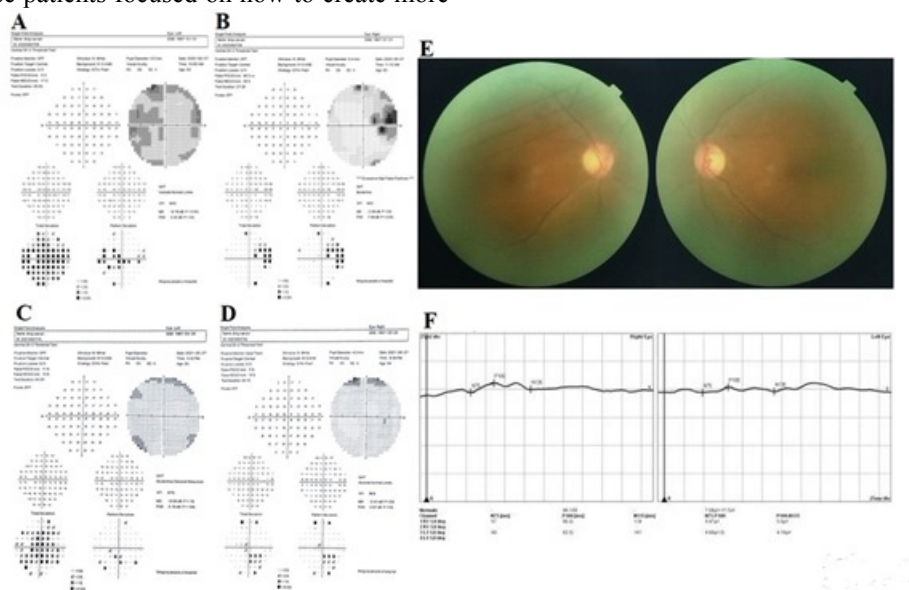
#### 5. Discussion

The orbital architecture could be potentially disrupted during the progression of TAO [8]. Consequently, patients would suffer expansion of orbital fat and extraocular muscles causing proptosis, extraocular motility restriction causing diplopia, and compressive optic neuropathy causing vision loss in some severe cases [9]. Thus, treatment for these patients focused on how to create more

space for the optic nerve, immediately and effectively relieving pressure, and reduce subsequent tissue remodeling in extraocular muscles.

The alternate high doses of intravenous steroids for 2 consecutive weeks remains the primary treatment of sight-threatening TAO patients [10]. However, cases where compressive optic neuropathy is refractory to steroid treatment or where there is immediate risk to vision will require emergency orbital decompression [3].

Anatomically, the orbital apex is the narrowest area of the orbit, and the optic nerve lies near the medial rectus in the area of annulus of Zinn [11]. Therefore, combined medial wall and inferomedial orbital decompression is the most appropriate approach, with improvement or stabilization of visual acuity in 75-100% of cases with compressive optic neuropathy [12, 13]. Transnasal endoscopic medial and/or inferomedial wall decompression techniques pioneered in the last decades as videoendoscopic technology has advanced [14-16]. The surgery provides excellent visualization and a direct pathway to the ethmoid roof and orbital apex. In our case, we performed endoscopic transnasal uncinectomy, sphenoidectomy and maxillary antrostomy to the post wall of the maxillary sinus, followed by removal of lamina to the minor wing of sphenoid. The removal of the lamina papyracea and medial orbital floor enables the enlarged extraocular muscles to decompress into the ethmoid and maxillary sinuses. In addition, we also removed intraconal fat between the medial and inferior rectus. These procedures extremely relieved pressure on optic nerve and eyeball, broaden orbital volume, and allowed the bulb of the eye to recess back into the orbit. As a result, the afferent pupillary defect and optic disc edema was totally disappeared, the BCVA and visual field examination notably improved, and the intraocular pressure and proptosis returned normal after surgery (Figure 4).



**Figure 4:** Goldman visual field testing showed enlargement of physiologic blind spot and downgrade of visual sensitivity OU 1 month after surgery (A, B). The patient completed her last follow-up visit 1 year later after surgery. Goldman visual field testing demonstrated slightly decrease of visual sensitivity OS (C, D). The optic disc edema was totally disappeared (E), and VEP returned normal after surgery (F).

However, postoperative diplopia and strabismus may occur because of the ocular recession the vector of pull for the extraocular muscles change [17]. Hence, we took some steps including preservation of the inferomedial bone strut, and performance of “balanced orbital decompression” to reduce the incidence of the complication. It has been proved preservation of the bony strut at the maxillary–ethmoid junction could effectively reduce displacement of the muscle cone and orbital connective tissue into the maxillary and ethmoidal sinuses [18, 19]. According to previous report, leaving an intact periorbita significantly compromises the risk of new-onset diplopia [20]. However, the technique is not appropriate for the surgical treatment of all patients with TAO, especially in cases of optic neuropathy. The rationale of orbital decompression is to achieve maximum possible degree of apical decompression for these patients who have crowding at the orbital apex. Therefore, we completely remove the lamina papyracea, the anterior wall of the sphenoid sinus adjacent to the optic canal, and periorbita in the region of the orbital apex. We believe these measures are necessary to enhance the likelihood of return of vision.

Lateral decompression concurrent with medial and inferior wall decompression is thought to be a more “balanced approach” may reduce the degree of medial rectus prolapse and reduce postoperative dysmotility [21, 22]. The rate of postoperative diplopia decreases to 11%-16% in “balanced decompression” than in classic inferomedial transantral or endoscopic technique [23, 24]. We simultaneously executed deep lateral decompression with resection of lateral orbital rim and drilling of the sphenoid as far as the superior and inferior orbital fissure. New-onset diplopia or worsening diplopia was not observed in our patient. Although the patient had 40Δ esotropia in primary position of her left eye, the situation existed from the orbitopathy itself before surgery.

During the development of TAO, plenty of highly hydrophilic glycosaminoglycans and collagen fibrils accumulate in orbital tissues [1]. The extraocular muscles then significantly swollen, lost its elasticity and undergo fibrosis. The enlarged extraocular muscles exert pressure on the optic nerve in the anterior part of the orbital apex within the intraconal space. After orbital decompression, the crowded and thickened extraocular muscles were forced to bulge into newly created orbital space allowing for a lengthening of the muscle bellies and an improvement in contractile ability [20]. But the muscle volume remained expansile.

BTA acts by inhibiting the release of the acetylcholine neurotransmitter by acting on the peripheral cholinergic motor nerve endings at the neuromuscular junction which ultimately reduces muscle action. More importantly, high concentration of BTA causes cell apoptosis and subsequently results muscle atrophy [25]. 20-50 U intra-muscular injection of BTA is proved to reduce the bulk of the masseter muscle [26]. To further shrink the extraocular muscles and alleviate the compromise to optic nerve, we injected 20U of BTA to the belly of medial, inferior, and lateral rectus. The ef-

fect of BTA is short-term and gradually weakened within 2 to 4 months after injection [27]. The patients who received 3 injections maintained better and more effective decrease of masseter volume compared to a single dose [28]. In our study, the post-operative orbital CT showed mild reduction of extraocular muscle volume. We think the primary cause referred to the patient had not received continuous injection of BTA. Muscle atrophy results from the delay or prevention of muscle fiber regeneration after BTA injection [29, 30]. It is difficult to achieve the effect after single injection.

## 6. Conclusion

In conclusion, we described a deep lateral wall decompression and endoscopic inferomedial orbital decompression combined with directly injection of BTA in extraocular muscles for TAO patients with compression of the optic nerve and restrictive strabismus. We considered that the adequate orbital decompression provides an added anatomical space for the expansion of enlarged extraocular muscles, thereby extremely relieving pressure being exerted on the optic nerve. In addition, we postulated that extraocular muscles may shrink after repeated injection of high concentration of BTA. However, the optimal patient selection, dosage, frequency, and main side effects of treating TAO with BTA injection still need further study. Future clinical studies employing these techniques in a larger number of cases may give us better insight regarding its efficacy.

## 7. Funding

This work was supported by the National Natural Science Foundation of China (81960184), Ningxia Key Research and Development Program (Special Talents) (2018beb04023) and Nurturing and Revitalizing Projects of Peoples’ Hospital of Ningxia Hui Autonomous Region (201901)” in the acknowledgement section of the manuscript.

## References

1. Bahn RS. Graves’ ophthalmopathy. *N Engl J Med.* 2010; 362: 726-38.
2. Smith TJ. Challenges in Orphan Drug Development: Identification of Effective Therapy for Thyroid-Associated Ophthalmopathy. *Annu Rev Pharmacol Toxicol.* 2019; 59: 129-48.
3. Bartalena L. The 2016 European Thyroid Association/European Group on Graves’ Orbitopathy Guidelines for the Management of Graves’ Orbitopathy. *Eur Thyroid J.* 2016; 5: 9-26.
4. Verity DH, Rose GE. Acute thyroid eye disease (TED): principles of medical and surgical management. *Eye (Lond).* 2013; 27: 308-19.
5. Rootman DB. Orbital decompression for thyroid eye disease. *Surv Ophthalmol.* 2018; 63: 86-104.
6. Cheng J, Hsu SH, McGee JS. Botulinum Toxin Injections for Masseter Reduction in East Asians. *Dermatol Surg.* 2019; 45: 566-72.
7. Akbari MR. Management of Thyroid Eye Disease-Related Strabismus. *J Curr Ophthalmol.* 2020; 32: 1-13.

8. Taylor PN. New insights into the pathogenesis and nonsurgical management of Graves orbitopathy. *Nat Rev Endocrinol.* 2020; 16: 104-16.
9. McKeag D. Clinical features of dysthyroid optic neuropathy: A European Group on Graves' Orbitopathy (EUGOGO) survey. *Br J Ophthalmol.* 2007; 91: 455-8.
10. Phillips ME, Marzban MM, Kathuria SS. Treatment of thyroid eye disease. *Curr Treat Options Neurol.* 2010; 12: 64-9.
11. Martins C. Microsurgical anatomy of the orbit: the rule of seven. *Anat Res Int.* 2011; 2011: 468727.
12. Liao SL, Chang TC, Lin LL. Transcaruncular orbital decompression: an alternate procedure for Graves ophthalmopathy with compressive optic neuropathy. *Am J Ophthalmol.* 2006; 141: 810-8.
13. Korkmaz S, Konuk O. Surgical Treatment of Dysthyroid Optic Neuropathy: Long-Term Visual Outcomes with Comparison of 2-Wall versus 3-Wall Orbital Decompression. *Curr Eye Res.* 2016; 41: 159-64.
14. Michel O. Follow-up of transnasal orbital decompression in severe Graves' ophthalmopathy. *Ophthalmology.* 2001; 108: 400-4.
15. Gulati S. Long-term follow-up of patients with thyroid eye disease treated with endoscopic orbital decompression. *Acta Ophthalmol.* 2015; 93: 178-83.
16. Lv Z. Endoscopic Orbital Fat Decompression with Medial Orbital Wall Decompression for Dysthyroid Optic Neuropathy. *Curr Eye Res.* 2016; 41: 150-8.
17. Metson R, Samaha M. Reduction of diplopia following endoscopic orbital decompression: the orbital sling technique. *Laryngoscope.* 2002; 112: 1753-7.
18. Bleier BS, Lefebvre DR, Freitag SK. Endoscopic orbital floor decompression with preservation of the inferomedial strut. *Int Forum Allergy Rhinol.* 2014; 4: 82-4.
19. Mainville NP, Jordan DR. Effect of orbital decompression on diplopia in thyroid-related orbitopathy. *Ophthalmic Plast Reconstr Surg.* 2014; 30: 137-40.
20. Finn AP. A Retrospective Review of Orbital Decompression for Thyroid Orbitopathy with Endoscopic Preservation of the Inferomedial Orbital Bone Strut. *Ophthalmic Plast Reconstr Surg.* 2017; 33: 334-9.
21. Leone CJ, Piest KL, Newman RJ. Medial and lateral wall decompression for thyroid ophthalmopathy. *Am J Ophthalmol.* 1989; 108: 160-6.
22. Shepard KG, Levin PS, Terris DJ. Balanced orbital decompression for Graves' ophthalmopathy. *Laryngoscope.* 1998; 108: 1648-53.
23. Silver RD, Harrison AR and G.S. Goding GS. Combined endoscopic medial and external lateral orbital decompression for progressive thyroid eye disease. *Otolaryngol Head Neck Surg.* 2006; 134: 260-6.
24. Franceschini SS. Orbital decompression in graves' ophthalmopathy by medial and lateral wall removal. *Otolaryngol Head Neck Surg.* 2005; 133: 185-9.
25. Fang PK. Analysis of genomic differences among *Clostridium botulinum* type A1 strains. *BMC Genomics.* 2010; 11: 725.
26. Matarasso SL. Comparison of botulinum toxin types A and B: a bilateral and double-blind randomized evaluation in the treatment of canthal rhytides. *Dermatol Surg.* 2003; 29: 7-13.
27. Shome D. Botulinum toxin A: is it really that fragile a molecule? *Dermatol Surg.* 2010; 36: 2106-10.
28. Shome D, Khare S, Kapoor R. Efficacy of Botulinum Toxin in Treating Asian Indian Patients with Masseter Hypertrophy: A 4-Year Follow-Up Study. *Plast Reconstr Surg.* 2019; 144: 390-6.
29. Moon YM. Apoptotic action of botulinum toxin on masseter muscle in rats: early and late changes in the expression of molecular markers. *Springerplus.* 2016; 5: 991.
30. Borodic GE. Histologic assessment of dose-related diffusion and muscle fiber response after therapeutic botulinum A toxin injection. *Mov Disord.* 1994; 9: 31-9.