

## Clinical Analysis of Safety and Long-Term Impacts on Quality of Life of Segmental Bowel Resection for Bowel Endometriosis: A Single-Centre Follow-Up

Duo Liu<sup>1</sup>, Na Yang<sup>2</sup>, Yanchun Liang<sup>1</sup>, Ming Chen<sup>1</sup>, Wenwei Pan<sup>1</sup> and Shuzhong Yao<sup>1\*</sup>

<sup>1</sup>Department of Obstetrics and Gynecology, First Affiliated Hospital of Sun Yat-sen University, Guangzhou 510080, Guangdong, China

<sup>2</sup>Department of Operating Room, First Affiliated Hospital of Sun Yat-sen University, Guangzhou 510080, Guangdong, China

### \*Corresponding author:

Shuzhong Yao,  
Department of Obstetrics and Gynecology, First  
Affiliated Hospital of Sun Yat-sen University,  
Guangzhou 510080, Guangdong, China,  
Tel: +86-020-87606902;  
E-mail: zsy\_ysz@163.com

Received: 20 Nov 2021

Accepted: 13 Dec 2021

Published: 18 Dec 2021

J Short Name: COS

### Copyright:

©2021 Shuzhong Yao. This is an open access article distributed under the terms of the Creative Commons Attribution License, which permits unrestricted use, distribution, and build upon your work non-commercially.

### Citation:

Shuzhong Yao, Clinical Analysis of Safety and Long-Term Impacts on Quality of Life of Segmental Bowel Resection for Bowel Endometriosis: A Single-Centre Follow-Up. Clin Surg. 2021; 6(13): 1-8

### Keywords:

Bowel endometriosis; Segmental bowel resection; Pain; Quality of life

## 1. Abstract

**1.1. Aim:** To evaluate the long-term efficacy of segmental bowel resection for bowel endometriosis and the impact of post-operative complications on clinical outcomes.

**1.2. Methods:** 62 symptomatic patients with bowel endometriosis undergoing segmental bowel resection from Jun. 2010 to Jan. 2014 were recruited. A visual analogue scale (VAS) and SF-36 questionnaire were administered before and at least 5 years after surgery. Post-operative complications and pregnancy were also recorded. Median follow-up after operation was 76 months (62-105 months).

**1.3. Results:** 62 patients underwent laparoscopic segmental bowel resection, one of which converted to laparotomy. All patients complained of obvious pain symptoms, including dysmenorrhea, dyspareunia, bowel movement pain, chronic pelvic pain and tenesmus. Dysmenorrhea was the most frequent. The relief of all pain symptoms after surgery was statistically significant ( $P < 0.001$ ). The scores for 8 domains of SF-36 questionnaire were significant improved after operation ( $P < 0.001$ ), and the post-operative scores were improved to the level of Chinese female population. Post-operative complication included 18 cases of urinary retention, 4 rectovaginal fistulas, 2 cases of vaginal dehiscence, and 1 case each of thrombogenesis, diffuse peritonitis, peripheral nerve injury, bacteraemia, incomplete intestinal obstruction and mucus bloody stool. All of these patients recovered well. There was no significant difference in post-operative SF-36 questionnaire scores between

the patients with and without complications.

**1.4. Conclusion:** Segmental bowel resection can significantly relieve pain and improve long-term quality of life for patients with severe bowel endometriosis. Despite the relatively high complication rate, the complications had little impact on the improvement of quality of life.

## 2. Introduction

Endometriosis is a condition in which functional endometrial tissue, including glands and stroma, exist ectopically outside the uterine cavity and myometrium [1]. When ectopic lesion infiltrates into the subserosa or subserosus plexus of bowel and beyond, bowel endometriosis is diagnosed [2]. Approximately 3%-10% of women suffer from endometriosis during childbearing age, 5%-20% of which include bowel endometriosis. The rectum and sigmoid are the most common sites of involvement, accounting for more than 90% of all bowel endometriosis cases [3-5]. Bowel endometriosis, usually accompanied by lesions in other sites, can result in severe endometriosis-linked symptoms, such as dysmenorrhea, dyspareunia, chronic pelvic pain and infertility. Furthermore, because of bowel involvement, patients may complain of various intestinal symptoms, including bowel movement pain, tenesmus, diarrhoea, dyschezia, rectal bleeding, and very rarely, bowel occlusion, all of which can seriously affect quality of life [6,7].

Unfortunately, all medical treatments provide only temporary relief, and symptoms have a high recurrence rate after withdraw-

al, probably because up to 80% of bowel lesions have a fibrotic component [8,9]. Therefore, surgical resection of endometriosis lesions is the preferred treatment for severe symptomatic or frequent recurrent patients. Usually, there are three options for surgical treatment: shaving, disc resection and segmental bowel resection. A positive correlation has been found between the extent of the lesions to be resected and symptom relief [10]. Thus, we aim to remove the entire lesion, and segmental bowel resection may reach the maximal resection. Increasing number of gynaecologists have performed this complicated surgical technique and provided their patients with considerable relief, but the high complication rate and the long-term clinical outcomes must be noted [11, 12]. This study aim at evaluating the long-term safety and improvement for quality of life of segmental bowel resection to treat bowel endometriosis.

### 3. Patients and Methods

#### 3.1. Patients

62 bowel endometriosis patients who underwent segmental bowel resection at the Department of Gynaecology of the First Affiliated Hospital of Sun Yat-sen University from Jun. 2010 to Jan. 2014 were considered. Epidemiological characteristics of all patients are summarized in Table 1. We recruited patients who met the following criteria:

1. With severe endometriosis-linked pain or intestinal symptoms.
2. Of reproductive age.
3. Had not undergone endometriosis-related operation at least 1 year prior to our treatment.
4. Had a bowel mass  $\geq 3$  cm and with the whole bowel wall invasion. Operated by the same surgical team and had undergone radical resection of all lesions.
5. Had preoperative magnetic resonance imaging or rectal endoscopic criteria and post-operative is to pathological confirmation for bowel endometriosis.
6. Received follow up at least 5 years after operation.
7. Exclude inflammatory bowel disease, irritable bowel syndrome and tumour.

**Table 1:** Epidemiological characteristics of 62 patients.

Characteristic	Data
Age	37(23-44) <sup>a</sup>
Gestation	1(0-5) <sup>a</sup>
Parturition	1 (0-2) <sup>a</sup>
Previous pregnancy	34 (54.8%)
Infertility history	16 (25.8 %)
Previous surgery for endometriosis <sup>b</sup>	20 (32.3 %)
Previous medical treatment for endometriosis	17 (27.4 %)

a: Midian and range

b: None of the previous operations had involved the bowel lesion except one that consisted of only a simple biopsy for rectal lesion rather than resected lesion.

clinicsofsurgery.com

#### 3.2. Preoperative Assessment

Each patient completed a symptom questionnaires. Preoperative symptoms of all patients are summarized in Table 2. To evaluate pain, we used visual analogue scale (VAS) to evaluate the severity before surgery. The grades of pain were defined as follows: 0 (no pain), 1-3 (mild), 4-6 (moderated), and 7-10 (severe). A Short-Form 36 health survey questionnaire (SF-36 questionnaire) was administered to each patient before surgery. The SF-36 questionnaire consists of 36 questions that can be classified into 8 domains: physical functioning (RF), role physical (RP), bodily pain (BP), general health (GH), vitality (VT), social functioning (SF), role emotional (RE) and mental health (MH). Each domain can be scored respectively [13].

**Table 2:** Preoperative symptoms.

Symptom	n	Percent/%
Dysmenorrhea	56	90.3
Dyspareunia	19	30.6
Bowel movement pain	18	29.0
Chronic pelvic pain	24	38.7
Tenesmus	27	43.5
Dyschezia	14	22.6
Rectal bleeding	15	24.2
Diarrhoea	16	25.8

#### 3.3. Operation Procedure

Each patient was clearly informed of the high incidence of potential post-operative complications, and signed a dedicated informed consent form.

All of the patients underwent preoperative bowel preparation with 3000 ml macrogol solution and fasting for at least 12 hours. The operation was performed in laparoscopic procedure. The pelvic retroperitoneum was opened bilaterally. Pelvic adhesion was progressively dissected until both ureters were identified and isolated to the level of uterine artery. After bilateral uterosacral ligament lesions were exposed and resected, the bowel was mobilized from 2 cm below the lesion to the level of inferior mesenteric artery. We performed segmental bowel resection only when a bowel lesion with maximum diameter more than 3 cm or infiltration depth at least 2 cm in bowel wall was detected. The bowel was transected along distal margin of lesion using an angled stapling device and the proximal end with lesion was extracted out of pelvic cavity through an incision in the posterior vaginal fornix. The whole involved bowel segment was resected along proximal margin of lesion. The end of bowel was fixed an anvil plate and then returned to pelvic cavity through the vaginal incision, which was sutured later. Finally, bowel anastomosis was performed by using a circular stapler under laparoscopy.

#### 3.4. Follow-Up

All patients received GnRH-a after operation for 6 months. The VAS, SF-36 questionnaire, and an investigation about fertility were administered to all patients at least 5 year after operation.

Median follow-up after operation was 76 months (62-105 months).

### 3.5. Statistical Analysis

Statistical analysis was performed with SPSS Version 22.0 (IBM SPSS Statistics, IBM, USA). Continuous variables were compared with Student's t-test and paired categorical variables were compared with Wilcoxon signed-rank test. P value <0.05 was considered statistically significant.

## 4. Results

### 4.1. Surgical Findings and Intra-Operative Complications

All of the patients underwent laparoscopic surgery except for one, who required conversion to laparotomy during laparoscopic surgery due to extensive pelvic adhesion and excessive bleeding. All of the patients were found to have severe adhesions in pelvic cavity. The mean operative duration was 312±97min, the length of bowel to be resected was 7.10±2.88cm.

Sixty cases (96.8%) had lesions located in the rectosigmoid region. The remaining 2 cases, one involved the ileocecum, and the other involved the colon descendens. In 6 cases, at least 2 bowel lesions were found. The majority of patients also presented involvement in other sites, including uterosacral ligament in 58 cases, vagina in 44 cases, ovary in 32 cases, ureter in 20 cases, adenomyosis in 19 cases, rectovaginal septum in 15 cases, peritoneum in 9 cases, bladder in 5 cases and vessel in 4 cases. All of the lesions we detected were resected.

Intra-operative complications occurred in 6 patients (9.7%). Rectum injury occurred in 2 patients and rectal anastomotic leakage occurred in 1 patient. These 3 patients received a secondary suture reinforcement in rectum. Bladder injury occurred in 2 patients who received suture reinforcement in bladder. The remaining one was who required conversion to laparotomy due to extensive adhesion and excessive bleeding.

### 4.2. Post-Operative Complications

Post-operative complications occurred in 29 patients (46.8%), including 18 cases of urinary retention (2 cases combined intra-operative bladder injury), 4 rectovaginal fistulas (1 case combined urinary retention), 2 cases of vaginal dehiscence, and 1 case each of thrombogenesis, diffuse peritonitis, peripheral nerve injury (complained of numbness in left lower limb), bacteraemia, incomplete intestinal obstruction and mucus bloody stool.

All patients with urinary retention had underwent excision of bilateral uterosacral ligament lesions which were more than 2 cm in diameter. These patients recovered well after indwelling catheter for 3 to 6 weeks. The 4 women who developed a rectovaginal fistula were diagnosed within 10 days after operation and then underwent double-lumen transverse colostomy, and the rectovaginal fistulas had healed after colonic stoma closure 3 months later. The 2 patients with vaginal dehiscence received vaginal irrigation for 10 consecutive days, one recovered well but the other one had to

underwent a secondary suture in fornix vaginae. The patient with thrombogenesis needed to take warfarin orally for 6 months. Patients with diffuse peritonitis and bacteraemia underwent anti-infective therapy. Patients with incomplete intestinal obstruction and mucus bloody stool received the basic therapy including fasting, gastrointestinal decompression, somatostatin and parenteral nutrition support. Patient with peripheral nerve injury took neurotrophic drugs. During the long-term follow-up, 7 patients had suffered from difficult defecation. Six patients showed indications of gradual recovery. The remaining one had to undergo scar removal by longitudinally section transverse suture from constrictive bowel segment.

### 4.3. Evolution of Symptoms and Quality of Life

All of the patients complained of endometriosis-linked pain and various intestinal symptoms before surgery, as summarized in Table 2.

All of the patients suffered from pain, including dysmenorrhea, dyspareunia, bowel movement pain, chronic pelvic pain and tenesmus. Dysmenorrhea was the most frequently reported (90.3%). Semi-quantitative data on pre- and post-operative pain symptom intensity was summarized in Table 3 and Figure 1. A significant relief in all pain symptoms was observed. Qualitative data on pre- and post-operative intestinal symptoms was summarized in Table 4. The clinical remission rate (disappeared and relieved) of dyschezia, rectal bleeding and diarrhoea was 78.6%, 80% and 75%, respectively, and no aggravation was observed for any intestinal symptom.

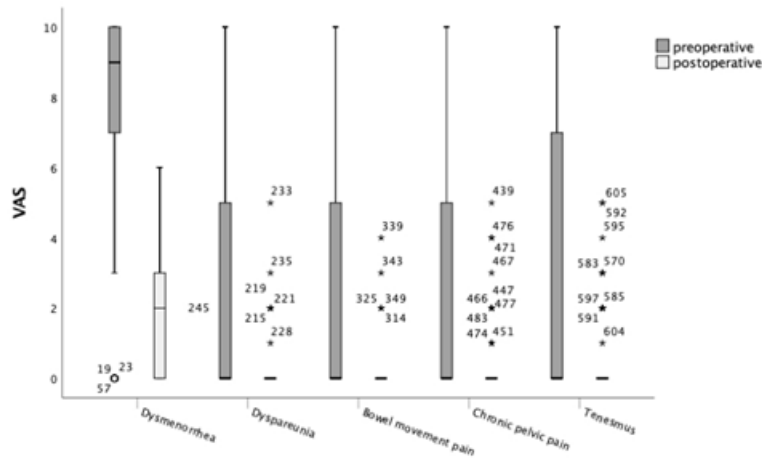
The improvement of post-operative quality of life was statistically significant (P<0.001) for all 8 domains of SF-36 questionnaire. The scores are shown in Figure 2. Compared with the standardized data for the Chinese female population 14, there was no statistically significant difference (P>0.05) in post-operative scores for the 8 domains of SF-36 questionnaire except for VT (Figure 3). But the post-operative score of VT was higher than standardized data for the Chinese female population.

According to the occurrence of post-operative complications, there was no statistically significant difference (P>0.05) in post-operative scores for all 8 domains of SF-36 questionnaire between patients with and without post-operative complications (Figure 4).

**Table 3:** Pre- and post-operative pain symptom intensity scores.

Symptom	Median preoperative intensity score (range)	Median post-operative intensity score (range)	P <sup>a</sup>
Dysmenorrhea	9(0-10)	2(0-6)	<0.001
Dyspareunia	0(0-10)	0(0-5)	<0.001
Bowel movement pain	0(0-10)	0(0-4)	<0.001
Chronic pelvic pain	0(0-10)	0(0-5)	<0.001
Tenesmus	0(0-10)	0(0-5)	<0.001

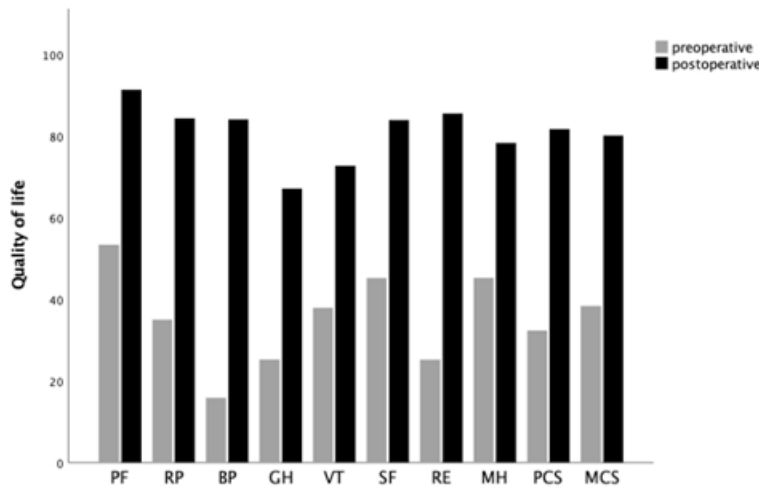
a: Wilcoxon signed-rank test



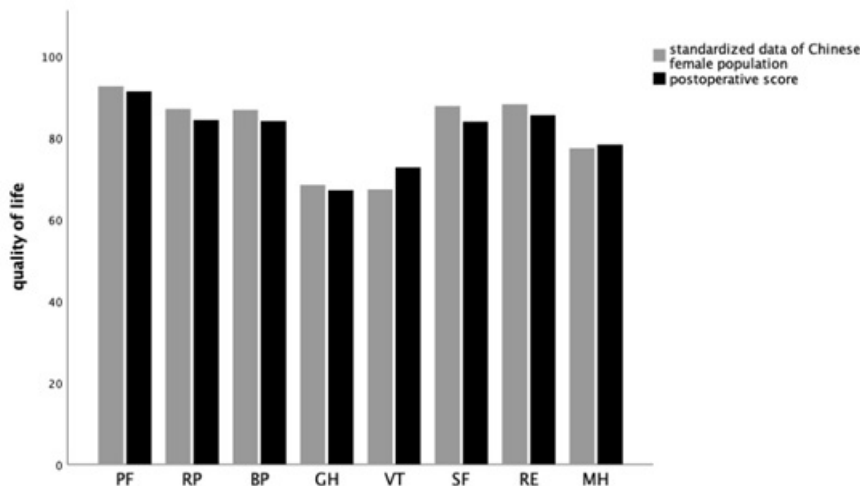
**Figure 1:** The box-plot of VAS scores for pain before and after surgery. An improvement in pain was observed; P values were <0.0001 for dysmenorrhea, dyspareunia, bowel movement pain, chronic pelvic pain and tenesmus, respectively.

**Table 4:** Pre- and post-operative intestinal symptoms.

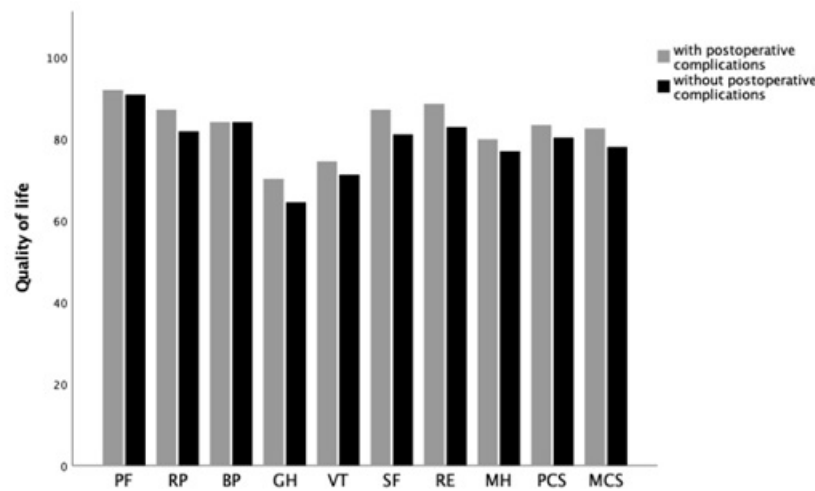
Symptom	Disappeared(%)	Relieved (%)	Same(%)	Aggravated (%)
Dyschezia	9/14(64.3%)	2/14(14.3%)	3/14(21.4%)	0/14(0%)
Rectal bleeding	9/15(60%)	3/15(20%)	3/15(20%)	0/15(0%)
Diarrhoea	4/16(25%)	8/16(50%)	4/16(25%)	0/16(0%)



**Figure 2:** Preoperative and postoperative scores of SF-36 questionnaire. All 8 domains showed significant improvement after surgery with P values <0.001.



**Figure 3:** Comparison between postoperative scores of SF-36 questionnaire for this study subjects and the standardized data of Chinese female population. There was no statistically significant difference with P values of 0.329, 0.164, 0.085, 0.528, 0.070, 0.308 and 0.556 for RP, BP, GH, SF, RE and MH, respectively. The only domain with statistically significant difference was VT with P=0.001.



**Figure 4:** The SF-36 questionnaire scores according to the presence of postoperative complications. There was no statistically significant difference with P values of 0.666, 0.176, 0.999, 0.166, 0.305, 0.151, 0.282, 0.343, 0.281 and 0.196 for RF, RP, BP, GH, VT, SF, RE, MH, PCS and MCS, respectively.

#### 4.4. Pregnancy after Surgery

There were 16 patients with infertility history before our treatment, 10 of whom had tried to conceive after surgery. Until our follow-up, 7 had become pregnant, including 2 cases of IVF-ET. Among the 7 pregnant cases, 2 had labour, 3 underwent caesarean sections, one had spontaneous abortion in the second trimester, and one underwent clear palace because missed abortion was found at 14 weeks.

#### 5. Discussion

In this study, we demonstrated the efficacy of segmental bowel resection for treating bowel endometriosis. This procedure provided obvious relief of pain and intestinal symptoms and significant improvement in quality of life.

Bowel endometriosis can be located in any part, mainly in rectosigmoid region, followed by ileocecum, appendix and caecum [2-5]. When the rectosigmoid region is involved, the most common intestinal symptoms are bowel movement pain and periodic tenesmus. This study found 60 cases of rectosigmoid region involvement. Of the remaining 2 cases of non-rectosigmoid involvement, one involved the ileocecum, a 4 cm×3 cm lesion had made the involved bowel segment rigid and constrictive; the other involved the colon descendens and presented 3 lesions at least 3 cm in size. Amazingly, despite such poor intestinal environments, the 2 non-rectosigmoid region involved patients had few intestinal symptoms. Intestinal symptoms may be related to the site of involvement. In our study, we did not find any lesions in the upper gastrointestinal tract. For patients with bowel endometriosis, less than 10% of cases are outside of the pelvic cavity [15]. In fact, not all patients with bowel endometriosis complain of intestinal symptoms; in this study, 12 patients had none. But all 62 patients complained of severe pain and sought treatment for pain. Therefore, the greatest discomfort resulting from bowel endometriosis is

pain. Previous studies about pain showed VAS scores of 8-9, 5-6, 1-8 and 2-6 for dysmenorrhea, dyspareunia, bowel movement pain and chronic pelvic pain [16-18], respectively, consistent with our study. Additionally, the mean scores for the 8 domains of the SF-36 questionnaire were quite low in this study, and BP had the lowest mean score (15.9). Our data implied that patients' quality of life were affected seriously, especially in terms of pain. Therefore, our treatment mainly aimed to relieve pain and improve quality of life.

As mentioned, medical treatments may be the first-line for DIE patients. Although several medical treatments can be efficacy, high rate of symptoms recur after withdrawal should be noted. Thus, these medicines may be used for prolonged periods of time, even years [19-23]. When bowel endometriosis seriously impacts quality of life, surgical resection is the preferred treatment [19]. Regarding the previous treatment of the patients in our study, 17 patients had received previous medical treatment for endometriosis with recurrence after withdrawal. On the other hand, 20 patients had undergone previous surgical treatment for endometriosis; however, only one involved the bowel, and it was just a simple biopsy for intestinal lesion. If entire lesions were not radically resected, patients may be at high risk of requiring re-operation. There are three options for surgical treatment: shaving, disc resection and segmental bowel resection [11]. Redwine and Sharpe firstly reported a case of laparoscopic segmental resection of the sigmoid colon as a treatment for bowel endometriosis [24]. Fedele have shown that the risk of clinical recurrence requiring further treatment was significantly higher in women who did not undergo colorectal resection when this region was involved widely [25]. Our indications of the surgical routes are as follows: 1. Shaving: lesions in the superficial seromuscular layer and less than 1 cm in size. 2. Disc resection: lesions invading the deep layer and no more than 2 cm in size that involve no more than 1/3 of the circumfer-

ence of the whole bowel wall. 3. Segmental bowel resection: huge masses more than 3 cm in size or involving more than 1/3 of the circumference of the bowel wall or infiltration depth at least 2 cm in bowel wall.

This study has demonstrated that segmental bowel resection for bowel endometriosis is associated with an obvious relief of pain and intestinal symptoms and a significant improvement in quality of life. The later combined GnRH-a treatment aimed at enhancing the efficacy of operation. Many previous studies have shown same result with us [26-29]. A prospective study by Bassi et al. analysed the quality of life 1 year after surgery for 151 patients who underwent laparoscopic segmental bowel resection for bowel endometriosis. They also showed significant improvement in all 8 domains of SF-36 questionnaire. But this study did not evaluate the impact of complications [17]. In addition, we cited the standardized data for the Chinese female population from Rui et al. [14]. Who examined 3124 SF-36 questionnaires from healthy population in Beijing, Shanghai, Guangzhou, Xian and Wuhan, the biggest cities in the north, east, south, west and centre of China, respectively. We found no significant difference between the post-operative scores of patients and the standardized data for Chinese female population except for VT, but the post-operative score of VT was the higher. This comparison indicated that bowel resection surgery can improve patients' quality of life to the level of the healthy population. A similar result has been found for the quality of life between the healthy population and patients who underwent segmental bowel resection of a much larger operative area to treat malignant tumour [30].

Although segmental bowel resection can achieve a satisfactory curative effect, this surgical route remains quite controversial because of the risk of complications [31-33]. There is still no consensus regarding the choice between radical (segmental resection) or conservative (shaving and disc resection) surgical management for bowel endometriosis, and different standards are applied in different centres. Some studies summarized their surgical procedure by indicating that there may be no difference in risk between disc resection and segmental bowel resection. Radical technique usually has a positive impact on clinical improvement of gynaecological and intestinal symptoms in patients with bowel involvement, but it requires high-tech comprehensive skill and surgical skill has a greater impact on risk than the surgical approach does [34-36]. The complication rate of segmental bowel resection for bowel endometriosis is estimated to be 10-22% [37,38]. Because of benign change, we resected the lesions just along the margins. No report indicates a better curative effect as a result of extending the bowel to be resected. Mabrouk et al. indicated that the presence of satellite lesions or even positive resection margins did not seem to influence the clinical outcomes of segmental colorectal resection [18]. In addition, Abrão et al. [29]. Summarized three frequently observed risk factors to be noted during operation [39]: 1. Keeping

the vaginal cleft open during the bowel surgical procedure may increase the risk of infection. 2. Excessive use of electrocoagulation can lead to over necrosis of the incisal edge of the posterior vaginal fornix, increasing the risk of rectovaginal fistulae and abscesses. 3. Surgical resection of low rectal lesions may increase the risk of anastomotic leaks. The overall rate of post-operative complications in our study was 46.8%. Although higher than those reported in previous studies, just a few severe complications occurred. Four cases (6.5%) of rectovaginal fistula were detected. These 4 patients underwent double-lumen transverse colostomy, and the fistulas healed after 3 months. Among all cases of post-operative complications, nearly two-thirds were urinary retention. All of these patients underwent excision of bilateral uterosacral ligament lesions larger than 2 cm and recovered well after indwelling catheter for 3 to 6 weeks. Deep infiltrating endometriosis in the bilateral uterosacral ligament may be a risk factor for post-operative urinary retention. Li et al. investigated bladder function after excision of uterosacral or rectovaginal endometriosis from 252 patients. The study found no definitive association between the depth of endometriosis excision and urinary dysfunction and indicated that urinary dysfunction may be explained by lesion itself that cause damage to the hypogastric plexus [40]. Furthermore, no difference in quality of life was observed between the women with post-operative complications and those without. The complications may have no impact on the improvement of quality of life.

It is well known that endometriosis is associated with infertility. The infertility rate associated with endometriosis is 23-66%, of which 90% were primary [27,28,41,42]. But no study has indicated a higher pregnancy rate among patients who have undergone operation [43]. A systematic review conducted to assess the impact of colorectal surgery on the fertility of patients with DIE, has found a spontaneous pregnancy rate of 40-60% [41]. For asymptomatic bowel endometriosis patients with infertility, ART may be preferred, and bowel surgery may be necessary if IVF fails twice or more [44]. If surgery is needed, laparoscopy would achieve a better curative effect and pregnancy rate than laparotomy [45]. Although surgical interventions may have had an impact on fertility, the presence of lesions and severe pelvic adhesions may have a greater influence. In addition, according to the study by de Ziegler et al. [44] 3-6 periods of GnRH-a treatment may increase the post-operative pregnancy rate. So as we did. In conclusion, bowel endometriosis can result in severe pain and intestinal symptoms that affect the quality of life remarkably. Surgical resection is the preferred treatment for severe symptomatic patients. This single-centre series demonstrates that segmental bowel resection is a feasible technique and can provide obvious relief of symptoms and increases long-term quality of life to the level of the healthy population. The relatively high rate of complications must be noted, but may have little impact to the improvement in quality of life. This surgical procedure is safe but complex, requiring high-tech

comprehensive skills in laparoscopic gynaecology, urology and colorectal surgery. Our further studies will evaluate the safety and efficiency of other surgical routes for bowel endometriosis, comparing with segmental bowel resection to establish an optimized route for bowel endometriosis by means of randomized controlled trials.

## References

- Clement PB. Pathology of endometriosis. *Pathol Annu.* 1990; 25 Pt 1: 245-295.
- Chapron C, Fauconnier A, Vieira M. Anatomical distribution of deeply infiltrating endometriosis: surgical implications and proposition for a classification. *Hum Reprod.* 2003; 18(1): 157-161.
- Houtmeyers P, Ceelen W, Gillardin JM, Dhondt M, Pattyn P. Surgery for gastrointestinal endometriosis: indications and results. *Acta Chir Belg.* 2006; 106(4): 413-416.
- Beltran MA, Tapia QT, Araos HF, Martinez GH, Cruces KS. Ileal endometriosis as a cause of intestinal obstruction. Report of two cases. *Rev Med Chil.* 2006; 134(4): 485-490.
- Jatan AK, Solomon MJ, Young J, Cooper M, Pathma-Nathan N. Laparoscopic management of rectal endometriosis. *Dis Colon Rectum.* 2006; 49(2):169-174.
- Fritzer N, Tammaa A, Salzer H, Hudelist G. Dyspareunia and quality of sex life after surgical excision of endometriosis: a systematic review. *Eur J Obstet Gynecol Reprod Biol.* 2014; 173: 1-6.
- Soumekh A, Nagler J. Gastrointestinal endometriosis causing subacute intestinal obstruction with gradual development of weight loss and misdiagnosed as irritable bowel syndrome. *Case Rep Gastroenterol.* 2014; 8(1): 51-55.
- Thomassin I, Bazot M, Detchev R, Barranger E, Cortez A, Darai E. Symptoms before and after surgical removal of colorectal endometriosis that are assessed by magnetic resonance imaging and rectal endoscopic sonography. *Am J Obstet Gynecol.* 2004; 190(5): 1264-1271.
- Darai E, Thomassin I, Barranger E. Feasibility and clinical outcome of laparoscopic colorectal resection for endometriosis. *Am J Obstet Gynecol.* 2005; 192(2): 394-400.
- Donnez J, Squifflet J. Complications, pregnancy and recurrence in a prospective series of 500 patients operated on by the shaving technique for deep rectovaginal endometriotic nodules. *Hum Reprod.* 2010; 25(8): 1949-1958.
- Donnez O, Roman H. Choosing the right surgical technique for deep endometriosis: shaving, disc excision, or bowel resection? *Fertil Steril.* 2017; 108(6): 931-942.
- Mabrouk M, Raimondo D, Altieri M. Surgical, Clinical, and Functional Outcomes in Patients with Rectosigmoid Endometriosis in the Gray Zone: 13-Year Long-Term Follow-up. *J Minim Invasive Gynecol.* 2018.
- Ware JE, Jr Gandek B. Overview of the SF-36 Health Survey and the International Quality of Life Assessment (IQOLA) Project. *J Clin Epidemiol.* 1998; 51(11): 903-912.
- Rui W, Cheng W, Ma XQ, Zhao YF, Yan XY, Jia H. Health-related quality of life in Chinese people: a population-based survey of five cities in China. *Scand J Public Health.* 2011; 39(4): 410-418.
- Ha JK, Choi CW, Kim HW. An extremely rare case of gastric sub-epithelial tumor: gastric endometriosis. *Clin Endosc.* 2015; 48(1): 74-77.
- Dubernard G, Piketty M, Rouzier R, Houry S, Bazot M, Darai E. Quality of life after laparoscopic colorectal resection for endometriosis. *Hum Reprod.* 2006; 21(5): 1243-1247.
- Bassi MA, Podgaec S, Dias JA, Jr D'Amico Filho N, Petta CA, et al. Quality of life after segmental resection of the rectosigmoid by laparoscopy in patients with deep infiltrating endometriosis with bowel involvement. *J Minim Invasive Gynecol.* 2011; 18(6): 730-733.
- Mabrouk M, Spagnolo E, Raimondo D. Segmental bowel resection for colorectal endometriosis: is there a correlation between histological pattern and clinical outcomes? *Hum Reprod.* 2012; 27(5): 1314-1319.
- Singh SS, Suen MW. Surgery for endometriosis: beyond medical therapies. *Fertil Steril.* 2017; 107(3): 549-554.
- Casper RF. Progestin-only pills may be a better first-line treatment for endometriosis than combined estrogen-progestin contraceptive pills. *Fertil Steril.* 2017; 107(3): 533-536.
- Jensen JT, Schlaff W, Gordon K. Use of combined hormonal contraceptives for the treatment of endometriosis-related pain: a systematic review of the evidence. *Fertil Steril.* 2018; 110(1): 137-152 e131.
- Vercellini P, Buggio L, Frattaruolo MP, Borghi A, Drudi D, Somigliana E. Medical treatment of endometriosis-related pain. *Best Pract Res Clin Obstet Gynaecol.* 2018; 51: 68-91.
- Grandi G, Barra F, Ferrero S. Hormonal contraception in women with endometriosis: a systematic review. *Eur J Contracept Reprod Health Care.* 2019; 24(1): 61-70.
- Redwine DB, Sharpe DR. Laparoscopic segmental resection of the sigmoid colon for endometriosis. *J Laparoendosc Surg.* 1991; 1(4): 217-220.
- Fedele L, Bianchi S, Zanconato G, Bettoni G, Gotsch F. Long-term follow-up after conservative surgery for rectovaginal endometriosis. *Am J Obstet Gynecol.* 2004; 190(4): 1020-1024.
- Dubernard G, Rouzier R, David-Montefiore E, Bazot M, Darai E. Use of the SF-36 questionnaire to predict quality-of-life improvement after laparoscopic colorectal resection for endometriosis. *Hum Reprod.* 2008; 23(4): 846-851.
- Kavallaris A, Chalvatzas N, Hornemann A, Banz C, Diedrich K, Agic A. 94 months follow-up after laparoscopic assisted vaginal resection of septum rectovaginale and rectosigmoid in women with deep infiltrating endometriosis. *Arch Gynecol Obstet.* 2011; 283(5): 1059-1064.
- Fleisch MC, Hepp P, Kaleta T. Feasibility and first long-term results after laparoscopic rectal segment resection and vaginal specimen retrieval for deep infiltrating endometriosis. *Arch Gynecol Obstet.* 2014; 289(6): 1241-1247.

29. Mangler M, Herbstleb J, Mechsner S, Bartley J, Schneider A, Kohler C. Long-term follow-up and recurrence rate after mesorectum-sparing bowel resection among women with rectovaginal endometriosis. *Int J Gynaecol Obstet.* 2014; 125(3): 266-269.
30. Lai X, Wong FK, Ching SS. Review of bowel dysfunction of rectal cancer patients during the first five years after sphincter-preserving surgery: a population in need of nursing attention. *Eur J Oncol Nurs.* 2013; 17(5): 681-692.
31. Minelli L, Fanfani F, Fagotti A. Laparoscopic colorectal resection for bowel endometriosis: feasibility, complications, and clinical outcome. *Arch Surg.* 2009; 144(3): 234-239.
32. Van den Broeck U, Meuleman C, Tomassetti C. Effect of laparoscopic surgery for moderate and severe endometriosis on depression, relationship satisfaction and sexual functioning: comparison of patients with and without bowel resection. *Hum Reprod.* 2013; 28(9): 2389-2397.
33. Roman H, Bubenheim M, Huet E. Conservative surgery versus colorectal resection in deep endometriosis infiltrating the rectum: a randomized trial. *Hum Reprod.* 2018; 33(1): 47-57.
34. Brouwer R, Woods RJ. Rectal endometriosis: results of radical excision and review of published work. *ANZ J Surg.* 2007; 77(7): 562-571.
35. Malzoni M, Di Giovanni A, Exacoustos C. Feasibility and Safety of Laparoscopic-Assisted Bowel Segmental Resection for Deep Infiltrating Endometriosis: A Retrospective Cohort Study With Description of Technique. *J Minim Invasive Gynecol.* 2016; 23(4): 512-525.
36. Rocha AM, Albuquerque MM, Schmidt EM, Freitas CD, Farias JP, Bedin F. Late Impact of the Laparoscopic Treatment of Deep Infiltrating Endometriosis with Segmental Colorectal Resection. *Arq Bras Cir Dig.* 2018; 31(4): e1406.
37. Kondo W, Bourdel N, Tamburro S. Complications after surgery for deeply infiltrating pelvic endometriosis. *BJOG.* 2011; 118(3): 292-298.
38. Bouaziz J, Soriano D. Complications of colorectal resection for endometriosis. *Minerva Ginecol.* 2017; 69(5): 477-487.
39. Abrao MS, Petraglia F, Falcone T, Keckstein J, Osuga Y, Chapron C. Deep endometriosis infiltrating the recto-sigmoid: critical factors to consider before management. *Hum Reprod Update.* 2015; 21(3): 329-339.
40. Li YH, De Vries B, Cooper M, Krishnan S. Bowel and bladder function after resection of deeply infiltrating endometriosis. *Aust N Z J Obstet Gynaecol.* 2014; 54(3): 218-224.
41. Iversen ML, Seyer-Hansen M, Forman A. Does surgery for deep infiltrating bowel endometriosis improve fertility? A systematic review. *Acta Obstet Gynecol Scand.* 2017; 96(6): 688-693.
42. Darai E, Marpeau O, Thomassin I, Dubernard G, Barranger E, Bazot M. Fertility after laparoscopic colorectal resection for endometriosis: preliminary results. *Fertil Steril.* 2005; 84(4): 945-950.
43. Chapron C, Pietin-Vialle C, Borghese B, Davy C, Foulot H, Chopin N. Associated ovarian endometrioma is a marker for greater severity of deeply infiltrating endometriosis. *Fertil Steril.* 2009; 92(2): 453-457.
44. de Ziegler D, Borghese B, Chapron C. Endometriosis and infertility: pathophysiology and management. *Lancet.* 2010; 376(9742): 730-738.
45. Meuleman C, Tomassetti C, Wolthuis A. Clinical outcome after radical excision of moderate-severe endometriosis with or without bowel resection and reanastomosis: a prospective cohort study. *Ann Surg.* 2014; 259(3): 522-531.