

Review of Diagnostic Procedures and Progress in the Management of Acute Cholecystitis

Ntsobe T^{1,a}, Wei P^{1,a}, Haijin L^{*2,a,b}, Feng C^{2,a}, Haijin H^{2,a}, Martial EFC^{3,a} and Kuete M^{3,c}

^aPediatric Surgery, First Affiliated Hospital of Gannan Medical College, Jiangxi province, Ganzhou city, China

^bPediatric Surgery, China Medical University, China

^cANHUI Biochem United Pharmaceutical Research Institute, School of Chemistry and Materials Science, University of Science and Technology of China, ANHUI, China

*Corresponding author:

Haijin,
Department of Pediatric Surgery, China Medical University, China, Tel: 008613979738718;
BO: 341000; E-Mail: liuhaji@163.com

Received: 07 Jan 2022

Accepted: 21 Jan 2022

Published: 28 Jan 2022

J Short Name: COS

Copyright:

©2022 Ntsobe T. This is an open access article distributed under the terms of the Creative Commons Attribution License, which permits unrestricted use, distribution, and build upon your work non-commercially.

Citation:

Ntsobe T. et al. Review of Diagnostic Procedures and Progress in the Management of Acute Cholecystitis. Clin Surg. 2022; 6(15): 1-8

Keywords:

Acute cholecystitis; Cholecystectomy; Murphy's sign

1. Abstract

1.1. Background: This review will be a contribution for decision making and adequate management of Acute Cholecystitis.

1.2. Patients and Methods: We retrieved studies from PubMed, Wiley of science and Science direct.

1.3. Results: Many authors have agreed to diagnostic methods that include clinical findings, radiologic and laboratory outcomes. Early laparoscopic cholecystectomy is the best treatment for Grade I and Grade II patients of the Tokyo Guideline 2018. For many decades, the treatment protocol has been controversial for patients presenting severe cholecystitis (Grade III AC) and those unfit for surgery because of co morbidities. Recent authors advocated for early laparoscopic cholecystectomy for Grade III patients. Delayed laparoscopic cholecystectomy is recommended for patients who missed the golden 72 hours and presenting high risk of intra operative complications. Cholecystostomy is described by many scholars as alternative treatment for patients presenting comorbidities. Nowadays, Endoscopic trans papillary or transmural and ultrasound-assisted cholecystostomy are the new techniques of cholecystostomy.

1.4. Conclusion: Diagnostic assessment of Acute cholecystitis include clinic and Para clinic. Early laparoscopic cholecystectomy within 72 hours is the first choice or treatment for Grade III patients. Delayed cholecystectomy is indicated for those presenting high risk of intra-operative complications if surgery is done early. Cholecystostomy is indicated for patients presenting with comorbidities and is an alternative treatment for those unfit for surgery. Nowadays, endoscopic and ultrasound-assisted drainages are the new techniques of cholecystostomy.

2. Introduction

Acute Cholecystitis (AC) is commonly due to gallstone obstruction at the level of cystic duct. Gallbladder contraction against this persistent obstacle leads to local inflammation and edema. In this case it is acute calculus cholecystitis (ACC) as a result of gallstone effects and represents 85-90% of total cases of cholecystitis compared to acalculous cholecystitis (AAC) 5-15% [1, 2]. AAC represents 50-70% of cholecystitis in children; it is caused by infection and constitutes the less common version of cholecystitis that occurs usually in critically ill patients [3-5]. Risk factors are generalized sepsis, major trauma, low output after cardiac operations, severe burns, long term protraction and parenteral feeding [6, 7]. Specific guidelines for pediatric cholecystitis are not available and clinical studies are necessary to establish the most appropriate management of AC in children. Many tools are used to assess diagnosis of AC and Laparoscopic Cholecystectomy (LC) is described as the best choice of treatment by current authors [8-10]. Several guidelines are used to manage AC in adult patients. The current commonly used in practice are the TG18 for diagnostic criteria and severity grading scale [11], the World Society of Emergency Surgery (WSES) guideline 2020 [12], the Parkland Grading Scale (PGS) and the American Association for Surgery of Trauma - Emergency General Surgery (AAST EGS) [1]. This review will be a tool for decision making and a contribution for a worldwide consensus about AC management.

3. Patients and Methods

We retrieved studies that aim to describe diagnostic or Management of AC from PubMed, Wiley of science and Science direct. We used different items such as Acute Cholecystitis "OR" Severe cholecystitis, Cholecystectomy "AND/OR" Cholecystostomy.

This research has been conducted as recommended by the Declaration of Helsinki in 1995. No consent with patients, nor ethical committee approval have been obtained as there was no human intervention.

4. Results

4.1. Pathogenesis and Clinical Signs

Cholesterol gallstones account for 80%90% of calculi analyzed after cholecystectomy in European and American populations [13]. Then, Biliary calculi genesis is directly linked to lifestyle and food intake. Almost 80% of calculi remain asymptomatic. The presence of calculi into the gallbladder will provoke cystic duct obstruction and gallbladder enlargement. This obstruction leads to inflammation, infection, ischemia, necrosis or perforation [14]. This inflammation can progress to empyema, gangrenous or emphysema [15, 16]. Some patients will present isolated biliary colic. Other morbid signs can be fever more than 38,5 degrees Celsius, vomiting, severe asthenia, jaundice, Right Upper Abdominal Quadrant (RUAQ) pain/tenderness/mass with positive Murphy’s sign [17, 18].

4. 2. Diagnostic Procedures

AC is a common differential diagnosis for patients presenting to the Emergency Department (ED) with abdominal pain [18-20]. In a systematic review conducted from 1965 to 2016 [17], Ashika J et al. revealed that the prevalence of AC in ED was 14.9%. Within 1990 patients received in ED, 297 have been diagnosed for AC. He suggested to consider parameters such as history of the disease, physical examination, laboratory data and ultrasound imaging to achieve diagnosis of AC. Eskelinen M et al. [21] conducted a cohort of 1333 patients and aimed to compare common clinical

signs, biological results and diagnostic score of AC. He concluded that, for clinical diagnosis of AC, the diagnostic score should be considered as an integral part of diagnostic algorithm. In 2018, the TG13 has been reviewed by Yokoe et al. [11] and diagnostic criteria (Table 1) with new recommendations for imaging investigations have been adopted:

- **Recommendation 1, level C:** Abdominal Ultrasound (US) is recommended as the best choice of imaging to diagnose AC. It is less invasive, available, easily to use with low cost and preferred prior to CT scan and Magnetic Resonance Imaging (MRI).
- **Recommendation 2, level B:** MRI/MRCP (Magnetic resonance cholangiopancreatography) should be assessed to diagnose AC if abdominal US does not provide a definitive diagnosis.
- **Recommendation 3, level C:** Contrast CT scan or contrast MRI are recommended when gangrenous cholecystitis is suspected.

The TG13/TG18 classified AC on 3 grades based to clinical signs and laboratory outcomes (Table 2). This classification is the most simplified and the most used by current authors. Grade I is considered as the mild AC without generalized signs of inflammation. Grade II is the moderate AC with elevated White Blood Cells (WBC) and C-Reactive Protein (CRP). Grade III is the severe grade and considered as Grade II associated with organs dysfunction; it may cause general signs and is life-threatening because of organ damage. The TG18 diagnostic criteria are recommended to be used as the TG13 and constitute a useful indicator for vital prognosis prediction [11, 22].

Table 1: TG13/18 diagnostic criteria of AC

a. Local signs of inflammation.
<ul style="list-style-type: none"> • Murphy’s sign • RUQ mass/pain/tenderness
b. Systemic signs of inflammation.
<ul style="list-style-type: none"> • Fever; • elevated CRP; • elevated WBC count
c. Imaging findings: Imaging findings characteristic of AC
Suspected diagnosis: one item in a + one item in b
Definitive diagnosis: one item in a + one item in b + c

Management of Acute Cholecystitis

Cited from Yokoe et al. (11): The TG13/18 diagnostic criteria of AC;

CRP: C-reactive protein, RUQ: right upper abdominal quadrant, WBC: white blood cell

Table 2: TG18/TG13 severity grading scale of AC

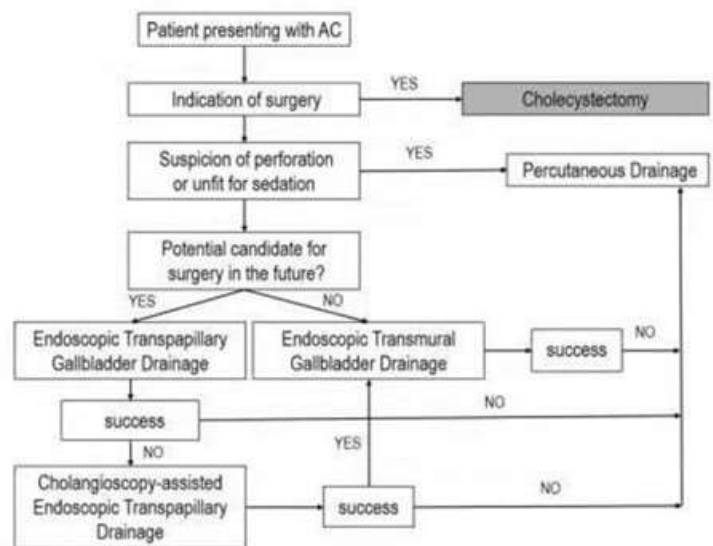
<p>Grade III or severe AC is associated to anyone of the following organs/systems dysfunction:</p> <ul style="list-style-type: none"> • Cardiovascular dysfunction: hypotension requiring treatment with dopamine ≥ 5 microgram/kg per min, or any dose of nor epinephrine • Neurological dysfunction: decreased level of consciousness • Respiratory dysfunction: $\text{PaO}_2/\text{FiO}_2$ ratio < 300 • Renal dysfunction: oliguria, creatinine > 2.0 mg/dl • Hepatic dysfunction: PT-INR > 1.5 • Hematological dysfunction: platelet count $< 100,000/\text{mm}^3$
<p>Grade II or moderate AC is associated with anyone of the following conditions:</p> <ul style="list-style-type: none"> • Elevated WBC count ($> 18,000/\text{mm}^3$) • Palpable tender mass in the right upper abdominal quadrant • Duration of complaints > 72 h • Marked local inflammation (gangrenous cholecystitis, pericholecystic abscess, hepatic abscess, biliary peritonitis, emphysematous cholecystitis)
<p>Grade I or mild AC does not meet the criteria of Grade III or Grade II. It can also be defined as AC in a healthy patient with no organ dysfunction and mild inflammatory changes in the gallbladder, making cholecystectomy a safe and low-risk operative procedure.</p>

Cited from Yokoe et al. (11): the TG13 /18 severity grading scale of acute cholecystitis.

4.3. Modalities of Management

4.3.1. Conservative treatment and management of co morbidities

Conservative treatment has been practiced either with medical treatment only or associated to cholecystostomy in patients at risk for surgery because of co morbidities. Medical management includes intravenous hydration, analgesics, antibiotics and restriction of oral feeding [23, 24]. It has since been the first choice of treatment for acalculous or non-obstructive cholecystitis in critically ill patients. Many publications reported a high rate of treatment failure requiring cholecystostomy or surgery in patients who was treated only with medication [25-27]. Cholecystostomy has initially been performed by percutaneous access and direct puncture at the right upper abdominal quadrant [28-30]. In 1984, Kozarek [31] reported that the gallbladder can be drained endoscopically by selective cannulation of the cystic duct in 74% of patients. He called this method Endoscopic Retrograde Cholecysto Pancreatography (ERCP). ERCP allows good visualization of the gallbladder cavity, easy retrieval of bile for biological analysis and possibility of dissolution or extraction of calculi. Since Kozarek's description, endoscopic drainage of the gallbladder knew great advances. Nowadays, this drainage can be done either by placement of transpapillary stent (ETPGBD), nasobiliary drain or Ultrasound-assisted drainage (EUSGBD) [32-34]. This endoscopic-assisted drainage is safe for patients with liver insufficiency (cirrhosis) or with contraindications for percutaneous drainage because of coagulopathy [35]. Due to the lack of comparative studies, nasobiliary drainage is less practiced compared to ETPGBD. In a recent review, Sobani ZA et al. proposed an algorithm for management of AC in patients unfit for surgery (Figure 1) [35]. In this algorithm, PC is indicated as the first option in case of gallbladder perforation or for patients unfit for sedation. He suggested to perform PC in case endoscopic drainage is not efficient.



Cited from Sobani ZA et al. (35) Sobani ZA, Ling C, Rustagi T. Endoscopic Transpapillary Gallbladder Drainage Acute Cholecystitis. *Dig Dis Sci*. 2021 May;66(5):1425-1435. doi: 10.1007/s10620-020-06422-z. Epub 2020 Jun 25. PMID: 32588249.

Figure 1: Algorithm for management of AC in patients unfit for surgery.

4.3.2. Surgical Management

With great advances in minimally invasive surgery, LC is preferred prior to open surgery. LC has shown good results such as early recovery and short length of hospital stay for Grade I and Grade II of the TG18 when surgery is performed early [36-38]. But for Grade III patients, many authors reported a high conversion to open surgery and intra operative difficulties when LC is performed early [39-41]. Risk factors of conversion to open surgery have been reported in the previous literature. Out of patient's obesity, elder age, most frequent are: adhesive tissue of calot's triangle, common bile duct adhesion to the gallbladder, gangrenous and bile duct injury [42-44]. Recent guidelines suggested Parkland grading scale for management of AC (Table 3) and AAST EGS (Table 4) completed Parkland grading scale considering co morbidities in patients at risk for surgery [1]. Parkland classified AC in 5 grades

according to the severity of signs and proposed treatment for each grade. This classification was based to the degree of inflammation and intra operative difficulties. Grade 5 has been considered as the most severe with perforated gallbladder, necrosis and bad visualization during operation due to adhesive tissues. Most of times such patients have prolong operating time and are at high risk of post-operative complications. The AAST EGS classified also AC in 5 grades and proposed appropriated management for each grade.

It considered laparoscopic description of the gallbladder and the severity of inflammation of surrounding tissues that can go from localized inflammation to generalized peritonitis (Grade V). Grade I and II are at low risk of conversion to open surgery and managed with laparoscopy. Co morbidities are considered in Grade III and PC is recommended as alternative of surgery. Grade IV and V are respectively the most severe with high risk of conversion to open surgery because of gallstone ileus (grade IV) or generalized peritonitis (grade V).

Table 3: Parkland grading scale of AC.

Cholecystitis Severity Grade	Description of Severity	Management
1	Normal appearing gallbladder (“robin’s egg blue”) No adhesions present Completely normal gallbladder.	Typical acute or acute on chronic cholecystitis Laparoscopic Cholecystectomy feasible Relatively low operating room time, bile leakage rate length of stay, and conversion rate
2	Minor adhesions at neck. otherwise, normal gallbladder Adhesions restricted to the neck or lower of the gallbladder.	Typical acute or acute on chronic cholecystitis Laparoscopic Cholecystectomy feasible. Relatively low operating room time bile leakage rate and conversion rate
3	Presence of ANY of the following Hyperemia, pericholecystic fluid adhesions to the body, distended gallbladder.	Higher risk of operative difficulties compared to grades 1 and 2. Laparoscopic cholecystectomy feasible but impact on operative time and complications not predictable
4	Presence of ANY of the following: Adhesions obscuring majority of gallbladder Grade I-III with abnormal liver anatomy, intrahepatic gallbladder or impacted stone (Mirizzi).	Higher risk of operative difficulties compared to grades 1 and 2. Laparoscopic cholecystectomy feasibility is unclear and impact on operative time and complications not predictable.
5	Presence of ANY of the following: Perforation, necrosis, inability to visualize the gallbladder due to adhesions.	High risk for longer operative time increased operative difficulty and increased postoperative complication rates compared to lower grades. Gangrenous cholecystitis likely surgery High concern for conversion to open.

Table 4: AAST EGS grade descriptions of acute cholecystitis severity.

Grade	Description	Imaging	Operative	Management
Grade I	Localized gallbladder inflammation	Wall thickening pericholecystic fluid, non-visualization of the gallbladder	Localized inflammatory changes	Laparoscopic cholecystectomy with low risk of conversion to open.
Grade II	Distended gallbladder with purulence or hydrops, necrosis/gangrene of wall noted without iatrogenic perforation	Above plus air in the gallbladder lumen, wall or biliary tree	Distended gallbladder with pus/hydrops, non-perforated wall necrosis/gangrene	Laparoscopic cholecystectomy with low risk of conversion to open.
Grade III	Non iatrogenic perforation with bile located to RUQ	Extraluminal fluid collection limited to RUQ	Non iatrogenic gallbladder wall perforation with bile limited to RUQ	Laparoscopic cholecystectomy with risk of conversion to open. Consider percutaneous, cholecystostomy, if severe co morbidities
Grade IV	Pericholecystic abscess, bilioenteric fistula, gallstone ileus	RUQ abscess, bilioenteric fistula, gallstone ileus	Pericholecystic abscess, bilioenteric fistula, gallstone ileus	Laparoscopic cholecystectomy with high probability of conversion to open. Consider open cholecystectomy initially. Consider percutaneous cholecystostomy if severe co morbidities.

Grade V	Grade IV disease but with generalized peritonitis	Free intra peritoneal fluid	Above with generalized peritonitis	Laparoscopic cholecystectomy with high probability of conversion to open. Consider open cholecystectomy initially. Consider percutaneous cholecystostomy if severe comorbidities.
----------------	---	-----------------------------	------------------------------------	---

Cited from A. Elkbuli, C. et al. (1): Current grading of gall bladder cholecystitis and management guidelines: Is it sufficient? *Ann Med Surg (Lond)*. 2020 Oct 28; 60:304-307. doi: 10.1016/j.amsu.2020.10.062. PMID: 33204421; PMCID: PMC7649581

5. Discussion

In 2013, the Tokyo Guideline (TG13) [22] had set diagnostic criteria that have been adopted in 2018 during the revision process of this guideline. Despite the TG13/18 has been validated by

the scientific committee, Dacey M et al. [45] conducted 3 years prospective study based on 857 patients with suspected AC that limited the TG13/18 diagnostic criteria. Among severe cases including gangrenous cholecystitis, 45% did not present the TG13/18 diagnostic criteria. In this study, the TG13/18 sensitivity was only 53%. This low sensitivity has been explained by the fact that many patients with AC didn't express fever or elevated WBC in early stage. The most recurrent sign of AC in this study was right upper quadrant pain and Murphy's sign. The TG13 recommended initially DLC after PC and antibiotics treatment for Grade III AC. But this approach has been limited by certain studies (46-48). With a Propensity Score Analysis, some researchers from TEXAS compared grade III AC patients who received PC to those who did not [46]. This study revealed that, PC group had higher mortality rate after 30, 90 days and 2 years following intervention. The readmission rate was high and the probability to undergo cholecystectomy within 2 years in elder patients was low. So, these authors suggested an eventual modification of the TG13. In 2018, the TG13 has been updated and ELC recommended for grade III AC [49].

The time frame for surgical intervention has been also discussed in many studies. Certain studies revealed that ELC increased conversion rate to laparotomy, postoperative complications and prolong duration of surgery [50]. But, with current advances in surgery, ELC became the gold standard treatment of AC [51, 52]. No significant difference has been reported in terms of procedure time, morbidity or mortality between laparoscopy and open surgery. Recent studies approved that ELC has a significantly short postoperative recovery time compared to DLC and open surgery [47, 53]. The last guideline published by the WSES in 2020 [12] emphasized management of AC and recommended ELC within 7 days from hospital admission and within 10 days from the onset of symptoms for grade III AC. DLC should be performed 6 weeks after the first clinical sign in case ELC cannot be done. The WSES suggested to avoid ELC in case of septic shock and prefer antibiotics with PC as temporary treatment for patients unfit for early surgery. This aims to minimize any risk of intra-operative complications. In a single-center retrospective study published in 2020 by Cheng X et al. [54], 104 patients were included. 70 patients underwent DLC and 34 underwent ELC. There was no heterogeneity

between both groups in terms of operation mean time, mortality and conversion rates. The author concluded that; DLC is safe and feasible when patients with AC missed the golden 72 hours for ELC. Many authors reported a high rate of biliary complains after DLC compared to ELC [55, 56]. Some meta-analyses presented DLC leads to high conversion rate to open surgery, long operating time and increased postoperative complications and mortality [57, 58]. To prevent intra operative difficulties such as BDI due to bad visualization of anatomic structures, Wakabayashi G et al. [8] recommended intra operative cholangiography or Ultrasonography after a preoperative MRCP. Ng ZQ et al. [48] reported in 2018, a rare case of Hemorrhagic cholecystitis that necessitated an emergent cholecystectomy to prevent fatal perforation of the gallbladder because of bad prognosis of this clinical presentation. They suggested the necessity of ultrasound and CT scan to diagnose such severe co morbidities.

For patients at risk for surgery due to comorbidities, the choice of treatment is discussed between gallbladder drainage as alternative of surgery and drainage followed by DLC 4-6 weeks later. Gurusamy et al. [22] investigated the efficacy of PC in the management of elderly and high-risk patients with AC. Two studies including 156 patients managed with PC either as alternative of surgery or temporary treatment prior to surgery were included for analysis. No difference has been reported between both groups concerning morbidity and mortality. Another systematic review conducted by Ambe PC et al. [59] suggested PC to be associated with increased mortality rate. The cause of death was directly related to AC and no distinction was made between deaths during and after procedure. Patients who underwent PC stayed more days to the hospital than those managed with surgery. The rate of readmission for biliary complains was higher in the PC group. No difference in odds of complications and reintervention has been reported among both groups. Reasons for readmission were catheter slippage, bile leakage, persistent or recurrent cholecystitis that could eventually necessitate reintervention (placement of a new PC catheter or cholecystectomy). Mattone E et al. [60] reported a case of PC treatment failure in a covid-19 patient who initially was unfit for surgery because of respiratory deficiency. After PC, this patient presented a gangrenous gallbladder despite multidisciplinary treatment that he underwent and eventually the surgeon performed DLC. Despite that PC can be easily substituted by ERCP, Merei F et al. [61] reported a case of multifocal pyogenic abscess formation following ERCP procedure. These complications linked

to gallbladder drainage justify numerous treatment failure observed when cholecystostomy is used as an alternative of surgery [7, 20, 30, 32, 61].

6. Conclusion

Diagnostic methods of AC associated clinical findings, biological and radiologic assessments. ELC is the best treatment for Grade I and Grade II patients of the TG18 grading scale. DLC after a temporary drainage is indicated for Grade III patients who missed the golden time for ELC and those presenting co morbidities with high risk intra-operative complications if surgery is performed early. Endoscopic transpapillary or nasobiliary drainage and ultrasound –assisted drainage brought great progress in cholecystostomy methods. Many scholars reported these new technologies as alternative of surgery for patients presenting severe co morbidities.

References

1. Elkbuli A, Meneses E, Kinslow K, Boneva D, McKenney M. Current grading of gall bladder cholecystitis and management guidelines: Is it sufficient? *Ann Med Surg (Lond)*. 2020; 60: 304-7.
2. Knab LM, Boller AM, Mahvi DM. Cholecystitis. *Surg Clin North Am*. 2014; 94(2): 455-70.
3. Poddighe D, Sazonov V. Acute acalculous cholecystitis in children. *World J Gastroenterol*. 2018; 24(43): 4870-9.
4. Jones MW, Genova R, O'Rourke MC. Acute Cholecystitis. *StatPearls*. Treasure Island (FL): StatPearls Publishing Copyright © 2021, StatPearls Publishing LLC. 2021.
5. Huffman JL, Schenker S. Acute acalculous cholecystitis: a review. *Clin Gastroenterol Hepatol*. 2010; 8(1): 15-22.
6. Kalliafas S, Ziegler DW, Flancbaum L, Choban PS. Acute acalculous cholecystitis: incidence, risk factors, diagnosis, and outcome. *Am Surg*. 1998; 64(5): 471-5.
7. Takeda T, Sasaki T, Mie T, Furukawa T, Kanata R, Kasuga A, et al. Novel risk factors for recurrent biliary obstruction and pancreatitis after metallic stent placement in pancreatic cancer. *Endosc Int Open*. 2020; 8(11): E1603-e10.
8. Wakabayashi G, Iwashita Y, Hibi T, Takada T, Strasberg SM, Asbun HJ, et al. Tokyo Guidelines 2018: surgical management of acute cholecystitis: safe steps in laparoscopic cholecystectomy for acute cholecystitis (with videos). *J Hepatobiliary Pancreat Sci*. 2018; 25(1): 73-86.
9. Bekki T, Abe T, Amano H, Hanada K, Kobayashi T, Noriyuki T, et al. Validation of the Tokyo guideline 2018 treatment proposal for acute cholecystitis from a single-center retrospective analysis. *Asian J Endosc Surg*. 2021; 14(1): 14-20.
10. Wang SY, Yeh CN, Jan YY, Chen MF. Management of Gallstones and Acute Cholecystitis in Patients with Liver Cirrhosis: What Should We Consider When Performing Surgery? *Gut Liver*. 2021; 15(4): 517-27.
11. Yokoe M, Hata J, Takada T, Strasberg SM, Asbun HJ, Wakabayashi G, et al. Tokyo Guidelines 2018: diagnostic criteria and severity grading of acute cholecystitis (with videos). *J Hepatobiliary Pancreat Sci*. 2018; 25(1): 41-54.
12. Pisano M, Allievi N, Gurusamy K, Borzellino G, Cimbanassi S, Borna D, et al. 2020 World Society of Emergency Surgery updated guidelines for the diagnosis and treatment of acute calculus cholecystitis. *World J Emerg Surg*. 2020; 15(1): 61.
13. Mou D, Tesfasilassie T, Hirji S, Ashley SW. Advances in the management of acute cholecystitis. *Ann Gastroenterol Surg*. 2019; 3(3): 247-53.
14. Patel G, Jain A, Kumar RB, Singh N, Karim T, Mishra R. Gallbladder Perforation: A Prospective Study of Its Divergent Appearance and Management. *Euroasian J Hepatogastroenterol*. 2019; 9(1): 14-9.
15. Littlefield A, Lenahan C. Cholelithiasis: Presentation and Management. *J Midwifery Womens Health*. 2019; 64(3): 289-97.
16. Raffee L, Kuleib S, Oteir A, Kewan T, Alawneh K, Beovich B, et al. Utility of leucocytes, inflammatory markers and pancreatic enzymes as indicators of gangrenous cholecystitis. *Postgrad Med J*. 2020; 96(1133): 134-8.
17. Jain A, Mehta N, Secko M, Schechter J, Papanagnou D, Pandya S, et al. History, Physical Examination, Laboratory Testing, and Emergency Department Ultrasonography for the Diagnosis of Acute Cholecystitis. *Acad Emerg Med*. 2017; 24(3): 281-97.
18. Ukegijini K, Schmied BM. [Diagnosis and treatment of acute cholecystitis]. *Ther Umsch*. 2020; 77(4): 133-46.
19. Menéndez-Sánchez P, León-Salinas C, Amo-Salas M, Méndez-Cea B, García-Carranza A. Association of laboratory and radiologic parameters in the diagnosis of acute cholecystitis. *Rev Gastroenterol Mex (Engl Ed)*. 2019; 84(4): 449-54.
20. Sanaiha Y, Juo YY, Rudasill SE, Jaman R, Sareh S, de Virgilio C, et al. Percutaneous cholecystostomy for grade III acute cholecystitis is associated with worse outcomes. *Am J Surg*. 2020; 220(1): 197-202.
21. Eskelinen M, Meklin J, Syrjänen K, Eskelinen M. Performance of a Diagnostic Score in Confirming Acute Cholecystitis Among Patients With Acute Abdominal Pain. *Anticancer Res*. 2020; 40(12): 6947-56.
22. Miura F, Takada T, Strasberg SM, Solomkin JS, Pitt HA, Gouma DJ, et al. TG13 flowchart for the management of acute cholangitis and cholecystitis. *J Hepatobiliary Pancreat Sci*. 2013; 20(1): 47-54.
23. Meeroff M. Medical treatment of acute cholecystitis. *Medicina (Madr)*. 1958; 26(6-7): 189-220.
24. Entremont PD. [Treatment of acute cholecystitis]. *Union Med Can*. 1959; 88(4): 437-40.
25. Dehni N, Schielke A. [Acute cholecystitis]. *Rev Prat*. 2007; 57(19): 2134-8.
26. SIa K. [Remote results of conservative and surgical treatment of acute cholecystitis]. *Sov Med*. 1958; 22(1): 106-9.
27. Bubnova OP. [Remote results of the conservative and surgical treatment of cholecystitis]. *Klin Med (Mosk)*. 1969;47(1):54-7.
28. Fujinaga A, Iwashita Y, Tada K, Watanabe K, Kawasaki T, Masuda T, et al. Efficacy of releasing impacted gallstones after percutaneous

- transhepatic gallbladder drainage for acute cholecystitis and consideration of the surgical difficulty during laparoscopic cholecystectomy. *J Hepatobiliary Pancreat Sci.* 2021; 28(11): 993-9.
29. Podboy A, Yuan J, Stave CD, Chan SM, Hwang JH, Teoh AYW. Comparison of EUS-guided endoscopic transpapillary and percutaneous gallbladder drainage for acute cholecystitis: a systematic review with network meta-analysis. *Gastrointest Endosc.* 2021; 93(4): 797-804.e1.
 30. Di Martino M, Miguel Mesa D, Lopesino González JM, de la Hoz Rodríguez Á, Martín-Pérez E. Safety of Percutaneous Cholecystostomy Early Removal: A Retrospective Cohort Study. *Surg Laparosc Endosc Percutan Tech.* 2020; 30(5): 410-5.
 31. Kozarek RA. Selective cannulation of the cystic duct at time of ERCP. *J Clin Gastroenterol.* 1984; 6(1): 37-40.
 32. Lyu Y, Li T, Wang B, Cheng Y, Chen L, Zhao S. Comparison of Three Methods of Gallbladder Drainage for Patients with Acute Cholecystitis Who Are at High Surgical Risk: A Network Meta-Analysis and Systematic Review. *J Laparoendosc Adv Surg Tech A.* 2021; 31(11): 1295-302.
 33. Anderloni A, Buda A, Vieceli F, Khashab MA, Hassan C, Repici A. Endoscopic ultrasound-guided transmural stenting for gallbladder drainage in high-risk patients with acute cholecystitis: a systematic review and pooled analysis. *Surg Endosc.* 2016; 30(12): 5200-8.
 34. Yang MJ, Yoo BM, Kim JH, Hwang JC, Baek NH, Kim SS, et al. Endoscopic naso-gallbladder drainage versus gallbladder stenting before cholecystectomy in patients with acute cholecystitis and a high suspicion of choledocholithiasis: a prospective randomised preliminary study. *Scand J Gastroenterol.* 2016; 51(4): 472-8.
 35. Sobani ZA, Ling C, Rustagi T. Endoscopic Transpapillary Gallbladder Drainage for Acute Cholecystitis. *Dig Dis Sci.* 2021; 66(5): 1425-35.
 36. Di Martino M, Mora-Guzmán I, Vaello Jodra V, Sanjuanbenito Dehesa A, Morales-García D, Caiña Ruiz R, et al. Laparoscopic cholecystectomy for acute cholecystitis: is the surgery still safe beyond the 7-day barrier? A multicentric observational study. *Updates Surg.* 2021; 73(1): 261-72.
 37. Di Buono G, Romano G, Galia M, Amato G, Maienza E, Vernuccio F, et al. Difficult laparoscopic cholecystectomy and preoperative predictive factors. *Sci Rep.* 2021; 11(1): 2559.
 38. Altieri MS, Brunt LM, Yang J, Zhu C, Talamini MA, Pryor AD. Early cholecystectomy (< 72 h) is associated with lower rate of complications and bile duct injury: a study of 109,862 cholecystectomies in the state of New York. *Surg Endosc.* 2020; 34(7): 3051-6.
 39. Stanistic V, Milicevic M, Kocev N, Stanistic B. A prospective cohort study for prediction of difficult laparoscopic cholecystectomy. *Ann Med Surg (Lond).* 2020; 60: 728-33.
 40. Kohga A, Okumura T, Yamashita K, Isogaki J, Kawabe A, Kimura T. Does early surgery imply a critical risk for patients with Grade III acute cholecystitis? *Asian J Endosc Surg.* 2021; 14(1): 7-13.
 41. Ohya H, Maeda A, Takayama Y, Takahashi T, Seita K, Kaneoka Y. Preoperative risk factors for technical difficulty in emergent laparoscopic cholecystectomy for acute cholecystitis. *Asian J Endosc Surg.* 2021; 15(1): 82-9.
 42. Warchałowski Ł, Łuszczki E, Bartosiewicz A, Dereń K, Warchałowska M, Oleksy Ł, et al. The Analysis of Risk Factors in the Conversion from Laparoscopic to Open Cholecystectomy. *Int J Environ Res Public Health.* 2020; 17(20).
 43. Jang YR, Ahn SJ, Choi SJ, Lee KH, Park YH, Kim KK, et al. Acute cholecystitis: predictive clinico-radiological assessment for conversion of laparoscopic cholecystectomy. *Acta Radiol.* 2020; 61(11): 1452-62.
 44. Park SW, Lee SS. Current status of endoscopic management of cholecystitis. *Dig Endosc.* 2021.
 45. Joseph B, Jehan F, Dacey M, Kulvatunyou N, Khan M, Zeeshan M, et al. Evaluating the Relevance of the 2013 Tokyo Guidelines for the Diagnosis and Management of Cholecystitis. *J Am Coll Surg.* 2018; 227(1): 38-43.e1.
 46. Dimou FM, Adhikari D, Mehta HB, Riall TS. Outcomes in Older Patients with Grade III Cholecystitis and Cholecystostomy Tube Placement: A Propensity Score Analysis. *J Am Coll Surg.* 2017; 224(4): 502-11.e1.
 47. Shikata S, Noguchi Y, Fukui T. Early versus delayed cholecystectomy for acute cholecystitis: a meta-analysis of randomized controlled trials. *Surg Today.* 2005; 35(7): 553-60.
 48. Ng ZQ, Pradhan S, Cheah K, Wijesuriya R. Haemorrhagic cholecystitis: a rare entity not to be forgotten. *BMJ Case Rep.* 2018; 2018.
 49. Okamoto K, Suzuki K, Takada T, Strasberg SM, Asbun HJ, Endo I, et al. Tokyo Guidelines 2018: flowchart for the management of acute cholecystitis. *J Hepatobiliary Pancreat Sci.* 2018; 25(1): 55-72.
 50. Kum CK, Eypasch E, Lefering R, Paul A, Neugebauer E, Troidl H. Laparoscopic cholecystectomy for acute cholecystitis: is it really safe? *World J Surg.* 1996; 20(1): 43-8.
 51. Bundgaard NS, Bohm A, Hansted AK, Skovsen AP. Early laparoscopic cholecystectomy for acute cholecystitis is safe regardless of timing. *Langenbecks Arch Surg.* 2021; 406(7): 2367-73.
 52. Lin YN, Wu YT, Fu CY, Liao CH, Cheng CT, Wang SY, et al. Evaluating the advantages of treating acute cholecystitis by following the Tokyo Guidelines 2018 (TG18): a study emphasizing clinical outcomes and medical expenditures. *Surg Endosc.* 2020; 35(12): 6623-32.
 53. Kum CK, Goh PM, Isaac JR, Tekant Y, Ngoi SS. Laparoscopic cholecystectomy for acute cholecystitis. *Br J Surg.* 1994; 81(11): 1651-4.
 54. Cheng X, Cheng P, Xu P, Hu P, Zhao G, Tao K, et al. Safety and feasibility of prolonged versus early laparoscopic cholecystectomy for acute cholecystitis: a single-center retrospective study. *Surg Endosc.* 2021; 35(5): 2297-305.
 55. El Nakeeb A, Ezzet H, Askar W, El Hanafy E, Hamdy E, Atef E, et al. Early Versus Late Cholecystectomy After Clearance of Common Bile Duct Stones by Endoscopic Retrograde Cholangiopancreatography: A Prospective Randomized Study. *Surg Laparosc Endosc Percutan Tech.* 2016; 26(3): 202-7.

56. Rattner DW, Ferguson C, Warshaw AL. Factors associated with successful laparoscopic cholecystectomy for acute cholecystitis. *Ann Surg.* 1993; 217(3): 233-6.
57. Papi C, Catarci M, D'Ambrosio L, Gili L, Koch M, Grassi GB, et al. Timing of cholecystectomy for acute calculous cholecystitis: a meta-analysis. *Am J Gastroenterol.* 2004; 99(1): 147-55.
58. Lyu Y, Cheng Y, Wang B, Zhao S, Chen L. Early versus delayed laparoscopic cholecystectomy for acute cholecystitis: an up-to-date meta-analysis of randomized controlled trials. *Surg Endosc.* 2018; 32(12): 4728-41.
59. Ambe PC, Kaptanis S, Papadakis M, Weber SA, Jansen S, Zirngibl H. The Treatment of Critically Ill Patients With Acute Cholecystitis. *Dtsch Arztebl Int.* 2016; 113(33-34): 545-51.
60. Mattone E, Sofia M, Schembari E, Palumbo V, Bonaccorso R, Randazzo V, et al. Acute acalculous cholecystitis on a COVID-19 patient: a case report. *Ann Med Surg (Lond).* 2020; 58: 73-5.
61. Merai F, Shapiro G, Abu Shakra I, Bickel A, Ganam S, Bez M, et al. A unusual case of multifocal pyogenic abscess formation following ERCP procedure. *BMC Surg.* 2020; 20(1): 92.