

## Iatrogenic Cystic Artery Pseudoaneurysm Post Laparoscopic Cholecystectomy- A Case Report with Literature Review

Po Hong Tan<sup>1\*</sup>, Elyaraitul Nadia Rahim<sup>1</sup>, Kah Chun Yong<sup>1</sup>, Norhafizah Ehsan<sup>2</sup> and Kharlina Khairudin<sup>1</sup>

<sup>1</sup>General Surgery, Hospital Sultanah Aminah, Malaysia

<sup>2</sup>Interventional Radiology, Hospital Sultanah Aminah, Malaysia

### \*Corresponding author:

Po Hong Tan,  
General Surgery, Hospital Sultanah Aminah,  
Malaysia, Tel: +60123219043,  
E-mail: tanpohong.tph@gmail.com

Received: 12 Apr 2022

Accepted: 09 May 2022

Published: 13 May 2022

J Short Name: COS

### Copyright:

©2022 Po Hong Tan. This is an open access article distributed under the terms of the Creative Commons Attribution License, which permits unrestricted use, distribution, and build upon your work non-commercially.

### Citation:

Po Hong Tan. Iatrogenic Cystic Artery Pseudoaneurysm Post Laparoscopic Cholecystectomy- A Case Report with Literature Review. Clin Surg. 2022; 7(9): 1-5

### Keywords:

Cholecystectomy; Laparoscopic; Aneurysm; False; Hemobilia

### 1. Abstract

Cystic Artery pseudoaneurysm post laparoscopic cholecystectomy is a rare complication associated with potential risk of morbidity and mortality. This is a case of cystic artery pseudoaneurysm post laparoscopic cholecystectomy in a 27-year-old female who presented post op day 10 post laparoscopic cholecystectomy with abdominal pain, melena and haematemesis. OGDS showed no active bleeder and initial CT only showed gallbladder hematoma which was treated in percutaneous drainage. However, recurrent symptoms prompt a CT Angiography which revealed a cystic artery pseudoaneurysm with hemoperitoneum. The pseudoaneurysm was successfully treated with trans-arterial catheter embolization of the cystic artery stump. She was well post intervention but required parenteral antibiotics resulting in a 2weeks hospitalization and eventually discharged. Literature review reports only 10 cases of iatrogenic cystic artery pseudoaneurysm post laparoscopic cholecystectomy in the last two decades. Based on our literature review, the main presentation is usually hemobilia (70%), age of patient ranging 26 to 79 years old and timing of presentation ranging from 1 weeks to 3 years post laparoscopic cholecystectomy. The pathophysiology is often due to indirect or direct thermal injury during cauterization. CT angiography is the investigation of choice. Trans arterial embolization is the treatment of choice with high success rate. However, surgery still plays a role in complex cases where embolization failed. There should be a high index of suspicion of such pathology especially in patients who present with upper gastrointestinal bleed post cholecystectomy so early diagnosis and treatment can be done.

### 2. Introduction

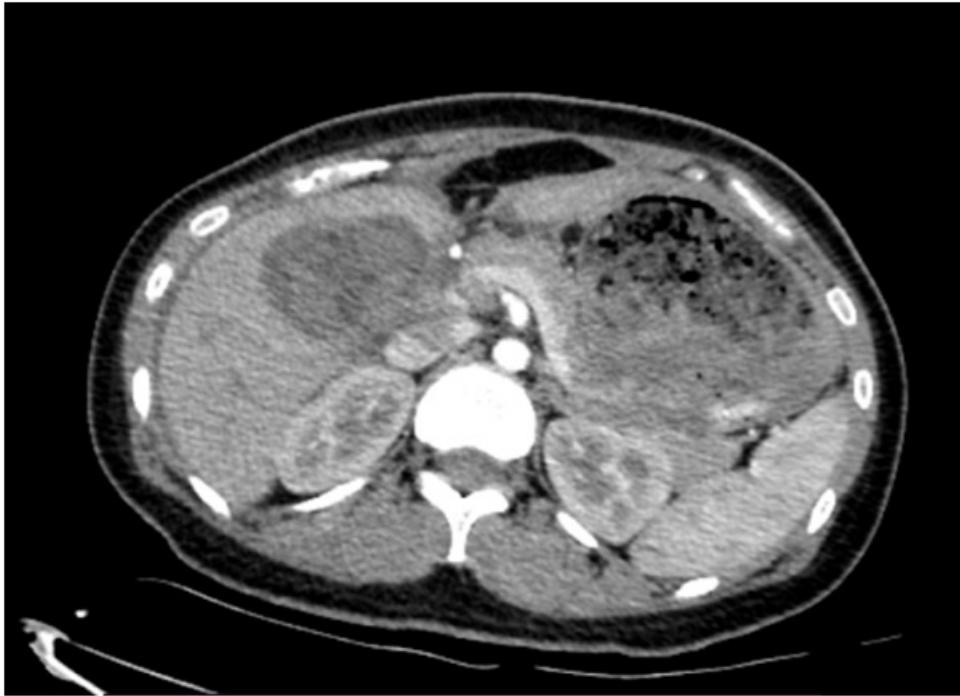
Laparoscopic cholecystectomy has been the gold standard of treatment for cholelithiasis in the 21st century. It has distinct advantages due to minimally invasive, reduced complications and reduced hospital stay compared to open technique. It is very rarely associated with vascular complications. However, it does happen. Mechanism involved is likely due to thermal or direct injury to vascular wall. Patient normally present with upper gastrointestinal bleed, abdominal or jaundice. We here present a case report and literature review of cystic artery pseudoaneurysm post laparoscopic cholecystectomy. The presentation, diagnosis and management are discussed.

### 3. Case Report

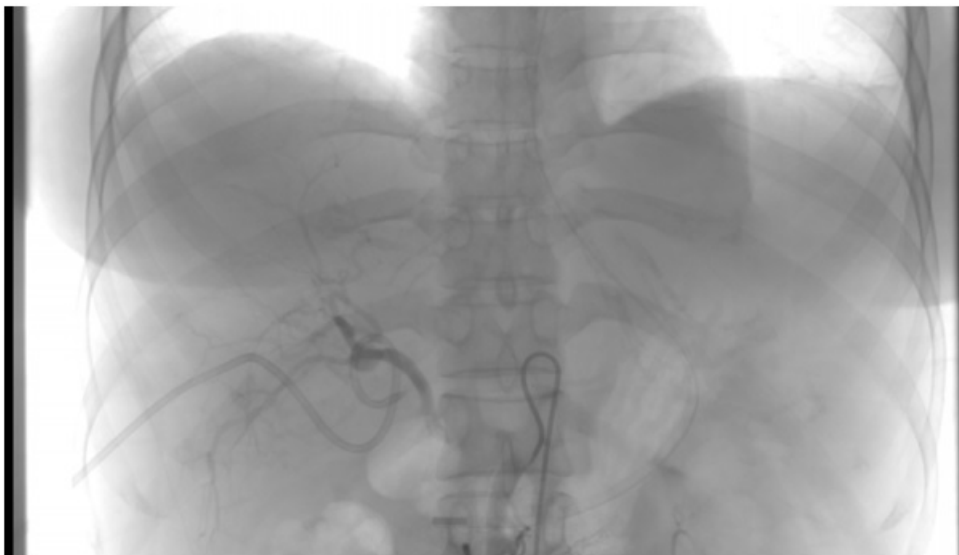
A 27-year-old female, who is postoperative day 11 of laparoscopic cholecystectomy presented to a private hospital with abdominal pain with haemodynamic instability. There were no intra-operative difficulties encountered during the that time. Physical examination revealed patient was pale, with tender abdomen at the right hypochondriac region. Blood works and CT scan revealed the patient was anaemic with Hb of 8.2, and CT scan showed gallbladder bed haematoma (Figure 1.1). Patient is treated with blood transfusion and an ultrasound guided drainage of gallbladder bed hematoma was done. Subsequently, the symptoms resolved. However, the patient had an episode of upper gastrointestinal bleed 1-day post procedure, an urgent upper endoscopy was done which no active or recent bleeders were identified. CT Angiography was then done which showed cystic artery pseudoaneurysm with massive hemoperitoneum. Decision was made for angio-embolization after

multidisciplinary discussion between hepato-biliary team and interventional radiology team. Coiling of the right hepatic artery was then done (Figure 1.2 and 1.3). Patient was well after with no more

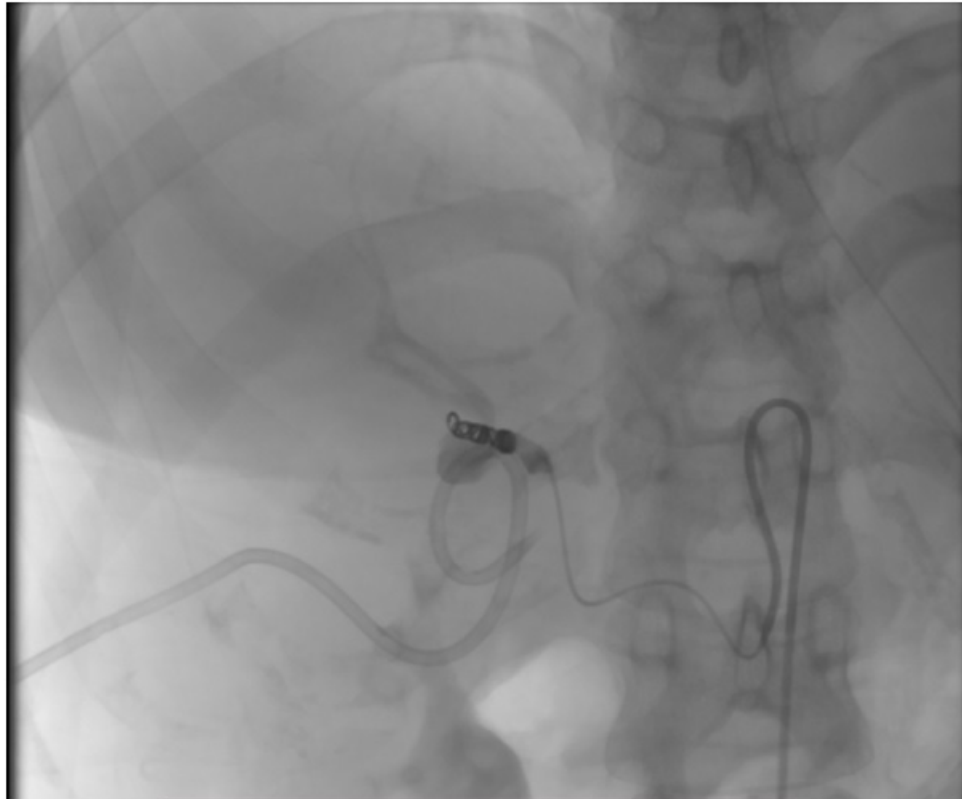
episodes of UGIB or abdominal pain, recovery was uneventful and patient was subsequently discharged.



**Figure 1.1:** CT scan showing Gallbladder bed hematoma.



**Figure 1.2.** Angiography of cystic artery pseudoaneurysm before angioembolization.



**Figure 1.3.** Angiography showing cystic artery pseudoaneurysm post coil embolization.

#### 4. Methods

An extensive literature search is carried out in the PubMed databases. All case reports of cystic artery pseudoaneurysms related to laparoscopic cholecystectomies from 2000 to 2020 are included (Table 1.1). Additionally, we present a case of cystic artery pseudoaneurysm that were treated in our centre and included its data in the literature review. 10 case reports were found between year 2000 to 2022 including our own case report. The main presentation was upper gastrointestinal bleed 7 (70%), followed by abdominal pain

with jaundice 3 (30%). There is a near equal gender distribution of 6 females (60%), and 4 males (40%). Age of patients involved are wide ranging from 26 to 79 years of age, with mean of 48. Timing of presentation ranges from 1 week to 3 years post laparoscopic cholecystectomy. 8 patients were treated with angio-embolization (80%). 6 were successful (75%) while 2 required further intervention. 1 case needing excision of pseudoaneurysm while the other required percutaneous thrombin injection. 2 cases (20%) were treated primarily with surgical intervention. There was no mortality reported in these 10 case reports.

**Table 1.1:** 9 cases of iatrogenic cystic artery pseudoaneurysm post laparoscopic cholecystectomy on PubMed database from 2000 to 2020, including our case report.

References	Author	Year of Article	Age	Sex	Symptoms	Time of presentation	Treatment
Int Surg. 2012 Apr-Jun; 97(2): 140–144 [1]	Athanosious Petrou	2012	31	Female	Haemobilia	3 months	Angioembolization, followed by ligation of pseudoaneurysm
Trop Gastroenterol. Apr-Jun 2008;29(2):107-9 [2]	V Moses	2008	26	Male	Haemobilia	3 months	Angioembolization
Surg Today • 2008;38(6):567-71 [3]	Yuen Nakase	2008	63	Female	Haemobilia	11 days	Angioembolization
HPB (Oxford). 2006; 8(4): 318–319 [4]	O.L. De Molla Neto	2006	31	Female	Abdominal Pain and Jaundice	50 days	Ligation of RHA
J Laparoendosc Adv Surg Tech A .2006 Dec;16(6):609-12[5]	Jens Heyn	2006	78	Male	Haemobilia	1 year	Excision of pseudoaneurysm
Surgery 2002 May;131(5):585-6[6]	Pierre F Saldinger	2002	50	Female	Haemobilia	1 week	Angioembolization

Hong Kong Med J 2018 Apr;24(2):203–5[7]	K To	2018	56	Male	Haemobilia	4 weeks	Angioembolization
ACG Case Rep J. 2017; 4: e38 [8]	Ricardo Badillo	2017	79	Male	Abdominal Pain, Jaundice	15 months	Angioembolization
Clin Imaging . Jul-Aug 2014;38(4):522-525[9]	Abhishek Kumar	2014	45	Female	Haemobilia	3 years	Angioembolization and percutaneous thrombin injection
Current Case Report	Tan PH	2022	26	Female	Haemobilia	11 days	Angio-embolization

## 5. Discussion

Cystic artery pseudoaneurysm post laparoscopic cholecystectomy is rare. Despite laparoscopic cholecystectomy being a common procedure in the 21st century, only about 10 cases were reported for the past 2 decades. Most case reports of vascular pseudoaneurysm post laparoscopic cholecystectomy were the involvement of right hepatic artery with only minority involving cystic artery [10]. Multiple theories for development of such complication are proposed. Direct injury, thermal injury and bile leak leading to vascular wall damage is some of the proposed mechanism. Thermal injury can be direct or indirect through metal clips. Bile acid from bile leaks causing erosion of vascular wall can be a cause as well. There was no mortality in case reports of cystic artery pseudoaneurysm reported. However, there are cases reported of mortality in other vessel involvement. Based on our literature review, there is wide age range of presentation ranging from 26 to 79 years of age. This data could possibly indicate that surgical factors such as difficult cholecystectomies rather than patient factor plays a bigger role in pathophysiology of such complications. However, there are insufficient data to prove this statement, as there are cases where these complications developed in absence of intra-operative difficulties [4]. There is also wide timing of presentation post op possibly due to the fact that majority of pseudoaneurysm remain asymptomatic during initial phase. However, regardless of the pathophysiology, age and time of presentation, the diagnostic and treatment modalities remain roughly the same. CT Angiography is the diagnosis of choice with high sensitivity. Modalities of treatment in most case reported are angio-embolization with a high success rate. Gel foam, coils or thrombin can be used to embolize blood vessels. Regardless of mode of embolization, most patient treated with trans-arterial embolization yield good outcome [3,4,7,8,9]. There is much less risk compared to surgery and most cases only local anaesthesia needed. However, there is associated failure and complications, such as failure in coiling due to coagulopathies [2], difficulties in placing, cannulation issues, misidentification of vessels, or loosely packed coils. In successful trans-arterial embolization, there are complications such as liver abscess [4], ischaemia, and post-procedure bleeding. In cases where service is not available or embolization failed, surgical repair would be recommended which yield good outcome [2,5,6]. Most common surgical options for pseudoaneurysm are either excision of aneurysm or ligation of the right hepatic artery. There are even reported case where ligation of pseudoaneurysm was done laparoscopically [11].

Regardless done open or laparoscopically, it does come with complication such as failure of excision. Ligation of right hepatic artery can be done with high success rate and a low risk of liver ischaemia due to portal vein flow. Generally, surgical treatment yields good outcome based on recent literature review [1]. There is also one case reported where the cystic artery pseudoaneurysm was treated successfully with percutaneous thrombin injection. However, it does carry risk of liver ischaemia, although it did not happen in this particular case.

## 6. Conclusion

Cystic artery pseudoaneurysm post laparoscopic cholecystectomy is rare but relevant in clinical settings as it is a very common procedure. There is potential risk of high morbidity and mortality if not diagnosed and treated early. We as clinician should have high index of suspicion of such complication especially in patients presenting with upper gastro intestinal bleed post laparoscopic cholecystectomy so that it can be treated timely and appropriately.

## References

- Petrou A, Brennan N, Soonawalla Z, Silva MA. Hemobilia due to cystic artery stump pseudoaneurysm following laparoscopic cholecystectomy: Case presentation and literature review [Internet]. International surgery. International College of Surgeons. 2012.
- Moses V, Keshava SN, Cornerstone Wann V, Joseph P, Sitaram V. Cystic artery pseudoaneurysm after laparoscopic cholecystectomy presenting as Haemobilia: A case report [Internet]. Tropical gastroenterology: official journal of the Digestive Diseases Foundation. U.S. National Library of Medicine. 2022.
- Nakase Y, Takagi T, Fukumoto K, Kassai K, Yamagami T, Itani K, et al. Hemobilia and cystic artery stump pseudoaneurysm associated with liver abscess after a laparoscopic cholecystectomy: Report of a case [Internet]. Surgery today. U.S. National Library of Medicine. 2022.
- De Molla Nateo OL, Ribeiro MAF, Saad WA. Pseudoaneurysm of cystic artery after laparoscopic cholecystectomy [Internet]. HPB: the official journal of the International Hepato Pancreato Biliary Association. U.S. National Library of Medicine. 2022.
- Heyn J, Sommerey S, Schmid R, Hallfeldt K, Schmidbauer S. Fistula between cystic artery pseudoaneurysm and cystic bile duct cause of acute anemia one year after laparoscopic cholecystectomy [Internet]. Journal of laparoendoscopic & advanced surgical techniques. Part A. U.S. National Library of Medicine. 2022.
- Saldinger PF, Wang JY, Boyd C, Lang E. Cystic artery stump pseu-

- doaneurysm following laparoscopic cholecystectomy [Internet]. Surgery. U.S. National Library of Medicine. 2022.
7. K TO, Eric CH Lai, Daniel TM Chung, Oliver CY Chan, CN Tang. Cystic artery pseudoaneurysm with Haemobilia after laparoscopic cholecystectomy [Internet]. HKMJ. 2018.
  8. Badillo R, Darcy MD, Kushnir VM. Hemobilia due to cystic artery Pseudoaneurysm: A rare late complication of laparoscopic cholecystectomy [Internet]. ACG case reports journal. U.S. National Library of Medicine. 2021
  9. Kumar A, Sheikh A, Partyka L, Contractor S. Cystic artery pseudoaneurysm presenting as a complication of laparoscopic cholecystectomy treated with percutaneous thrombin injection [Internet]. Clinical imaging. U.S. National Library of Medicine. 2022.
  10. Machado NO, Al-Zadjali A, Kakaria AK, Younus S, Rahim MA, Al-Sukaiti R. Hepatic or cystic artery Pseudoaneurysms following a laparoscopic cholecystectomy: Literature review of aetiopathogenesis, presentation, diagnosis and management [Internet]. Sultan Qaboos University medical journal. Sultan Qaboos University Medical Journal, College of Medicine & Health Sciences. 2017.
  11. Panda N, Narasimhan M, Gunaraj A, Ardhhanari R. Laparoscopic management of post-cholecystectomy sectoral artery pseudoaneurysm [Internet]. Journal of minimal access surgery. Medknow Publications & Media Pvt Ltd. 2014.