

Role of Loop Electrosurgical Excision Procedure in the Management of Precancerous Lesions of the Cervix in Developing Countries

Pambou O^{1,2,5*}, Mokondjimobe E^{2,5}, Baleka AM³, Essimo JM³, Longo-Mbenza^{4,5,6} and Kisoka LC⁵

¹Private Hospital in West Paris, University of Versailles Saint-Quentin-en-Yvelines

²Faculty of Health Sciences, Marien Ngouabi University, Brazzaville, Republic of Congo

³Department of Gyneco-obstetrics, University of Kinshasa, Kinshasa, Democratic Republic of Congo

⁴Department of Internal Medicine, University of Kinshasa, Kinshasa, Democratic Republic of Congo

⁵Department of Public Health, Lomo University of Research, Kinshasa, Democratic Republic of Congo

⁶Faculty of Health Sciences, Walter Sisulu University, Mthatha, South Africa

*Corresponding author:

Benjamin Longo-Mbenza
Department of Internal Medicine, University of Kinshasa, Department of Public Health, Lomo University of Research, Kinshasa, Kinshasa, Democratic Republic of Congo, Faculty of Health Sciences, Walter Sisulu University, Mthatha, South Africa, Tel: +33676942374; E-mail: longombenza@gmail.com

Received: 26 Jan 2023
Accepted: 21 Mar 2023
Published: 29 Mar 2023
J Short Name: COS

Copyright:

©2023 Pambou O, This is an open access article distributed under the terms of the Creative Commons Attribution License, which permits unrestricted use, distribution, and build upon your work non-commercially.

Citation:

Pambou O. Role of Loop Electrosurgical Excision Procedure in the Management of Precancerous Lesions of the Cervix in Developing Countries. Clin Surg. 2023; 9(2): 1-8

Keywords:

Precancerous lesions of the cervix; LEEP; Developing countries

1. Abstract

1.1. Purpose: The human papilloma virus (HPV) causes 80% of cases of cervical cancer. The World Health Organization recommends the use of cryotherapy or loop electrosurgical excision procedure (LEEP) for treating these lesions. This study evaluated the role of LEEP in developing countries and aimed to demonstrate that excision of high-grade cervical precancerous lesions by LEEP is simple, reproducible, inexpensive.

1.2. Patients and Methods: This non-randomized observational analytical retrospective study was performed for over 4 years in patients who underwent cervico-vaginal smears and HPV tests during gynecology consultation at the Private Hospital of Western Paris (PHWP) in France. Patients with pathological smear and HPV positivity were directed to colposcopy biopsy. Cervical intraepithelial neoplasia (CIN) 2 and 3 lesions were treated by LEEP under local and ambulatory anesthesia. R environment and Excel version 2018 were used for statistical analysis.

1.3. Results: 167 pathological smear positive cases (13.17%) were sent for colposcopy biopsy. HPV16 was the most frequently encountered virus (80%). More than 50% of pathological smears showed low grade atypical squamous cells of undetermined sig-

nificance or low-grade squamous intraepithelial lesions/CIN 1 lesions (41.9%). Patients with high-grade squamous intraepithelial lesions (CIN 2 and 3) (7.7% cases) were treated with LEEP; 2 had adenocarcinoma in situ and 1 squamous cell cancer. The resection margins were healthy in 99% of cases; there were no surgical or anesthetic complications in our study and no recurrence was observed in 4 years

1.4. Conclusion: Precancerous lesions (including CIN 2 and 3) of the cervix were treated by LEEP without complications or recurrences in 4 years. This simple, reproducible, and affordable surgical technique could be taught and adapted in under-equipped practices to reduce the incidence of invasive cervical cancer.

2. Introduction

Precancerous lesions of the cervix are asymptomatic. A distinction is made between low-grade (CIN I) and high-grade (CIN 2 and 3) lesions, as untreated high-grade lesions progress to invasive cancer [1,2]. Precancerous lesions are screened using cervico-vaginal (Papanicolaou) smears, colposcopy biopsy, and recently, by HPV tests. [1]

More than 95% of patients treated for precancerous lesions have an excellent prognosis; progression to invasive cancer is extremely

rare in developed countries.

The therapeutic arsenal is completed by excision methods that allow histological analysis. Electroresection with a LEEP and surgical conization with a cold scalpel, are used under highly regulated conditions for the treatment of CIN 2 and 3 lesions in cases where the endocervical junction zone cannot be visualized.

The World Health Organization (WHO) recommends two types of treatment in precancerous lesions: destructive cryotherapy, which does not allow histological analysis of the surgical specimen, and LEEP, which allows histological analysis of the sample. Complete excision of the lesion is achieved in 95% of cases. In this context, the WHO recommends the use of cryotherapy in low- and middle-income countries [7].

Cryotherapy is particularly useful in rural areas, where access to healthcare is limited. The procedure can be performed by staff with no specific training, and midwives or nurses can perform this procedure in the office [7].

LEEP is the reference technique for the treatment of precancerous lesions in developed countries [4,5,8,9]. It lasts for less than three minutes, inclusive of resection and hemostasis. As of 2022, less than 1% complications and 2% recurrences have been reported with this technique [12,13]. In developing countries, and particularly in Africa, LEEP is used sparingly in major centers. LEEP needs qualified personnel, no pathologist access, a minimalistic technical platform, electric supply, and a generator. The occurrence of complications such as hemorrhage, which may lead to hysterectomy [14], has limited its widespread use and acceptance in low-income countries.

This study aims to show that LEEP is a simple affordable technique, with minimalist technical requirements, which can be performed in developing countries with a trained personnel.

3. Patients and Methods

This retrospective observational monocentric study was performed at the PHWP in France between January 2019 and December 31, 2021. The cervico-vaginal smear (CVS) was performed in all women who attended for gynecological consultation based on the recommendations of the National Institute for the Fight against Cancer and High Authority of Health

Patients were invited for a colposcopy with directed biopsy in the event a pathological smear showed atypical squamous cells-cannot exclude high grade lesions (ASC-H) or high-grade squamous intraepithelial lesion (HSIL) in the presence of HPV with high oncogenic risk. Colposcopy biopsy was performed according to the recommendations of the French Society of Colposcopy and Cervicovaginal Pathology and the International Federation of Colposcopy and Cervical Pathology.

After clearly identifying the junction zone with 2%acetic acid and the lugol (or Shiller) test, one or more oriented biopsies were

taken from the mapped lesions in each quadrant in the clockwise direction. In cases with positive biopsy results showing precancerous lesions (high grade CIN 2, CIN 3, and occasionally multifocal CIN 1 with HPV positivity in women aged over 40 years), LEEP was offered on an outpatient basis under local anesthesia. The patient lay on the operating table in the lithotomy position; the cervix was preferably exposed using a Collin speculum. Local anesthesia was achieved by infiltrating the cervix with a solution of xylocaine and 1% adrenaline. Each quadrant of the cervix was infiltrated with 1 ml of the solution after aspiration with the syringe to exclude vessel puncture. The loop electrode was connected to the electrocautery appliance, which was in turn connected to the coagulation section generator. The size of the resection loop was selected according to the extent of the lesions; 3 sizes of Fischer excisors were available (small, medium, and large). The sample was sent to the Paris Institute of Pathology.

All patients were treated by the same practitioner, a member of the French Society of Colposcopy and Cervicovaginal Pathology and the colposcopy charter.

Excel software (Version 2018) was used for presenting the data and calculating the results; R environment (version 4.0.3) was used for logistic regression. In cases where the variables of the models tested were significant at a threshold value of $P < 0.05\%$ (Z-score test), the probability curve with its confidence interval was represented graphically.

4. Results

A total of 8416 patients were eligible for the screening smear; 1268 underwent pathological smear examination, among whom 167 (13.17%) were directed to colposcopy and biopsy. The biopsies represented 1.98% of all Pap smears taken during the study period.

4.1. Age

None of the patients aged less than 20 years had precancerous lesions in this cohort; CIN 1 lesions appeared after the age of 20 years. Precancerous lesions were mainly found in women aged between 30 and 65 years, with a strong predominance between 45 and 50 years. The average age of patients with CIN 3 was 44.72 years. Except for 1 patient who was diagnosed with adenocarcinoma at the age of 28 years, cancer (including the 2 diagnosed cases of squamous cell and adenocarcinoma) was found to develop from the age of 66 years.

4.2. Parity

The average number of children among women in our cohort was 2.1; multiparity was not observed.

4.3. Colposcopy Findings

The colposcopy data are shown in Figure 1. Almost half (49.10% [82 cases]) of colposcopy-directed biopsies showed no precancerous lesions. These lesions were categorized as metaplasia (in 34.73% [58 cases] of abnormal smears) and chronic cervicitis (in

14.37% [24 cases]).

Slightly more than 50% (85 cases) of pathological smears showed precancerous lesions; these were divided into low grade CIN (69 [41.14%]) and high grade CIN (13 [7.78%]) lesions. We identified 3 (1.79%) cases of cancer; 2 and 1 had adenocarcinomas in situ and invasive carcinoma of the cervix, respectively.

Table 1 shows the distribution of precancerous invasive cancer lesions, ECAD treatment and histopathological abnormalities by age group. Age before 60, menopausal and perimenopausal women were more represented.

Table 2 shows the distribution of patients according to postoperative status, age and histopathological lesions. The metrorrhagia was related to the histopathological lesion CIN 3 + Koilocyte (Figure 2).

Precancerous lesions are asymptomatic. The FCV, colposcopy, and biopsy triad made it possible to clearly distinguish metaplastic and cervicitis type lesions of the cervix (49.10% [82 patients]) from precancerous lesions of the CIN type (50.90% of cases).

CIN type lesions were found in 73.91% of patients aged 20–40 years. The 20–30-year age group contributed to more than a third of CIN 1 cases. Overall, 41.14% lesions were of the CIN 1 type. A total of 34.78% lesions were found in 24 patients aged 21 to 30 years; this group contributed to 34.78% of all precancerous lesions. CIN 1 lesions were uncommon at the age of 60 years (7.2% cases in this study).

High-grade CIN 2 and 3 lesions (13 cases [7.78%]) were observed from the age of 31 years in this cohort; they were commonly found (in 91.66% of cases) from the age of 40 years.

Table 1: Distribution of precancerous lesions by age group

AGE	TYPES OF LESIONS					CONIZATION/ECAD TREATMENT	Histopathology
	CIN 1	CIN 2	CIN 3	INVASIVE	AIS		
20 to 30 years old	24				1		
31 to 35 years old	16	1	1			2	CIN 3
36 to 40 years old	11	1	2			3	CIN 2 AND CIN 3
41 to 45 years old	6		4			4	CIN 1 AND CIN 3
46 to 50 years old	7		3			3	CIN 3
51 to 60 years old	5		2			2	CIN 3 +HPV
61 to 65 years old	0	1	0			1	CIN 3
66 to 70 years old	0	0	0		1	1	AIS lesions
71 to 76 years old	0			1			INVASIVE CANCER
TOTAL	69	3	12	1	2	15	

Notes:

Abbreviations: AIS, adenocarcinoma in situ; LEEP, loop electrosurgical excision procedure; HPV, human papilloma virus; CIN, cervical intraepithelial neoplasia

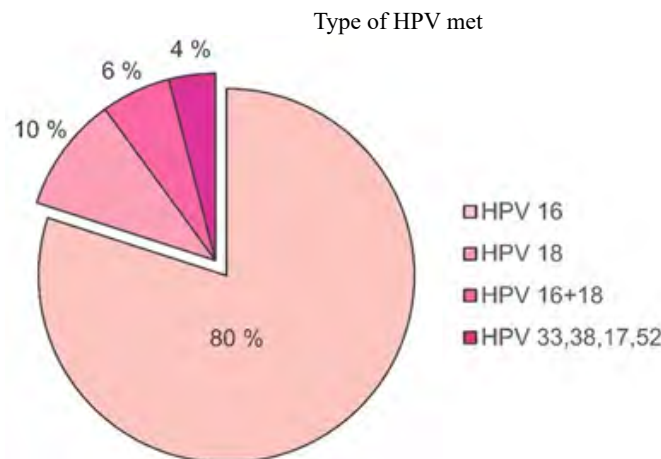


Figure 1: The colposcopy data

Table 2: Histological results of LEEP

PATIENTS	AGE	TYPE OF LESIONS	ELECTRO-CONIZATION	HEALTHY MARGINS		HISTOPATHOLOGY	POST OPERATIVE FOLLOW-UP
				YES	NO		
MOG.	43 years	CIN 1 extended				CIN 2	simple
JAN.	52 years	CIN 3		yes		CIN 3	simple
WOW.	46 years	CIN 3		yes		CIN 3	simple
BES.	47 years	CIN 1 + extended kys		yes		CIN 3	simple
ALL.	31 years	CIN 2 – CIN 3		yes		CIN 3	simple
ARVs.	66 years old	CIN 3 + endocervical curettage		yes		AIS	simple
BOU.	54 years old	CIN1 + extended HPV		yes		CIN 2+HPV	simple
DAN.	34 years old	CIN1 + HPV		yes		CIN 3	simple
KAR.	44 years	CIN1 + HPV		yes		CIN 3	simple
MAC.	41 years	CIN 1 extended		yes		CIN2-CIN 3	simple
RIC.	38 years old	CIN 3		yes		CIN 3	simple
RIV. S	45 years old	CIN 3		yes		CIN 3	simple
TAM.	50 years	CIN 3		yes		CIN 3	simple
FLIGHT.	40 years	CIN 1 + CIN 2		yes		CIN 2+HPV	simple
SIL.	28 years old	CIN 3 + koilocyte			Nope	CIN 3+AIS	metrorrhagia

Abbreviations: AIS, adenocarcinoma in situ; HPV, human papilloma virus; CIN, cervical intraepithelial neoplasia

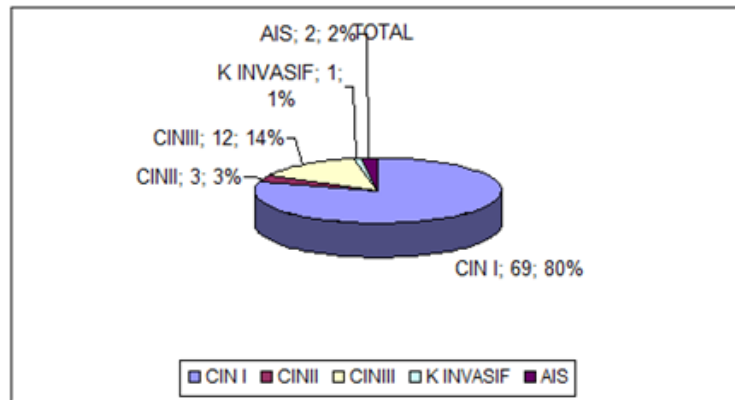


Figure 2: Distribution of high-grade lesions

4.4. Type of HPV

HPV 16 and 18 were found in 80% and 20% of cases, respectively. HPV 16 and 18 were found in 45% of cases and HPV 33,38,17, and 52 were observed in less than 10% of cases (Figure 3).

CIN 3 was associated with adenocarcinoma in situ in a 28-year-old pregnant patient. Cancer was not detected before the age of 20 years in this cohort; squamous cell carcinoma was diagnosed from the age of 66 years. Among 8,648 patients who underwent a vaginal smear test, 1 had the human immunodeficiency virus (HIV).

4.5. Resection Margins

The diagnosis was revised in one case after analyzing the surgical margins. The multifocal CIN 2 lesion in this case extended to the 4 quadrants and was located in the endocervix at more than 3 mm from the junction zone; this case was associated with positive results for HPV 16.

4.6. Cancer

Among 1268 pathological smears, 3 cases were diagnosed with cancer (ie, 0.23% and 1.79% of the biopsies); this included 2 adenocarcinoma in situ and 1 invasive squamous cell cancer.

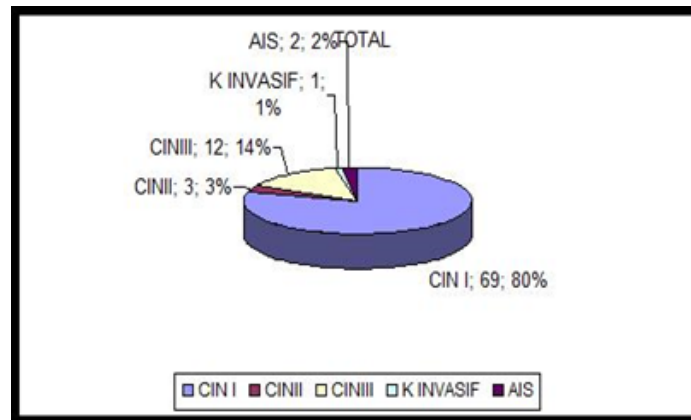


Figure 3: Types of HPV

4.6.1. Adenocarcinoma in Situ: The case histories of the 2 patients (28- and 70-year-old patients) diagnosed with adenocarcinoma in situ.

4.6.2.Squamous Cell Carcinoma: The stage IIa invasive squamous cell carcinoma that was found in a 73-year-old woman would have been diagnosed with the naked eye even without colposcopy. One patient did not undergo gynecological examination for more than 5 years; her gynecologist had retired and she no longer consider the need to have medical follow-up because of her age.

She had invasive cancer that was found to be of stage IIa at diagnosis. Biopsies outcomes during colposcopy confirmed the presence of squamous invasiveness, which constitutes an absolute contraindication to LEEP and conization. The patient underwent conventional surgery and radiotherapy.

4.7. ECAD complications during the study period

No complications related to LEEP were observed during the study period.

4.8. Recurrence

No recurrence or progression to high-grade lesions was observed until December 31, 2021 (Figure 4).

5. Discussion

Cervical cancer is a global public health concern, with one woman dying from the disease every 2 minutes. As it is a preventable disease, the Director-General of the WHO announced a call to action for cervical cancer elimination in 2018. [15]

According to the WHO, more than 90% of the 311,000 deaths in that year occurred in low-income or middle-income countries. [15] Therefore, there is an immediate need to prevent, detect, diagnose, and treat precursor lesions of cervical cancer at the institutional, non-institutional, and population level.

Our study initially focused on 1268 pathological smears; 167 smears were eligible to colposcopy biopsies. Overall, 85 patients had precancerous lesions; 41.14% and 9.58% of cases showed low grade (CIN 1) and high grade (CIN 2 and 3) intraepithelial lesions, respectively. Our patients were young. However, no cases showed any cervical pathology before 20 years-old.

The 20-40 year-old age group comprised 35.5% of patients in this cohort. This finding corroborates with most studies, [1–3,16] which found precancerous lesions to affect women after the age of 25 years-old and cancers those over 60 years.

In developing countries, cervical cancer is diagnosed in advanced stages among women of young age. In a collaborative study on the diagnosis and treatment of cervical cancer, Chirenje et al [17] found that cancers of the cervix represent 80% of all admissions for gynecological cancers in several countries of eastern, central, and southern Africa, with a peak incidence at 45 years. More than 50% of patients have invasive cancer exceeding stage II or even stage III on admission.

This observation by Chirenje et al suggests that young patients aged under 50 years drive invasive cancer cases. Mutombo et al [18] also observed that 3878 cancers occur each year in the Democratic Republic of Congo, with an average age of less than 50 years. These results contrast with those from developed countries (and from our cohort) where cancer is a disease of those aged over 60 years; cervical cancer is therefore an older women disease in developed countries. [9,15]

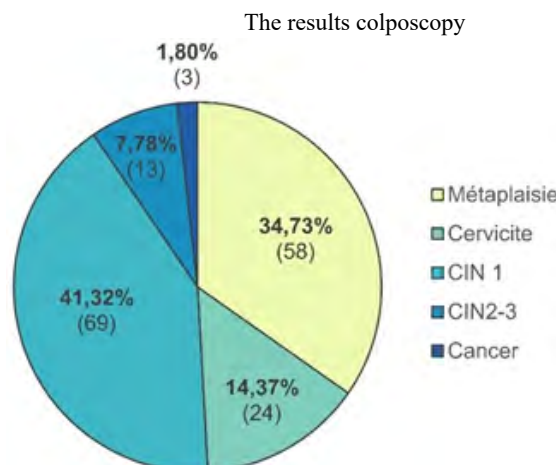


Figure 4: Diathermy electroresection

This cancer is on the rise in sub-Saharan Africa and aggravated by HIV. [15] The cervical cancer morbidity and mortality have decreased remarkably in developed countries where organized screening is performed. [15,16,19] Mboumba et al, [20] Okonofua et al, [21] Chirenje et al, [17] Moukassa et al, [16] Mutombo et al [18], and the WHO report the need to increase investment to diagnose and treat cervical cancer in developing countries, particularly in sub-Saharan Africa. Cervical pathologies prevention implies the vaccination against HPV coupled with sexually transmitted infections prevention towards young people via all information channels (press, social media, NGOs and television), particularly in all places used by this population including urban areas, churches, schools and universities. Lack of prevention and late diagnosis of these cervical lesions lead to invasive cancers.

Three therapeutic methods are usually used to treat precancerous lesions: [9] cryotherapy, LEEP, and cold conization. In our study, we used LEEP; it offers the indisputable advantage of removing affected cervical tissue in the form of a cone for histological evaluation. [16,19] This procedure is generally performed under local anesthesia on an outpatient basis in more than 95% of cases. [4] In our study, all patients were treated on an outpatient basis and 97% received local anesthesia. Described by Baggisch and advocated by Boulanger and Mergui [3,22], LEEP reduces the costs related to hospitalization, personnel, and equipment. [3–5,22] LEEP can be performed in technologically less-equipped and low income countries with just electricity supply, an electroresection probe and an electrocoagulation generator.

Our team, located in a developed country, has 4 operators: surgeon, dresser (operating theater nurse), anesthetist or nurse anesthetist supervised by the anesthetist, and occasionally one or two internship trainees.

All patients underwent satisfactory and complete resection with healthy margins and a 3-year cure rate of 98%. This result corroborates various studies. In 1984, Boulanger et al noted a success rate of 94%, [22] and in 1989, Prendiville et al obtained success in 95% cases. Mergui et al [23] reported a success rate of 97% in their cohort of 185 patients treated by electroresection; 171 (92.4%) patients had undergone sano resection.

Sano resection (in a healthy zone), which offers better results thanks to slightly larger electro cones adapted to the size of the lesions, is considered successful when the histological analysis demonstrates the operative margin to be away from the border of the cervical lesions; this technical improvement help colposcopists to perform electro resections offering a higher success rates (SFCPV congress of January 10, 2019) [24]. Superior quality colposcopy also offers good histological biopsy results with the possibility to avoid electroresection of immature metaplastic lesions which may be falsely interpreted as being atypical. In their study in Burkina Faso, [14] Milogo et al found that the LEEP specimen showed normal cervix histology in 20% cases; this proportion was considerably higher

than that reported in the literature. [1,2,5,8,22] In the young women planning group to become pregnant, the treatment of 20% of cases with a normal cervix appears to be excessive.

New generators, which deliver sectional high-frequency currents that do not carbonize the tissue, allow reliable pathological interpretation during LEEP performance. Successful LEEP depends on the height of the resection cone, passage in the healthy zone, no or few complications, and resection under colonoscopic control [8]. We did not use intraoperative or postoperative antibiotic therapy in the 15 resection procedures; follow-up for 4 years showed no cases of recurrence. CIN 2 lesions persisted in 2% of cases where resections were performed for high-grade lesions. In this context, the literature indicates a recurrence rate ranging from 2 to 5% depending on team expertise. [3,8,16,23]

Previous studies report a considerably low complication rate of less than 1% in patients treated with ECAD; as we observed no complications, this rate was slightly higher than ours.

Our complication rates contrast with those reported in the literature from Africa. The study performed in Burkina Faso by Milogo et al [14] found that 54.85% of 237 cases with precancerous lesions benefited from LEEP. The authors observed a complication rate of 63.8% with profuse bleeding in 26.5%, infection of the resection area in 26.5%, and hysterectomy for hemostasis. These outcomes may explain why cryotherapy is preferred in first instance in developing countries, particularly in sub-Saharan Africa. [7,25]

Cryotherapy advantage lies in an outpatient performance, without anesthesia, particularly in rural areas where medical follow-up is difficult. [7] The major drawback of this technique is the absence of histological analysis.

In a study of 21 cases treated by cryotherapy in Yaoundé, Ndoua et al [25] observed cure and late complications rates of 95.2% and 66.7%, respectively. Although bleeding and hydrorrhea were among the reported complications, stenosis was not observed. The authors do not specify whether high-grade CIN 2 or CIN3 lesions were treated using cryotherapy; however, they recommend the use of cryotherapy for treating all precancerous lesions.

In a study located in Abidjan, Aka and Coll [6] observed a significantly higher risk of recurrence with cryotherapy compared to LEEP (by 5.96%). This risk was more significant among women carrying HIV (by 2.85%).

Based on the WHO cryotherapy guidelines regarding cervical epithelial neoplasia, [15] cryotherapy is performed in women with CIN 1; these patients have low-grade lesions confirmed by histology and test positive on screening without histological confirmation. The expert group recognizes that ablation without histological confirmation is not very satisfactory. [15]

We do not use cryotherapy in our practice; CO2 laser is used instead for low and high grade lesions in developed country. The laser is particularly of interest concerning young women of childbearing

age because the majority of low-grade lesions are observed among them. This is currently accepted that low-grade lesions regress in 20% of cases; CO2 laser is indicated in persistent CIN 1 in young women with a well-visualized junction zone cases, which presupposes colposcopy with examination of the vagina.

The use of electrocoagulation to treat precancerous lesions appears to be as effective and less expensive than cryotherapy. Nevertheless, our study has certain limitations. First, the study had a retrospective design, and was conducted in France and not in a developing country where electricity supply can be a challenge. Second, the study was monocentric and performed by the same trained team. The patient proceeded through screening via the stages of FCV, HPV typing, colposcopy biopsy, LEEP, histological evaluation of the surgical specimen, and post operative follow-up. Finally, this study had a small sample size. And yet, we believe that the study, even modestly, help discover LEEP's strengths and advantages: a simple reproducible operative technique, with basic equipment, which can be performed on an outpatient basis under local anesthesia. Therefore, under-equipped countries such as sub-Saharan Africa ones can use LEEP with a trained personnel. In that study, the author has adapted techniques used in developed countries to developing countries.

A previous article published on gynecological endoscopy supports this observation. [26] The practice of endoscopic surgery was almost non-existent in sub-Saharan Africa in the 1990s. As the equipment was expensive, endoscopic surgery usefulness was questioned: technical platforms were obsolete, and there were significant risks of complications in the absence of trained key personnel. [26]. If performed by trained practitioners, operative complications from LEEP are expected to be considerably low; [1,2,9,22,27] as shown in the literature and our study. The risk-benefit ratio outcomes after complete excision of the lesion (in terms of progression to invasive cancer) meets the public health objective of cervical cancer morbidity and mortality reduction, and inverts the incidence curve.

6. Conclusion

Our study found that LEEP successfully treated high-grade precancerous lesions of the cervix without complications and recurrence for over 4 years. In light of the advantages of LEEP, it may be used as the initial treatment for all high-grade lesions in countries with low technology.

7. Disclosure

7.1. Ethics approval and informed consent

Dr. Olivier GONTIER, Resuscitator, Chairman of the Ethics Committee of the West Paris Private Hospital, allowed the publication of the results of the clinical study conducted by Dr. Olivier PAMBOU and his team after noting the protection of data and protocols of the establishment, including the patient's charter and the absence of conflicts of interest.

7.2. Competing Interests

The authors report no conflicts of interest in relation to this work.

7.3. Recommendations

LEEP technique trainings need to be organized for colposcopy trainers in reference centers in developing countries; WHO and UNDP, to be incorporated into programs designed to fight cervical cancer.

7.4. Consent for the Publication

Patients have given their informed consent for the publication of their case details and accompanying images.

References

- Bergeron C, Ordi J, Schmidt D, Trunk MJ, Keller T, Ridder R, et al. Conjunctive p16INK4a testing significantly increases accuracy in diagnosing high-grade cervical intraepithelial neoplasia. *Am J Clin Pathol.* 2010; 133(3): 395-406.
- Richart RM. A modified terminology for cervical intraepithelial neoplasia. *Obstet Gynecol.* 1990; 75(1): 131-3.
- Mergui JL, Tauscher P, Bergeron C, Pambou O, Salat-Baroux J. [Electro-conization with the diathermic loop. Indications and results]. *Contracept Fertil Sex* 1992. 1994; 22(1): 53-9.
- Mergui JL, Tauscher P, Bergeron C, Pambou O, Salat-Baroux J. Therapeutic strategy for dysplastic cervical lesions. *Bichat IntError! Hyperlink reference not valid. erviews.* 1993; 108-15.
- Masson E. La conisation à l'anse diathermique. *EM-Consulte.* 2022.
- Aka KE, Horo A, Koffi A, Fanny M, Diassana M, Kone M. [Recurrences of precancerous lesions after conservative treatment: Operational results after a decade in Abidjan]. *Gynecol Obstet Fertil Senol.* 2021; 49(2): 107-11.
- WHO. Lignes directrices de l'OMS : utilisation de la cryothérapie pour le traitement de la néoplasie cervicale intraépithéliale. 2022.
- Carcopino X. Optimiser le traitement des lésions intra épithéliales de haut grade du col utérin par résection a l'anse diathermique grâce à la colposcopie | *Gynéco Online.* 2022.
- L'Institut national du cancer (INCa). Synthèse/ Surveillance post Thérapeutique des lésions du col de l'utérus. 2019. e-cancer.fr.
- Brun JL, Youbi A, Hocke C. Complications, séquelles et devenir du col traité par conisation : évaluation à travers 3 techniques opératoires. *J Gynécologie Obstétrique Biol Reprod.* 2002; 1090(6): 527.
- Baldauf J-J, Baulon E, Thoma V, Woronoff A-S, Akladios CY. [Obstetric outcomes following LOOP-excision]. *J Gynecol Obstet Biol Reprod (Paris).* 2013; 42(6): 534-40.
- Arbyn M, Redman CWE, Verdoodt F, Kyrgiou M, Tzafetas M, Ghaem-Maghani S, et al. Incomplete excision of cervical precancer as a predictor of treatment failure: a systematic review and meta-analysis. *Lancet Oncol.* 2017; 18(12): 1665-79.
- Demarquet E, Mancini J, Preaubert L, Gondry J, Chevreau J, Lamblin G, et al. Risk Factors of Post-Large Loop Excision of the Transformation Zone Recurrent High-Grade Cervical Intraepithelial Lesion: A Prospective Cohort Study. *J Low Genit Tract Dis.* 2019; 23(1): 18-23.

14. Traore TM. Prise En Charge Des Lésions Precancereuses Du Col Uterin Par La Resection A L'anse Diathermique Au Centre Hospitalier Universitaire Yalgado Ouedraogo: Bilan De Huit Mois D'activite. *J Sago Gynécologie–Obstétrique Santé Reprod.* 2017; 18(1).
15. WHO. Global Projections of mortality and causes of death, 2015 and 2030. 2022.
16. Moukassa D, N'Golet A, Lingouala LG, Eouani ML, Samba JB, Mambou JV, et al. [Precancerous lesions of the uterine cervix in Pointe-Noire, Congo]. *Med Trop Rev Corps Sante Colon.* 2007; 67(1): 57-60.
17. Chirenje ZM, Rusakaniko S, Kirumbi L, Ngwalle EW, Maku-ta-Tlebere P, Kaggwa S, et al. Situation analysis for cervical cancer diagnosis and treatment in east, central and southern African countries. *Bull World Health Organ.* 2001; 79(2): 127-32.
18. Mutombo Baleka A. Cervical cancer control and prevention strategies in a low-resource setting. 2019.
19. BABA Samake. Precancerous lesions of the cervix at the CsRef of the commune of the district of Bamako Thesis 2010 Faculty of Medicine University of Bamako. 2010.
20. Mboumba Bouassa RS, Prazuck T, Lethu T, Meye JF, Bélec L. Cervical cancer in sub-Saharan Africa: an emerging and preventable disease associated with oncogenic human papillomavirus. *Med Sante Trop.* 2017; 27(1): 16-22.
21. Okonofua F. Preventing and Controlling Cervical Cancer in Africa: A Call for Action. 2015.
22. Boulanger CM, Vanhoutte PM. Vasomotricité d'origine endothéliale. Rôle des protéines G. *Sang Thromb Vaiss.* 1997; 9(1): 22-30.
23. Mergui J-L, Sananes S, Pambou O, Foulques H, Salat-Baroux J. Traitement des lésions intra-épithéliales du col et du vagin. *Reprod Hum Horm.* 1995; 8(7): 417-28.
24. 42e Congrès National de la SFCPCV du 11 et 12 janvier 2019 | Gynéco Online. 2022.
25. Ndoua C, Tebeu PM, Kemfang JD, Kasia JM. Evaluation des résultats après traitement des lésions intra épithéliales du col utérin par la cryothérapie: étude préliminaire au Centre Hospitalier Universitaire de Yaoundé: A propos de 21 cas. *Pan Afr Med J.* 2015; 20(1).
26. Pambou O, Guyot B, Antoine JM, Salat-Baroux J. [Endoscopic gynecologic surgery in Africa. Luxury of necessity?]. *Rev Fr Gynecol Obstet.* 1995; 90(3): 174-7.
27. Sauvaget C, Muwonge R, Sankaranarayanan R. Meta-analysis of the effectiveness of cryotherapy in the treatment of cervical intraepithelial neoplasia. *Int J Gynaecol Obstet Off Organ Int Fed Gynaecol Obstet.* 2013; 120(3): 218-23.