

## Vaginal Myomectomy for a Large Cervical Myoma: Case Report and Literature Review

Ribeiro SECC\*, Bittencourt CA, Vanni D, Miyahara CBDF, Helito ALTP, Assumpcao MSD and Baracat EC Department of Medicine, University of Sao Paulo, Brazil

Volume 1 Issue 6- 2019

Received Date: 28 Mar 2019

Accepted Date: 08 Apr 2019

Published Date: 18 Apr 2019

### 1. Abstract

**1.1. Introduction:** The uterine leiomyoma is the most common pelvic tumor in women. The pathogenesis is considered multifactorial. They are usually asymptomatic, but may cause uterine bleeding, infertility, recurrent fetal loss and abdominal pain. As symptoms attend do be directly related to their size, number and location, treatment should be individualized.

**1.2. Goal:** The objective of the present study is to review current literature and report the case of a patient wishing to conceive who underwent laparoscopic assisted vaginal myomectomy for a large cervical myoma

**1.3. Methodology:** The search was performed using the descriptors “cervical myoma” and “vaginal myomectomy”. In the PUBMED database, of the 23 articles found, 4 were related to the theme and 2 recovered.

**1.4. Discussion:** Most of the studies evaluated cases of vaginal myomectomy by anterior and pos-terior colpotomy or by laparoscopy. The present study reports a case laparoscopy assisted vaginal myomectomy for a large cervical myoma. Anterior or posterior colpotomy were not necessary. **1.5. Conclusion:** Laparoscopic assisted vaginal myomectomy is a tactical option in selected cases and should be considered as a surgical alternative to hysterectomy in patients who wish to con-ceive, even in cases of large-volume fibroids.

### 2. Introduction

The uterine leiomyoma is the most common pelvic tumor in women. It can occur in up to 70% of women. It is clinically apparent in 25% of women in reproductive age [1]. The pathogenesis is considered multifactorial [2]. It is usually asymptomatic, but may provoke increased uterine bleeding, infertility, recurrent fetal loss and abdominal pain [3]. The symptoms are directly related to the size, number and location of the myomas [4], and treatment should be individualized. Treatment is clinical or surgical, depending on age, desire for future pregnancy, symptoms, size and location of myomas. In patients with plans to conceive the preference is for myomectomy over hysterectomy, and several surgical techniques are available. The present study reports the case of a patient wishing to conceive who underwent laparoscopic assisted vaginal myomectomy for a large cervical

myoma. Follows a bibliographic review on the surgical treatment of cervical fibroids.

### 3. Goal

The objective of the present study is to present the case of a patient who underwent laparoscopic assisted vaginal myomectomy for a large cervical myoma and to review the surgical treatment of cervical fibroids.

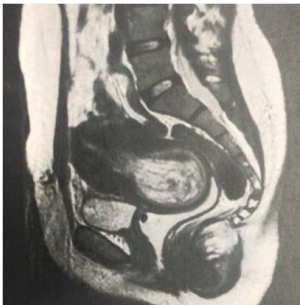### 4. Methodology

The literature review in Pubmed database using the descriptors “cervical myoma” and “vaginal myomectomy” yielded twenty-three articles. Only four were related to the theme and two were available. The authors declare no conflict of interest. The patient signed a term of consent for the case report and use of images.

\*Corresponding Author (s): Sergio Edgar Camoes Conti Ribeiro, Department of Medicine, University of Sao Paulo, Brazil, Fax: (5511) 3079-5050; Tel: (5511) 3079-5050; E-mail: sergiocontiribeiro@terra.com.br

## 5. Case Report

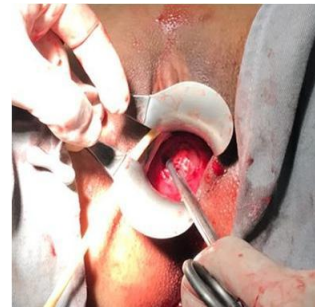A forty-year-old healthy woman with one previous cesarean-section and one spontaneous abortion presented with abnormal uterine bleeding and dysmenorrhea. She had undergone an open myomectomy the previous year, but maintained increased uterine bleeding, associated with anemia requiring blood transfusion. She responded poorly to clinical treatment with combined oral contraceptives, progestins and non-steroid anti-inflammatories. Diagnostic hysteroscopy revealed a type II submucous myoma with two centimeters, occupying the entire uterine cavity, emerging from the right anterolateral wall. The uterus Pelvic Magnetic Resonance Imaging was in anteversion and measured 104x60x59 mm. The study evinced a 16 mm submucosal myoma and a solid intra-uterine expansive formation measuring 67x52x51mm, located in the isthmus-corporeal transition, extending to the uterine cavity (**Figure 1**). Upon physical examination, it was possible to visualize the myoma through the external orifice of the cervix.



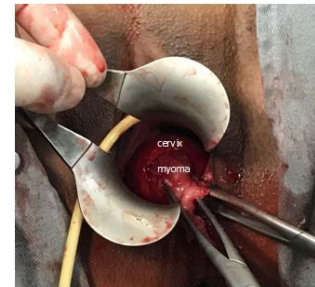**Figure 1:** Pelvic MRI. Sagittal T2 weighted images at midsagittal plane showing a pelvic mass with heterogeneous low signal inside the cervix, without clear invasion of adjacent pelvic structures.

The patient was submitted to a laparoscopy assisted vaginal myo-mectomy. We visualized the fibroid at the level of the external orifice of the uterine cervix, clamped it and combined torsion and traction until its complete withdrawal. With the dilated cervix, a submucous myoma was identified on the uterine fundus, clamped and removed likewise. Laparoscopic vision ensured the security of the procedure, in case of uterus perforation. The mass measured 6,8 x 5,0 x 3,5 cm. The final histopathological examination confirmed the diagnosis of uterine leiomyoma. The operation lasted about 120 minutes and there was no need for blood transfusion (**Figure 2 and 3**). The patient was discharged 24 hours after surgery, asymptomatic and without complications during hospitalization. She was reassessed on an outpatient basis twice, six and thirty days after surgery. On her last visit, she was asymptomatic, had no vaginal bleeding and a closed cervix (**Figure 4 and 5**).

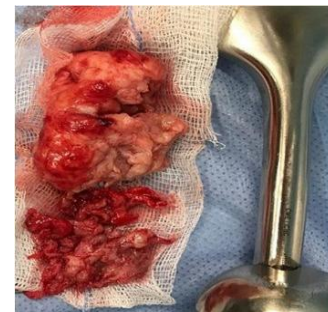
After the three months of surgery, control imaging revealed full recovery. hysteroscopy showed a uterine cavity with no abnormalities and Pelvic Magnetic Resonance Imaging was normal (**Figure 6**). She was then released for sexual activity and attempt at pregnancy.



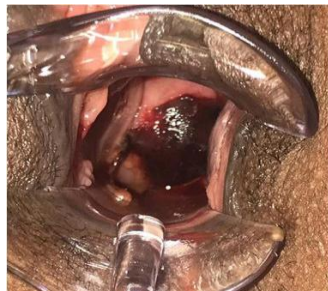**Figure 2:** Intraoperative images: myoma visualized at the level of the external orifice of the uterine cervix.



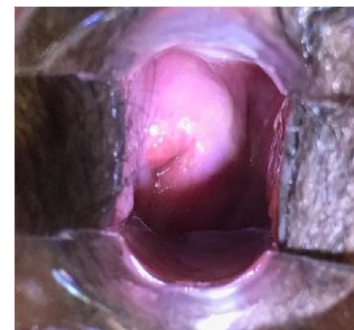**Figure 3:** Removed uterine leiomyoma.



**Figure 4:** Physical examination on the 6th day after surgery.



**Figure 5:** Physical examination on the 30th day after surgery.



**Figure 6:** RNM pos.

## 6. Discussion

Davies et al. [5] described in 1999 35 cases of vaginal myomectomy through anterior and posterior colpotomy. Subsequently, Faivre et al. [6] published a review on the topic and evaluated cases of excision of uterine fibroids by anterior and posterior vaginal wall incision. Rolli et al. [7] published in 2012 a retrospective study of 46 cases of vaginal myomectomy via posterior colpotomy. In these three studies, no surgical approach similar to the one described in this report was performed.

Terzic et al. [8] reported a case of vaginal myomectomy for a pediculated submucous myoma, showing that even large volume fibroids can be successfully removed vaginally. This report was somewhat similar in approach to this present study, yet no concomitant laparoscopy was performed. Peker et al. [9] reported a similar case in 2016 using laparoscopy to assist the treatment of a large prolapsed fibroid.

Birsan et al. [10] published in 2003 a pilot study involving 24 patients with single symptomatic uterine fibroids, aimed at comparing the feasibility and complications of vaginal and laparoscopic myomectomy. Conversion to laparoscopy was required in one nulliparous patient undergoing vaginal myomectomy for a fundal fibroid, as it proved inaccessible intra-operatively through the vaginal approach. This study suggests that vaginal myomectomy should be restricted to myomas located on the posterior uterine wall. Contrary to this study, the present report shows that it is possible, in selected cases, to safely remove anterior wall fibroids vaginally using laparoscopy to increase safety.

Pelosi's [11] in 1997 and Goldfarb [12] in 2001 described their procedures, in which the dominant myoma was removed laparoscopically, and the uterus was delivered - via colpotomy - into the vagina for removal of secondary uterine myomas and uterine closure.

Most studies have evaluated cases of vaginal myomectomy via anterior and posterior colpotomy or via laparoscopy. The present study reports a case of laparoscopy assisted vaginal myomectomy for a large cervical myoma without anterior or posterior colpotomy. We believe that laparoscopy adds safety to the surgical procedure, allowing wide visualization of the pelvis and adjacent organs, and hence prevention, identification and treatment of possible associated complications

## 7. Conclusion

Laparoscopy assisted vaginal myomectomy may be a surgical option in selected cases. It is an alternative to hysterectomy in patients with conception plans, even for large-volume fibroids. Laparoscopy adds safety to the surgical procedure as it allows wide visualization of the pelvis, blood vessels and adjacent or-

gans. It permits the identification and treatment of possible complications associated with an exclusively vaginal approach. More studies are needed to compare the techniques and postoperative outcomes

## References

1. Stewart EA, Cookson CL, Gandolfo RA, Schulze-Rath R. Epidemiology of uterine fibroids: a systematic review. *BJOG*. 2017; 124: 1501 - 1512.
2. Vlahos NF, Theodoridis TD, Partsinevelos GA. Myomas and Adeno-myosis. Impact on Reproductive Outcome Review Article. *BioMed Research International*. 2017.
3. AAGL Practice Report: Practice Guidelines for the Diagnosis and Management of Submucous Leiomyomas. *Journal of Minimally Invasive Gynecology*. 2012.
4. Corleta HVE, Chaves EBM, Krause MS, Capp E. Tratamento atual dos miomas. *Rev Bras Ginecol Obstet*. 2007; 29(6): 324 - 8.
5. Davies A, Hart R, Magos AL. The excision of uterine fibroids by vaginal myomectomy: a prospective study. *Fertil Steril*. 1999; 71(5): 961 - 4.
6. Faivre E, Surroca MM, Deffieux X, Pages F, Gervaise A, Fernandez H. Vaginal Myomectomy: Literature Review. *J Minim Invasive Gynecol*. 2010 Mar-Apr;17(2):154 - 60.
7. Rolli R, Favilli A, Acanfora MM, Scuderi G, Renzo GC, Gerli S. Vaginal myomectomy is a safe and feasible procedure: A retrospective study of 46 cases. *J Obstet Gynaecol Res*. 2012; 38(9): 1201 - 5.
8. Terzic M, Maricic S, Dotlic J. Vaginal Removal of Very Large Nascent Uterine Myoma - Case Report and Literature Review. *Geburtshilfe Frau-enheilkd*. 2013; 73(7): 724 - 726.
9. Peker N, Gundogan S, Sendag F. Laparoscopic management of huge myoma nascendi *The Journal of Minimally Invasive Gynecology* (2016)
10. Birsan A, Deval B, Detchev R, Poncelet C, Darai E. Vaginal and laparoscopic myomectomy for large posterior myomas: results of a pilot study. *Eur J Obstet Gynecol Reprod Biol*. 2003; 110(1): 89 - 93.
11. Pelosi III MA, Pelosi MA. Laparoscopic-Assisted Transvaginal Myomectomy *The Journal of the American Association of Gynecologic Laparoscopists* February 1997, Vol. 4, No. 2
12. Goldfarb HA, Fanarjian NJ. Laparoscopic-Assisted Vaginal Myomectomy: A Case Report and Literature Review. *JSLs*. 2001 Jan-Mar; 5(1): 81 - 5.