

Dieulafoy's Lesion, A Rare But Potentially Fatal Cause of Gastrointestinal Bleeding Treated With Repeated Therapeutic Gastrosopies : A Case Report

Gambardella D^{1,3*}, Schicchi AA², Luigino Borrello L³, Maria Teresa Caruso MT⁴ and Tedesco M³

¹Department of Medical and Surgical Sciences, University of Catanzaro, Catanzaro, Italy

²Operative Unit of Endoscopy (Director Dr. A.A. Schicchi), "Giovanni Paolo II" Hospital, Lamezia Terme, Italy

³Operative Unit of General Surgery (Director Dr. M. Tedesco), "Giovanni Paolo II" Hospital, Lamezia Terme, Italy

⁴Medical Intensive Care Unit, "G. Paolo II Hospital", Lamezia Terme, Italy

*Corresponding author:

Gambardella Denise,
Department of General Surgery,
"G. Paolo II Hospital",
and Department of General Surgery University of
Catanzaro, Italy,
E-mail: gambardelladenise@gmail.com

Received: 01 Nov 2020
Accepted: 16 Nov 2020
Published: 20 Nov 2020

Copyright:

©2020 Gambardella D et al. This is an open access article distributed under the terms of the Creative Commons Attribution License, which permits unrestricted use, distribution, and build upon your work non-commercially.

Citation:

Gambardella D, Dieulafoy's Lesion, A Rare But Potentially Fatal Cause of Gastrointestinal Bleeding Treated With Repeated Therapeutic Gastrosopies : A Case Report. Clinics of Surgery. 2020; 4(1): 1-5.

1. Abstract

1.1. Introduction: Dieulafoy's lesion (DL) is an uncommon but important cause of recurrent upper gastrointestinal bleeding. Advances in endoscopy have increased the detection rate of Dieulafoy's lesions and have significantly decreased the mortality. Surgical resection was historically the first-line treatment of Dieulafoy's lesions, usually taking the form of gastrotomy and wide-wedge resection or gastrectomy. This has now been overtaken by advances in endoscopic procedures. Surgical resection is currently reserved for the cases that are refractive to endoscopic or angiographic methods.

1.2. Materials and Methods: we report a case of A 60-year-old male was admitted to our operative unit for a recurrent acute gastrointestinal bleeding hematemesis and melena. He had history of high blood pressure and abuse of NSAIDs. An upper endoscopy revealing a protrusion on the greater curvature just 5 cm below the cardia. The patient underwent four gastrosopies and only the last one was successful in ensuring hemostasis.

1.3. Results: The post-operative period was uneventful and he was discharged seven days after the procedure. The follow-up visit 6 months later showed no complications due to the therapy and no extravasations, ulcerations or any other hemostatic disorders.

1.4. Conclusion: Dieulafoy's can be successfully managed by endoscopic treatment. Endoscopic hemostasis with combined approaches can be repeated before resorting to surgical resection.

2. Introduction

Dieulafoy's lesion (DL) also defined as exulceratio simplex, cirroid aneurysm or caliber-persistent submucosal vessel) is an unusual but important and potentially life threatening cause of gastrointestinal bleeding responsible for up to 5% of acute upper gastrointestinal bleeds [1-3]. The endoscopic modalities for control of bleeding is the first choice of treatment of the lesion, but often the hemostasis is not possible [4]. Angiographic embolization can also be used for therapeutic purposes in patients in whom endoscopic treatment has failed or surgery is contraindicated [5]. A potential emerging approach is EUS-guided therapy [6].

Surgical management is indicated when the lesion fails to respond to therapeutic endoscopy. The endoscopic modalities for control of bleeding is the first choice of treatment of the lesion, but often the hemostasis is not possible. Emergency surgery after the failure of 'surgical endoscopy, and haemodynamic instability status, is the only choice to solve the bleeding [4]. We describe the case of a patient with recurrent episodes of hematemesis, subjected to 4 egds of which only the last was found to be effective in controlling

hemostasis avoiding the surgical treatment that would have consisted of a total gastrectomy for the position of Dieulafoy lesion.

3. Case Report

A 60-year-old Italian man was admitted to a regional hospital with massive hematemesis and melena. Prior to admission, he had lunch. He was well until he experienced an episode of hematemesis. He had a story of hypertension, and presented in week before intermittent episodes of melena a fever and persistent cough for 7 days treated with antibiotic therapy and non-steroid anti-inflammatory drugs without benefit. There was no history of acid peptic disease, drugs intake, chronic liver disease, or antiplatelet or anticoagulant drugs. He arrived at emergency room with hypotension, severe pallor and tachycardia, and an important hematemesis. On physical examination, he was pale, with a temperature of 37.9°C, a pulse rate of 120 beats per minute, and a blood pressure of 90/52 mmHg. An abdominal examination was unremarkable, and no neurological abnormalities were noted. His laboratory results showed a marked anemia (Hb; 7,5 g/dl) with leukocytosis (16.000/mm³). A blood coagulation test result was also normal. He performs ECG and chest X-ray showing a pneumonic focal thickening in the upper right lobe. He performs the first emergency EGDS examination that reports only the presence in the stomach of modest blood stagnation of digested blood without signs of bleeding in progress. Therefore, a diagnosis of acute hemorrhagic NSAID abuse gastritis was made. He was admitted to the medical department, He was managed conservatively with H₂ blockers, intravenous fluids, kept nil by mouth and blood transfusion. However, during hospitalization, he developed another massive hematemesis; he was subsequently transferred to our department. On admission in our department, his Hb had decreased to 6.0 g/dl. Blood His rapidly progressive anemia associated with massive hematemesis indicated the presence of an active bleeding in his upper GI tract. We performed the second emergency gastroscopy. During gastroscopy were observed fresh blood and a large live clot which did not allowed, despite the patient's change position, the evaluation of part of the body and gastric fundus, without visible signs of bleeding despite numerous washes of the gastroduodenal wall. The SNG is repositioned by washing with hot water through the tube and administration of anti-emetic e.v. with repetition of gastroscopy after two hours. After two hours, the patient undergoes a new gastroscopy in which for the first time it is evident at the level of the bottom-gastric passage along the large curve, a small clot adhered to an area of eroded mucosa (3mm), performs infiltration, first perilesional and then intralesional of adrenaline 1: 10: 000 (15cc); no clip is placed for the tangential position of the lesion. This lesion is probably related to Dieulafoy's vascular lesion. The patient continued supportive medical therapy until the hemoglobin values and vital parameters stabilize after 4

days of hospitalization is discharged with diagnosis of digestive haemorrhage from Dieulafoy vascular lesion. After about three days the patient returned to medical observation for several episodes of hematemesis and severe anemia. His laboratory exams were: hemoglobin 5.5g/dL, Hematocrit 22%, Other hematological and biochemical investigations were within normal limits and he was hospitalized. After resuscitation therapy with fluids, plasma and blood infusion, a surgical consultation was required to evaluate the surgical treatment. After a careful evaluation of the patient's case of his comorbidities and of his clinical history, given the cause of gastric bleeding of a benign but recurrent nature as a Dieulafoy lesion present on the gastric fund previously treated only with perilesional injection of adrenaline, we decide to try again urgently endoscopic treatment trying a mechanical hemostasis. The stomach showed signs of recent bleeding with a large clot of the body-bottom passage; the clot is removed after repeated washing and exposure of the previously described DL positioned at the bottom-body passage on the great curvature. Endoscopic hemostasis was performed by: infiltration of cyanoacrylate, subsequent mechanical hemostasis with the addition of three clips and perilesional infiltration of adrenaline 1: 10,000 (6cc) (Figure a, b and c). The patient at the end of the procedure was hospitalized at the U.O. of General Surgery, Following endoscopic hemostasis, he was initiated on an intravenous proton pump inhibitor, Sondostatin, blood trasfusion, and plasma administration based on blood chemistry parameters. The patient underwent fasting therapy for 72h, and closely monitored the PA of CF every 3 hours for the first 24h. The postoperative course was smooth and uncomplicated. The patient is discharged after 7 days of hospitalization. Close endoscopic follow-up was also recommended. The patient was reassessed at three and six months with endoscopic control, no other acute bleeding episodes have occurred at the time (Figure d).

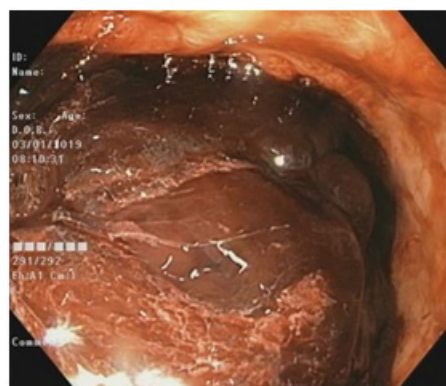


Figure a: Severe bleeding from Dieulafoy's lesion and presence of a large clot occupying the gastric lumen.

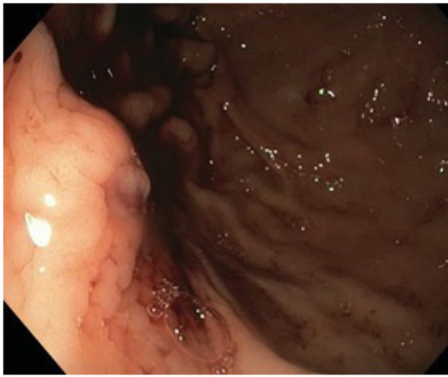


Figure b: A blood vessel protruding into the gastric lumen without surrounding ulceration consistent with Dieulafoy's lesion

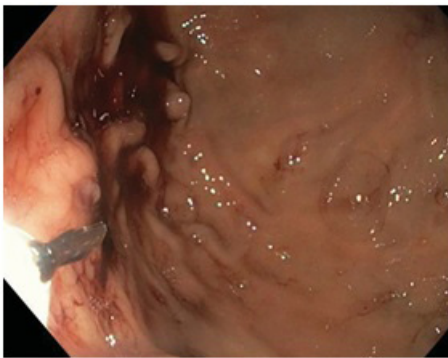


Figure c: Endoscopic haemostasis with perilesional infiltration of adrenaline 1: 10,000 (6cc).

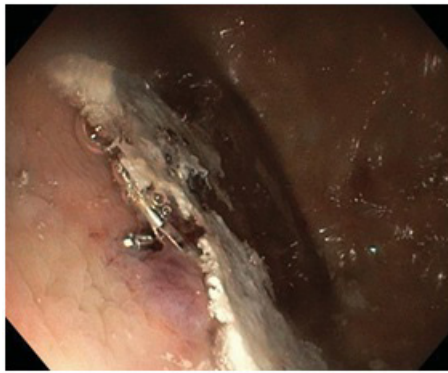

Figure d: Endoscopic haemostasis by means of: infiltration of cyanoacrylate, subsequent mechanical haemostasis with the apposition of three metal clips.

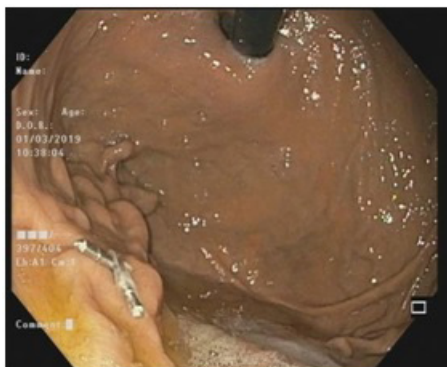


Figure e: Endoscopic follow-up at three months.

4. Discussion

The incidence of acute gastrointestinal bleeding ranges from 50 to 150 per 100,000 of the population each year. It is caused by peptic ulcers and esophageal or gastroduodenal erosions in nearly 80% of patients [7]. Dieulafoy's lesion is a rare and severe case of gastrointestinal bleeding, however, it is not always diagnosable [8, 9]. Histologically it is a normal vessel that has an abnormally large diameter, maintaining a constant width of 1–3 mm that runs inside the submucosa [10]. The incidence and etiology are still uncertain, [11, 12]. There is a common patient profile observed from the various case studies, i.e. male patients with a mean age of 54 years [13-14] with cardiopulmonary comorbidities and chronic renal failure [16]. The stomach is the most common site for Dieulafoy lesion. Mucosal defect most commonly occurs on the minor curve within 6 cm of the gastroesophageal junction [14-17]. However, lesions have been identified throughout the gastrointestinal tract from the esophagus to the anal canal and also of the bronchus. [18, 19, 20]. The most common presenting symptom of DL is hematemesis, often massive [21]. DL is usually diagnosed by endoscopic examination, which reveals a pigmented bump from the vessel stump, with minimal surrounding erosion and no ulceration with or without active bleeding or oozing of blood from a tiny point source on the gastrointestinal mucosa [22, 23]. Sometimes repeated gastroscopies are necessary before reaching the definitive diagnosis [24]. From some recent cases the DL can be identified at the first emergency gastroscopy up to 96% of the time [25], this is because most of the time the EGDS they are performed during the active phase of bleeding [26]. Gastroscopy allows hemostasis to be achieved in 93.6% of cases, with a relapse rate of 12.1% [27, 28]. The introduction and improvement of endoscopic techniques have greatly reduced the need to have to resort to surgery, bringing mortality from 80% to 8.6% [17]. Therapeutic gastroscopy is the primary modality of choice in the early stage treatment of Dieulafoy lesion [26]. Therapeutic interventions during gastroscopy consist of: electrocoagulation, sclerotherapy, laser therapy, adrenaline injection, mechanical "clipping" [26]. The adrenaline injection has been used in combination with the other types of treatment reported since, it allows a better visualization of the gastric mucosa and the achievement of therapeutic success [29]. Combined endoscopic therapies are reported to have lower re-bleeding rate when compared to endoscopic monotherapy [16, 30]. Therapeutic gastroscopy allows complete and permanent hemostasis to be achieved in 85% of cases. In 15% of cases in which bleeding occurs, gastroscopic treatment can be retried. In 10% can be successfully treated by repeating therapeutic gastroscopy while 5% require definitive surgery [21]. A potential emerging approach is EUS-guided therapy in patients with refractory gastrointestinal bleeding who have failed standard clip, adrenaline and coagulation treatment. This approach has been used to confirm endoscopic hemostasis of DL bleeding, demonstrating no blood flow after

therapy [4]. Angiographic embolization can also be used for therapeutic purposes in patients in whom endoscopic treatment has failed or surgery is contraindicated [31, 32, 5]. Surgical resection was historically the first-line treatment of Dieulafoy's lesions, and consisted of a gastrotomy and wide-wedge resection or gastrectomy. With the advancement of technologies in the endoscopic field, surgical resection is currently reserved for the 5% of cases that are refractive to endoscopic or angiographic methods. Laparoscopic surgery is an attractive option for treating these lesions as it offers a cure while being minimally invasive to the patient. However, successful laparoscopic resection relies on accurate pre-operative or intra-operative localization of the bleeding with clips or tattoo [33].

5. Conclusion

The endoscopic modalities for control of bleeding is the first choice of treatment of the lesion, but often the hemostasis is not effective. We suggest to repeat hemostasis with egds and above all to perform combined approaches before performing a surgery that could consist of a wedge resection or in cases where the lesions is situated within 6 cm of the gastro-esophageal junction a total gastrectomy. a total gastrectomy could be an over treatment for a cause of benign gastric bleeding as DL.

References

- Sciumè C, Di Vita G, Geraci G, Pisello F, Modica G. Dieulafoy's ulcer: unusual cause of upper gastrointestinal tract. Our experience. *Ann Ital Chir.* 2001; 72(2): 233-6.
- Schietroma M, Cecilia EM, De Santis G, Carlei F, Pessia B, Amicucci G. Supplemental Peri-Operative Oxygen and Incision Site Infection after Surgery for Perforated Peptic Ulcer: A Randomized, Double-Blind Monocentric Trial. *Surg Infect (Larchmt).* 2016; 17(1): 106-13.
- Sista F, Abruzzese V1, Schietroma M. Concomitant gastrointestinal stromal tumor of the stomach and gastric adenocarcinoma in a patient with billroth 2 resection. *Case Rep Surg.* 2013; 2013: 583856.
- Beatrice P, Lucia R, Antonio G, Domenico G, Mario S, Francesco C, Renato P. Rare case of upper gastrointestinal bleeding: Dieulafoy's lesion of duodenum. A case report. *Ann Med Surg (Lond).* 2019; 45: 19-21.
- P O Katz 1, L Salas. Less frequent causes of upper gastrointestinal bleeding. *Gastroenterol Clin North Am.* 1993; 22(4): 875-89.
- Hall PSJ, Teshima C, May GR, Mosko JD. Endoscopic Ultrasound-Guided Vascular Therapy: The Present and the Future. *Clin Endosc.* 2017; 50(2): 138-142.
- British Society of Gastroenterology Endoscopy Committee. Non-variceal upper gastrointestinal haemorrhage: guidelines. *Gut.* 2002; 51: iv1-6.
- H J Streicher. Solitary exulceratio simplex (Dieulafoy) as cause of massive intestinal hemorrhage] *Dtsch Med Wochenschr.* 1966; 91(21): 991-5.
- R Margreiter, S Weimann, L Riedler, K Schwamberger. [The Dieulafoy's ulcer (author's transl)] *Leber Magen Darm.* 1977; 7(6): 353-6.
- Dieulafoy G. *L'exulceratio simplex.* Manuale de Pathologie Interne. Masson, Paris, 1908.
- H V CORNELIUS. Pathogenesis of so-called solitary gastric erosion, Dieulafoi. *Frankf Z Pathol.* 1952; 63(4): 582-8.
- Goldman RL. Submucosal arterial malformation (aneurysm) of the stomach with fatal haemorrhage. *Gastroenterology.* 1964; 46: 589-594.
- Veldhuyzen V, Bartelman J, Schipper M, et al. Recurrent massive haematemesis from Dieulafoy vascular malformation: a review of 101 cases. *Gut.* 1986; 27: 213-222.
- Rossi N, Green EW, Pike JD. Massive bleeding of the upper gastrointestinal tract due to Dieulafoy erosion. *Arch Surg.* 1968; 97: 797-80.
- Saur K. Die solitare Exulceratio simplex (Dieulafoy) als Ursache einer schweren akuten Magenblutung. *Chirurg.* 1973; 44: 293-299.
- Lee YT, Walmsley RS, Leong RWL, Sung JY. Dieulafoy's lesion *Gastrointest Endosc.* 2003; 58(2): 236-43.
- Baxter M, Aly EH. Dieulafoy's lesion: current trends in diagnosis and management. *Ann R Coll Surg Engl.* 2010; 92(7): 548-54.
- Regula J, Wronska E, Pachlewski J. Vascular lesions of the gastrointestinal tract. *Best Pract Res Clin Gastroenterol.* 2008; 22(2): 313-28.
- Alshumrani G, Almuaikeel M. Angiographic findings and endovascular embolization in Dieulafoy disease: a case report and literature review. *Diagn Intervent Radiol.* 2006; 12: 151-4.
- Gharagozloo F, Rennert D, Margolis M, Tempesta B, Schwartz A, Cole V, Wang KP. Dieulafoy lesion of the bronchus: Review of the literature and report of the 13th case *Journal of Bronchology and Interventional Pulmonology.* 2008; 15(1): 38-40.
- Reilly HF, Al-Kawas FH. Dieulafoy lesion: diagnosis and management. *Dig Dis Sci.* 1991; 36: 1702-07.
- Chaer RA, Helton WS. Dieulafoy's disease. *J Am Coll Surg.* 2003; 196(2): 290-6.
- Rana S, Bhasin DK, Gupta R, Yadav TD, Gupta V, Singh K. Periampullary Dieulafoy's lesion: an unusual cause of gastrointestinal bleeding. *JOP.* 2010; 11: 266-269.
- Poma YJ, Guardado AV, Pérez CP, et al. Prognostic factors for recurrence of gastrointestinal bleeding due to Dieulafoy's lesion. *World J Gastroenterol* 2012; 18(40): 5734-38.
- Baettig B, Haeckel W, Lammer F, Jost R. Dieulafoy's disease: endoscopic treatment and follow up. *Gut.* 1993; 34: 1418-21.
- Parra Blanco A, Takahashi H, Mendez Jerez PV et al. Endoscopic management of Dieulafoy lesions of the stomach: a case study of 26 patients. *Endoscopy.* 1997; 29(9): 834-9.
- Nguyen DC, Jackson CS. The Dieulafoy's Lesion: An Update on Evaluation, Diagnosis, and Management. *J Clin Gastroenterol.* *J Clin Gastroenterol.* 2015; 49(7): 541-9.
- Park JG, Park JC, Kwon YH, Ahn YS, Seong SW. Endoscopic Man-

- agement of Rectal Dieulafoy's Lesion: A Case Series and Optimal Treatment. *Clin Endosc.* 2014; 47(4): 362-6.
29. Stark ME, Gostout CJ, Balm RK. Clinical features and endoscopic management of Dieulafoy's disease. *Gastrointest Endosc.* 1992; 38(5): 545-50.
 30. Marangoni G, Cresswell AB, Faraj W, Shaikh H, Bowles MJ. An uncommon cause of life-threatening gastrointestinal bleeding: 2 synchronous Dieulafoy lesions. *J Pediatr Surg.* 2009; 44(2): 441-3.
 31. Helliwell M, Irving JD. Haemorrhage from gastric artery aneurysms. *Br Med J (Clin Res Ed).* 1981; 282(6262): 460-1.
 32. Jaspersen D, Gaster CB, Koerner TH, Hammar CH. Doppler controlled injection treatment of Dieulafoy's disease. *J Gastroenterol Hepatol.* 1993; 8(3): 267-9.
 33. Alva S, Abir F, Tran D. Laparoscopic gastric wedge resection for Dieulafoy's disease following pre-operative endoscopic localisation with India ink and endoscopic clips. *J Soc Laparoendosc Surg.* 2006; 10(2): 244-6.