

VATS Approach to Symptomatic Morgagni Hernia in Adults

Carvalho EA^{1,2*}, Eto YX³, Rodrigues EN⁴, Alves ALA³, Ferreira AM³, Barreto DL⁵, dos Santos EPFA⁵, de Menezes FAJ³, Bernardes HR³, Guimarães JKG³, Boaventura LS⁴, Viana NAO³, da Silveira Alves RB³, Reis R³ and Furtado RDC³

¹Hospital Alberto Cavalcanti / Fundação Hospitalar do Estado de Minas Gerais, Departamentos de Cirurgia Torácica e Oncológica - Belo Horizonte - MG - Brasil

²Instituto Mario Penna/ Hospital Luxemburgo, Departamentos de Cirurgia Torácica e Cirúrgica Oncológica - Belo Horizonte - MG – Brasil

³Hospital Alberto Cavalcanti/Fundação Hospitalar do Estado de Minas Gerais, Departamento de Cirurgia Geral – Belo Horizonte – MG – Brasil

⁴Hospital Júlia Kubistheck / Fundação Hospitalar do Estado de Minas Gerais, Departamento de Anestesiologia – Belo Horizonte – MG – Brasil

⁵Hospital Cristiano Machado/ Fundação Hospitalar do Estado de Minas Gerais, Departamento de Cirurgia Geral – Belo Horizonte – MG – Brasil

*Corresponding author:

Erlon de Avila Carvalho,
Hospital Alberto Cavalcanti, Rua Camilo de Brito, 636, Bairro Padre Eustáquio, Minas Gerais - Brasil,
E-Mail: erlon.avila@gmail.com

Received: 22 Feb 2021

Accepted: 08 Mar 2021

Published: 12 Mar 2021

Copyright:

©2021 Carvalho EA, et al. This is an open access article distributed under the terms of the Creative Commons Attribution License, which permits unrestricted use, distribution, and build upon your work non-commercially.

Keywords:

Congenital Diaphragmatic Hernias; Morgagni Hernia; Thoracic Surgery; Minimally Invasive Surgery

Citation:

Carvalho EA, VATS Approach to Symptomatic Morgagni Hernia in Adults. Clin Surg. 2021; 5(3): 1-4

1. Abstract

Congenital diaphragmatic hernias represent 8% of congenital malformations and are characterized by a defect in the diaphragm, creating communication between the abdominal and thoracic cavities. Morgagni hernia (MH) is a type of congenital anteromedial herniated diaphragmatic hernia and represents 2-4% of diaphragmatic hernias. It appears as a result of a defect in the development of the diaphragm between its costal and sternal origin with the separation between the transverse septum and the costal arches (sternocostal triangle), forming the foramen of Morgagni, of pathology and etiology still unknown. This defect can cause abdominal contents to enter the chest cavity and, although it can cause symptoms such as cough, dyspnea and retrosternal pain, most cases are asymptomatic and its finding is usually accidental when chest or abdominal radiography is performed. The propaedeutic should be followed by computed tomography (CT) scan of the chest and abdomen, considered the gold standard diagnosis. There is a consensus in the scientific literature that the treatment of MH in symptomatic

or even asymptomatic adults is essentially surgical and should be instituted immediately after diagnosis due to the risk of developing complications. In the present study, we report a case of symptomatic MH with associated chronic dyspnea in a 59-year-old woman, being corrected by video-assisted thoracic surgery (VATS) in a tertiary health service in the city of Belo Horizonte, Minas Gerais, Brazil. The minimally invasive thoracic approach is still poorly performed and little described in the literature, despite its clear benefits and success rates similar to abdominal approaches. The present report of MH is of great importance to the scientific literature due to the scarcity of studies on the pathology in question and evidences a satisfactory outcome after MH correction in adults by minimally invasive thoracic route. As it is a rare entity, new case reports may contribute to a better definition of diagnostic, propaedeutic and therapeutic methods of MH.

2. Introduction

Morgagni's hernia consists of protruding abdominal structures to the chest through a defect in the anteromedial region of the dia-

phragm, formed due to the failure of its embryological fusion to the transverse septum and the ribs. It is extremely rare, comprising about 2 to 4% of diaphragmatic hernias of congenital origin, with the majority occurring in the right hemi thorax. When manifested in neonates, severe and fatal respiratory symptoms occur [2-6].

The symptoms differ when MH manifests in adulthood. Most patients are asymptomatic or have non-specific gastrointestinal symptoms (epigastric pain, nausea and vomiting) and cardiopulmonary (cough, palpitations and dyspnea), making it a diagnostic challenge in adulthood. When complications occur due to imprisonment or strangulation of structures in the diaphragmatic defect, obstructive symptoms may appear [2, 4-8, 11].

There are rare cases of symptomatic MH in adults in the current literature, with dyspnea of varying degrees, retrosternal discomfort and cough being described as the main manifestations. Although it can cause such symptoms, most cases are asymptomatic and its finding is usually accidental when chest or abdominal radiography is performed.

In view of the possible complications, once diagnosed, MH should be treated, even if asymptomatic. Treatment is primarily surgical and options include median sternotomy, thoracotomy, thoracosco-

py, in addition to abdominal approaches via laparotomy and laparoscopy. The transabdominal approach is usually performed in emergency situations or in bilateral defects [1, 2].

This study goal is to report a case of symptomatic MH with associated chronic dyspnea, being surgically corrected by thoracoscopy.

3. Case Report

Female patient, 59 years old, with hypertension and hypothyroidism, on regular medication use, with good control of both pathologies. Report of chronic dyspnea to great efforts, since adolescence, without symptoms of heartburn, regurgitation or associated hyporexia. She started cancer monitoring at Alberto Cavalcanti's Hospital due to the appearance of melanoma in her right thigh. Control tests revealed an image in the right supra diaphragmatic region suspected of having a diaphragmatic hernia, and a chest CT scan was then requested for diagnostic clarification. Image examination showed ventral diaphragmatic hernia on the right with insinuation of intra-abdominal fatty tissue to the anterior mediastinum, with no signs of suffering from its content, and compression atelectasis in the middle lobe was also observed: findings compatible with Morgagni's diaphragmatic hernia (Figures 1 & 2). Then preoperative preparation was carried out to perform corrective surgery electively.

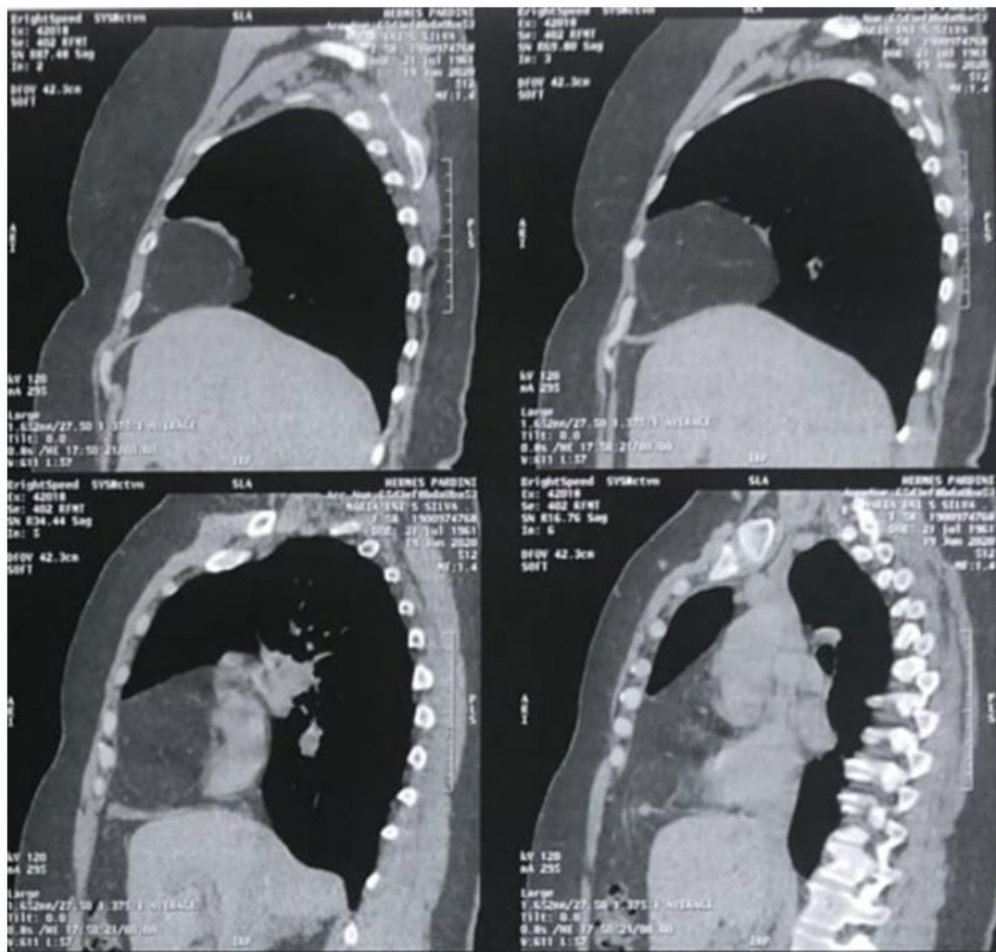


Figure 1&2: Ventral diaphragmatic hernia on the right with insinuation of intra-abdominal fatty tissue to the anterior mediastinum

Surgery was performed by VATS, patient positioned on the semi-back, using a cushion under the right lateral region of the chest and elevation of the right upper limb under the head, exposing the region of trocars insertion in the right hemithorax. VATS identified a large fatty content insinuating itself through a failure of the diaphragmatic coverage in the right ventral region of about 3 cm. Reduction of the content for the abdominal cavity and defect raffia with vicryl 1-0 with separate stitches, requiring a small infra mammary incision. Tubular drain inserted in a water seal in the right hemithorax, a surgical procedure without further complications. The patient evolved well in the immediate postoperative period, with good pain control and rapid reduction of chest drainage. Chest radiography was performed on the first and second postoperative days with no changes, then the drain on the second postoperative day was removed. She was discharged from the service on the third postoperative day with a request for a new radiograph to be performed on an outpatient basis after fifteen days. She has been in outpatient follow-up since then, with no complications in the late postoperative period until now.

4. Discussion

Congenital diaphragmatic hernias (CDH) represent 8% of congenital malformations and are characterized by a defect in the diaphragm, creating communication between the abdominal and thoracic cavities. They are generally classified, according to location, into three types: Bochdalek, Morgagni and Esophageal Hiatus [1].

Morgagni's hernia (MH), the eponymous name that identifies anteromedial retrosternal CDH, represents 2-4% of diaphragmatic hernias and was first described by the Italian anatomist Giovanni Battista Morgagni in 1769 in "The Seats and Causes of Diseases, Investigated by Anatomy" [1]. It appears as a result of a defect in the development of the diaphragm between its costal and sternal origin with the separation between the transverse septum and the costal arches (sternocostal triangle), forming the foramen of Morgagni, of pathology and etiology still unknown today [1].

This defect can lead to the entry of abdominal contents such as omentum and colon in the thoracic cavity and in more severe cases, stomach, liver and small intestine [1, 2]. This type of herniation can be fatal in infants due to the fact that large diaphragmatic defects lead to compression of the immature lung, resulting in defective lung formation and possible subsequent respiratory failure, as well as changes in the location of thoracic viscera from their natural position. Severity is related to the size of the herniated viscera and the period of pregnancy in which migration occurs [1, 2]. About 90% of MH occur on the right, as a result of the malformation being obliterated by the pericardium, 8% are on the left and 2% are bilateral [1].

Prenatal diagnosis occurs from the 15th week of pregnancy through ultrasound; however, it is more common during the morphological examination performed in the second trimester [2]. In adults, the

most suitable test is computed tomography scan of chest and upper abdomen, nonetheless, it is possible to be diagnosed in other imaging tests (radiography, ultrasound, nuclear magnetic resonance [1]).

Case reports and literature review studies have shown that MH is even rarer among adult individuals. Like the patient mentioned in this study, the majority of adult patients diagnosed with the disease are female (62%), are over 50 years of age and approximately 50% have predisposing factors that lead to increased intra-abdominal pressure (pregnancy, multiparity, trauma, obesity, constipation and chronic cough). Therefore, it is suggested that in adults there is an association between congenital diaphragm disorder and acquired factors, although the physiopathology of MH in this age group is still not well established in the scientific literature [2-4, 6, 8-10].

As in the case described, most MH diagnoses are incidental, discovered on chest radiography and appear as a nonspecific chest mass. If the herniated content contains an intestinal loop, intra-thoracic air content can be seen, consisting of a pathognomonic sign of MH. The propaedeutic should be followed by chest and abdomen CT scan, a highly sensitive test that, for revealing anatomical details, associated complications and defining the herniated structure, is considered the gold standard diagnosis. Other methods that help the characterization of this pathology are ultrasound, endoscopy of the upper gastrointestinal tract, contrasted enema and Magnetic resonance imaging (MRI) [5, 8-10].

There is a consensus in the scientific literature that the treatment of MH in symptomatic or even asymptomatic adults is essentially surgical and should be instituted immediately after diagnosis due to the risk of developing complications. Surgery is based on excision of the hernia sac, return of the contents to the abdominal cavity and closure of the hernia defect [3-5, 9-10, 12, 14].

Abdominal (laparotomy or laparoscopy) and thoracic (thoracotomy, sternotomy or thoracoscopy) approaches are possible, but there is still no scientific evidence to demonstrate clear superiority in the results of one over the other [3, 12]. Retrospective analysis of a Turkish study of 20 adult patients undergoing MH correction surgery revealed that those operated on abdominally achieved a similar success rate to those operated on thoracic [12].

Minimally invasive surgical techniques have advantages because they provide less postoperative pain, shorter hospital stays, early return to daily activities and better aesthetic results. However, this practice is still not widespread. A literary review study published in 2008 highlights that among 298 analyzed cases of MH in adults, only 2 were addressed by thoracoscopy [9]. Although they can culminate in a longer surgical time, they should be preferred when available [5, 6, 14, 15]. Literature review studies show that the approach of MH by thoracoscopy allows easy dissection of the hernial sac from mediastinal and pleural structures in addition to providing sufficient exposure for its repair [3, 9, 12].

Authors of a retrospective study conducted at the Mayo Clinic, USA, evaluated the history of 43 adult patients undergoing MH repair from 1987 to 2015. They concluded that the decision regarding the approach and the surgical technique used must be individualized and that due to the lack of evidence of superiority, the surgeon's preference and experience should be the main factors considered [11]. In agreement with these data, due to the availability of an experienced thoracic surgeon in the service where the surgical approach of the case presented was performed, the VATS approach was chosen.

5. Conclusion

The present report of Morgagni's Hernia is of great importance to scientific literature. On the grounds that it is a rare entity, especially when it manifests in an adult patient, new case reports may contribute to the better definition of diagnostic, propaedeutic and therapeutic methods of MH.

As a result of increase in the availability of sensitive imaging methods, a trend towards an increase in the number of incidentally diagnosed cases is expected, as it is this one reported [11]. Therefore, further studies on the behavior of MH in adults are needed.

In addition, MH diagnosed in adult patients lacks scientific consensus and standardization regarding its pathophysiology and the best form of therapeutic surgical approach. Several literary review articles and case reports call attention to the need for new data in this matter [3, 9, 11]. This article seeks to disseminate a possible effective and resolute diagnostic-therapeutic approach in the management of MH.

The minimally invasive thoracic approach is still poorly performed and little described in the literature, despite its clear benefits and success rates similar to abdominal approaches. Therefore, this case report also seeks to show a satisfactory outcome, good postoperative evolution and adequate pain control after correction in adults using minimally invasive thoracic access.

References

1. Santos E., Ribeiro S. Hérnia diafragmática congênita - artigo de revisão. *Acta Obstet Ginecol Port.* 2018; 2(1): 25-33.
2. Morgagni GB. The seats and causes of diseases investigated by anatomy; in five books, containing a great variety of dissections, with remarks. London: A. Millar; T. Cadell. 1769.
3. Târcoveanu E, Georgescu Ș, Vasilescu A, Andronic D, Dănilă N, Lupașcu C, et al. Laparoscopic Management in Morgagni Hernia - Short Series and Review of Literature. *Chirurgia (Bucur).* 2018; 113(4): 551-7.
4. Sanford Z, Weltz AS, Brown J, Shockcor N, Wu N, Park AE. Morgagni Hernia Repair: A Review. *Surg Innov.* 2018; 25(4): 389-99.
5. Elfiky A, Daneshvar D, Krzyzak M, Mukherjee I. Adult Onset Morgagni Hernia: Medical vs. Surgical Management. *Cureus.* 2019; 11(5): e4626.
6. Costa Almeida C, Caroço TV, Nogueira O, Infuli A. Laparoscopic repair of a Morgagni hernia with extra-abdominal transfascial sutures. *BMJ Case Rep.* 2019; 12(1): e227600.
7. Ryan JM, Rogers AC, Hannan EJ, Mastro Simone A, Arumugasamy M. Technical description of laparoscopic Morgagni hernia repair with primary closure and onlay composite mesh placement. *Hernia.* 2018; 22(4): 697-705.
8. Tone K, Kiryu I, Yoshida M, Tsuboi K, Takagi M, Kuwano K. Morgagni hernia with respiratory failure aggravated by noninvasive positive pressure ventilation: a case report and overview of the literature. *Respir Investig.* 2014; 52(3): 203-8.
9. Kim DK, Moon HS, Jung HY, Sung JK, Gang SH, Kim MH. An Incidental Discovery of Morgagni Hernia in an Elderly Patient Presented with Chronic Dyspepsia. *Korean J Gastroenterol.* 2017; 69(1): 68-73.
10. Horton JD, Hofmann LJ, Hetz SP. Presentation and management of Morgagni hernias in adults: a review of 298 cases. *Surg Endosc.* 2008; 22(6): 1413-20.
11. Eren S, Ciris F. Diaphragmatic hernia: diagnostic approaches with review of the literature. *Eur J Radiol.* 2005; 54: 448-59.
12. Young MC, Saddoughi SA, Aho JM, Harmsen WS, Allen MS, Blackmon SH, et al. Comparison of Laparoscopic Versus Open Surgical Management of Morgagni Hernia. *Ann Thorac Surg.* 2019; 107(1): 257-61.
13. Aydin Y, Altuntas B, Ulas AB, Daharli C & Eroglu A. Morgagni Hernia: Transabdominal or Transthoracic Approach? *Acta Chirurgica Belgica.* 2014; 114: 131-5.
14. Yoldas T, Ustun M, Karaca C, Firat O, Caliskan C, Akgun E, et al. Morgagni Hernia: Is It Just a Congenital Hernia or a Cause of Emergency Surgery? *Am Surg.* 2016; 82(11): 317-9.
15. Ağalar C, Atila K, Arslan NÇ, Derici ZS, Bora S. Adult morgagni hernia: a single center experience of 5 cases and review of literature. *Turk J Surg.* 2019; 35(4): 321-4.