

Appendiceal Mucocele: Management of This Rare Entity Cases Report and Review of Literature

Petros Siaperas¹, Evangelos Velaoras^{1*}, Aikaterini-Paraskevi Pierrakou², Andreas Tellos¹ and Ioannis Karanikas¹

¹2nd Department of General Surgery, Sismanoglion General Hospital, Athens Greece

²Department of Pathology, Sismanoglion General Hospital, Athens Greece

*Corresponding author:

Evangelos Velaoras,
2nd Department of General Surgery,
Sismanoglion General Hospital, Athens Greece

Received: 12 Aug 2024

Accepted: 16 Sep 2024

Published: 21 Sep 2024

J Short Name: COS

Copyright:

©2024 Evangelos Velaoras, This is an open access article distributed under the terms of the Creative Commons Attribution License, which permits unrestricted use, distribution, and build upon your work non-commercially.

Citation:

Evangelos Velaoras. Appendiceal Mucocele: Management of This Rare Entity Cases Report and Review of Literature . Clin Surg. 2024; 11(1): 1-5

1. Introduction

Appendiceal mucocele is a very rare entity, which according to the literature is found in only 0.3% of appendectomy specimens. Average age of diagnosis is considered around 50 years, without excluding younger patients. There is also a slightly higher incidence in female over male population. The term low-grade appendiceal mucinous neoplasms (LAMN) has been recently introduced by WHO and includes the previous term “mucocele”. This entity, although rare, can be presented with a great variety of symptoms and appears to have a great fluctuation concerning the survival rate according to the stage. Despite new terms having been introduced, literature has not yet concluded on the appropriate surgical management of this entity. In this abstract, we present 3 cases and a concomitant review of the recent literature.

2. Material & Methods

We have collected data regarding 3 recent cases presented in our department with completely different clinical presentation from March to June 2023.

3. Cases Presentation

A 56-year-old male patient was presented for an elective operation. Patient was complaining for vague abdominal symptoms. He submitted a CT scan which did not clearly show mucocele but differential diagnosis mentioned either peritoneal cyst or duplication cyst. He also had a negative colonoscopy. He was submitted to laparotomy. Intraoperative finding was appendiceal mucocele with no rupture or any distal signs of disease. An open right colectomy with side-to-side anastomosis was performed. Post-operative

course was uneventful. The histology report showed LAMN and staging was pT3 according to TNM/AJCC 2017. A 47 year old female patient was presented in ED with signs of acute appendicitis. Laboratory exams showed leukocytosis, plus elevated CRP. During clinical examination there were positive McBurney and Rovsing signs. U/S and CT scan were positive for acute appendicitis. Patient was submitted to laparoscopic appendectomy. Due to operational findings which showed mucocele a conversion to open with a midline incision was decided. Patient was submitted to right hemicolectomy with side to side anastomosis. Specimen was removed intact with appendix being measured at 7.7 x 2.5 cm. Post-operative course was uneventful. The histology report showed LAMN G1 (WHO 2019) and was negative for lymph node metastasis (0/19). As a result, staging was considered pTis N0 (UICC). A 35 year old male patient was presented to Emergency Department carrying with him a U/S examination which showed an abdominal mass with concomitant present of ascites. Patient reported that he decided to have a U/S examination due to mild abdominal discomfort and sense of fullness he had for few days. During operation a vast quantity of mucous was observed due to a ruptured mucocele. Thorough lavage of peritoneal cavity was performed and a right hemicolectomy with side to side anastomosis was decided. Post-operative course was uneventful. The histology report confirmed the diagnosis of a ruptured appendiceal mucocele with dimensions 14.4 x 2.9 cm. It revealed LAMN G1, was negative for lymph node metastasis (0/26) but staging was pT4a N1c M1b (according to AJCC-UICC 9th ed.).

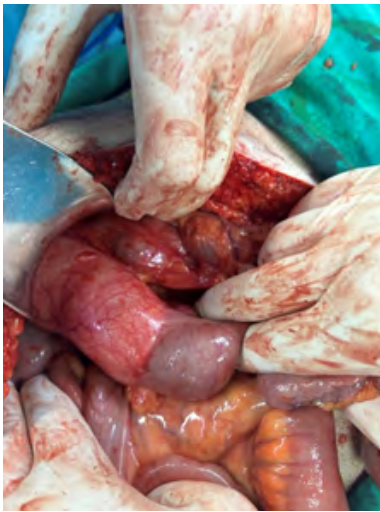


Figure 1 Case 1: Appendiceal Mucocele.

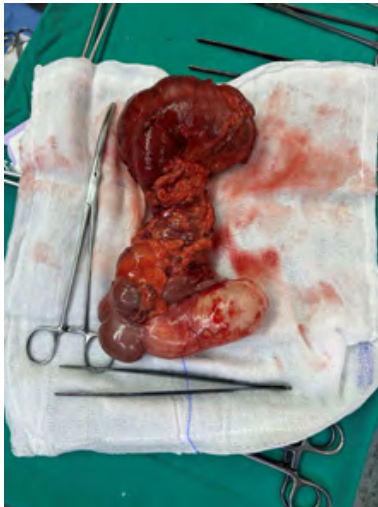

Figure 2 Case 1: Right colectomy specimen. Notice that mucocele is intact.

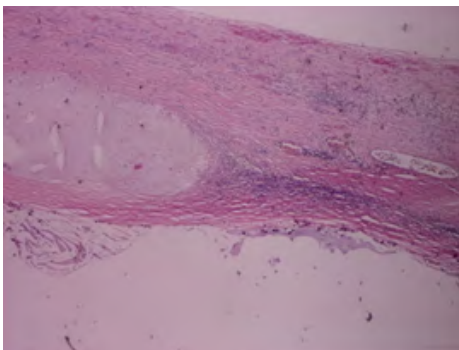
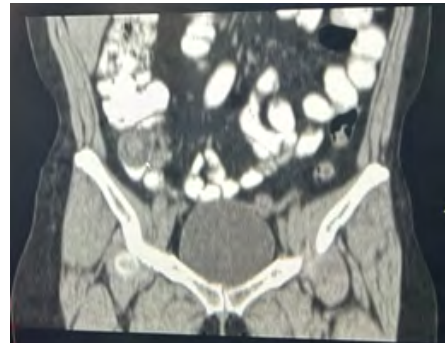

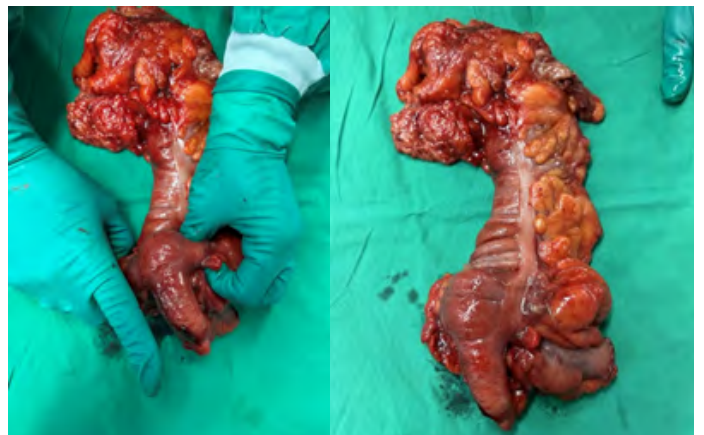Figure 3 Case 1: H&EX40. Focal invasion of the muscle wall by neoplastic cells. Presence of organized mucus in the subserosa, without extension to the serosal surface.


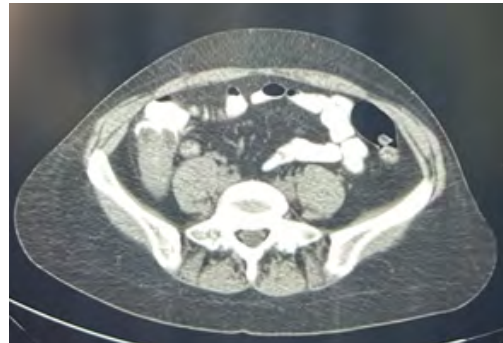


Figure 4 Case 1: DesminX40) Desmin immunohistochemical stain highlights the breakdown of the muscle wall.



Figures 5&6 Case 2: CT showing appendiceal mucocele (arrow).



Figures 7&8 Case 2: Specimen removed compared to assistant's hand. Notice mucocele is intact.



Figure 9 Case 2: Cross sectioning of the appendix, macroscopic view.

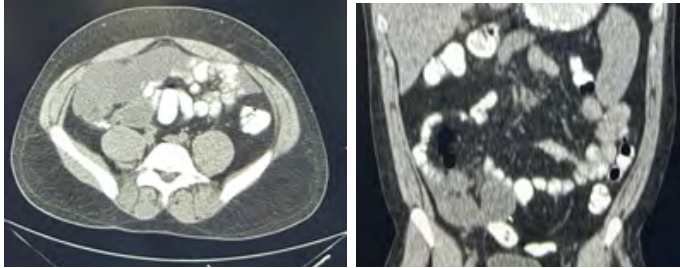


Figure 10&11: Case 3: CT showing vast quantity of muci in the abdominal cavity.

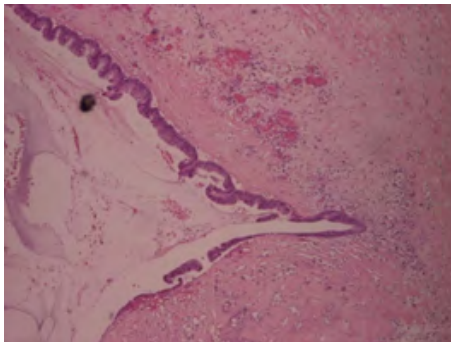


Figure 12 Case 3: H&E, 40x Low-grade appendiceal mucinous neoplasm. Epithelium with slender villi lined by tall mucinous epithelial cells with low-grade cytological atypia. Intramural glandular epithelium protruding into the appendiceal wall, exhibiting a pushing pattern of invasion.

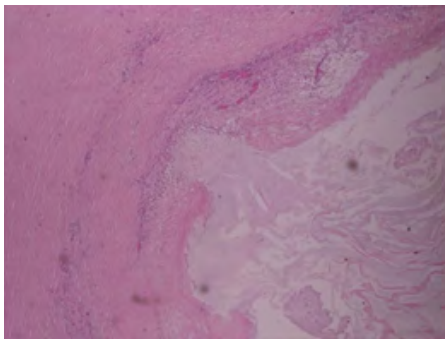


Figure 13 Case 3: H&E, 40x Low-grade appendiceal mucinous neoplasm. Low-power view exhibiting a pushing margin of the tumour in the fibrotic appendiceal wall.

4. Review of The Literature

During review of the literature for appendiceal mucocele, we found interesting data regarding its epidemiology, clinical presentation, diagnosis, therapeutic management, histopathology, grading, prognosis and survival.

A. Epidemiology: Only 0.3% of appendix specimens turn to be mucocele which makes this entity quite rare. Average age of patients diagnosed with mucocele is about 50 years and there is a marginal trend towards female sex [1,2].

B. Clinical Presentation: From literature, it seems that there is a great variety of symptoms that cannot predispose the clinician towards this diagnosis. A lot of patients complain about fatigue with mild abdominal discomfort. Only 14% have a palpable abdominal mass and even fewer, around 8%, present with appendicitis [3-5]. Stocchi et al found a correlation between the presence of symptoms, pain, abdominal mass, PMP with aggressive malignancy. Actually, symptomatic patients were more likely to have a malignant appendiceal mucocele when compared with those presenting with no mucocele-related symptoms. What is also important to mention is that, 95% of patients presenting at a very late stage with PMP seemed to have a highly malignant mucocele [3].

C. Diagnosis: There is no specific examination for the detection of mucocele on a regular basis. U/S and CT seem to be the gold standard. Cystic dilatation of the appendix and mural calcification seem to be common CT findings. A maximal luminal diameter greater than 1.3 cm has a sensitivity of 71.4%, specificity of 94.6%, and overall diagnostic accuracy of 88.2% for the diagnosis of acute appendicitis with mucocele [6, 7]. U/S can be used in the primary work-up of the management of right lower quadrant (RLQ) pain or abdominal discomfort. The “onion skin sign” is highly specific for mucocele, although quite rare [8].

D. Endoscopy: Colonoscopy has little to offer as mucocele can be found rarely during routine endoscopy. Colonoscopy usually reveals a smooth ball-shaped mound at the orifice of the appendix, moving in and out with respiratory movement. The appendiceal orifice is in the center of the mound, which is known as the “volcano sign”. [9]. Additionally, 13-42 % of patients diagnosed with appendiceal neoplasms also have synchronous colonic lesions which means that colonoscopy is indicated pre- or post- operatively [10].

E. Histopathology and Grading: There is a great debate about the appropriate classification of this entity as it can present a great variety. According to the PSOGI consensus classification appendiceal mucinous neoplasms can be characterized as -Serrated Polyp, Low grade mucinous neoplasm – LAMN, High grade mucinous neoplasm – HAMN and Mucinous adenocarcinoma (with or without signet ring cells). AJCC grades LAMN and HAMN as G1 and adenocarcinomas as G2 or G3. HAMNs have been shown to have mutations in TP53, ATM, and APC, and these additional al-

terations may be responsible for the more aggressive phenotypes [11,12]. Desmoplastic stroma with infiltrative invasion and the presence of signet ring cells are considered negative predictive factors. [11,12].

F. Surgery: It is not yet established which surgical approach is best for patients diagnosed with mucocoele. The literature agrees that care should be taken in order to remove intact an unruptured mucocoele and this is the reason why a low threshold for conversion from laparoscopic to open should exist. The debate concerns whether appendectomy alone or right hemicolectomy is the procedure of choice. AJCC proposes appendectomy alone in a presence of unruptured mucocoele which does not involve the base of cecum, an entity which is quite rare and difficult to judge intraoperatively [13]. Moreover, there is a controversy about whether microscopically positive margin after appendectomy for an unruptured LAMN indicates more radical excision (cecectomy, colectomy). Right colectomy is indicated in the presence of G2 or G3 mucinous adenocarcinoma [5].

G. Crs-Hipec: Literature agrees upon performing cytoreductive surgery (CRS) and heated intraperitoneal chemotherapy (HIPEC) only in specialized centers. On the contrary, there is a great debate upon which patients should be managed by surveillance or should undergo CRS-HIPEC. The ACCRS recommends CRS following appendectomy for patients with acellular mucin limited to the right lower quadrant, but also HIPEC for those with cellular mucin. [14] The Chicago consensus proposes CRS/HIPEC for patients with widespread disease or cellular mucin [15].

H. Survival: Prognosis is dependent on histology and presence, extent of peritoneal spread and invasion which determine the recurrence. After appendectomy, 5-year survival rate for the simple LAMN is 91-100% but it reduces to 51% for mucinous adenocarcinoma. No significant difference is observed in survival between LAMN and HAMN although limited data is available. However, 5-year overall survival rates for localized stages I to III of 74.9, 63.2, and 51.1 % for well-, moderately, and poorly differentiated tumors, respectively. For stage IV disease, the five-year overall survival rates were 56.7, 31.5, and 11.3 % correspondingly [16].

5. Discussion

Appendiceal mucocoele is a quite rare entity found only in 0.3% appendectomy specimens. Mean age of diagnosis is 50 years old with a slight prevalence towards female sex. Symptoms that may cause suspicion of mucocoele are vague abdominal discomfort, palpable abdominal mass or typical signs of acute appendicitis. Given the fact that there are no specific symptoms related to this pathology its diagnosis is often missed by physicians. U/S and CT scan seem to be the examination of choice for the differential diagnosis of RLQ pain or abdominal discomfort. Colonoscopy has little to offer as mucocoeles are rarely found during endoscopy routine check but it is essential to perform a full colonoscopy when the

diagnosis of mucocoele is made to exclude synchronous pathology. Literature has not yet concluded on the best surgical approach of this entity. There is a debate whether appendectomy alone versus right colectomy is the procedure of choice for an intact mucocoele when pathology is localized to RLQ. On the contrary, it is generally agreed that great care should be taken so that the specimen is removed intact. Another debate concerns patients who are eligible for CRS/HIPEC. The literature agrees that widespread disease is an indication for CRS/HIPEC which must be performed only in specialized centers. Survival rates have a great fluctuation according to histology, presence and extent of peritoneal spread and invasion with the PMP having the worst prognosis.

References

1. Dixit A, Robertson JH, Mudan SS, Akle C. Appendiceal mucocoeles and pseudomyxoma peritonei. *World J Gastroenterol.* 2007; 13(16): 2381-4.
2. Dhage-Ivatury S, Sugarbaker PH. Update on the surgical approach to mucocoele of the appendix. *J Am Coll Surg.* 2006; 202: 680-684.
3. Stocchi L, Wolff BG, Larson DR, Harrington JR. Surgical treatment of appendiceal mucocoele. *Arch Surg.* 2003; 138: 585-589.
4. Haritopoulos KN, Brown DC, Lewis P, Mansour F, Eltayar AR, Labruzzo C. Appendiceal mucocoele: a case report and review of the literature. *Int Surg.* 2001; 86: 259-262.
5. Govaerts K, Lurvink RJ, De Hingh IHJT, Van der Speeten K, Ville-neuve L, Kusamura S, Kepenekian V. PSOGI. Appendiceal tumours and pseudomyxoma peritonei: Literature review with PSOGI/EU-RACAN clinical practice guidelines for diagnosis and treatment. *Eur J Surg Oncol.* 2021; 47(1): 11-35.
6. Bennett GL, Tanpitukpongse TP, Macari M, Cho KC, Babb JS. CT diagnosis of mucocoele of the appendix in patients with acute appendicitis. *AJR Am J Roentgenol.* 2009; 192(3): W103-10.
7. Kim SH, Lim HK, Lee WJ, Lim JH, Byun JY. Mucocoele of the appendix: ultrasonographic and CT findings. *Abdom Imaging.* 1998; 23(3): 292-6.
8. Caspi B, Cassif E, Auslender R, Herman A, Hagay Z, Appelman Z. The onion skin sign: a specific sonographic marker of appendiceal mucocoele. *J Ultrasound Med.* 2004; 23(1): 117-21; quiz 122-3.v
9. Zanati SA, Martin JA, Baker JP, Streutker CJ, Marcon NE. Colonoscopic diagnosis of mucocoele of the appendix. *Gastrointest Endosc.* 2005; 62: 452-456
10. Trivedi AN, Levine EA, Mishra G. Adenocarcinoma of the appendix is rarely detected by colonoscopy. *J Gastrointest Surg.* 2009; 13: 668.
11. Umetsu SE, Kakar S. Staging of appendiceal mucinous neoplasms: challenges and recent updates. *Hum Pathol.* 2023; 132: 65-76.
12. Carr NJ, Cecil TD, Mohamed F, Sobin LH, Sugarbaker PH. Peritoneal Surface Oncology Group International. A Consensus for Classification and Pathologic Reporting of Pseudomyxoma Peritonei and Associated Appendiceal Neoplasia: The Results of the Peritoneal Surface Oncology Group International (PSOGI) Modified Delphi Process. *Am J Surg Pathol.* 2016; 40(1): 14-26.

13. Choudry HA, Pai RK. Management of Mucinous Appendiceal Tumors. *Ann Surg Oncol*. 2018; 25(8): 2135-2144.
14. Glasgow SC, Gaertner W, Stewart D. The American Society of Colon and Rectal Surgeons, Clinical Practice Guidelines for the Management of Appendiceal Neoplasms. *Dis Colon Rectum*. 2019; 62: 1425.
15. Chicago Consensus Working Group. The Chicago Consensus on Peritoneal Surface Malignancies: Management of Appendiceal Neoplasms. *Ann Surg Oncol*. 2020; 27: 1753.
16. Overman MJ, Fournier K, Hu CY. Improving the AJCC/TNM staging for adenocarcinomas of the appendix: the prognostic impact of histological grade. *Ann Surg*. 2013; 257: 1072.
17. Misdraji J, Yantiss RK, Graeme-Cook FM, Balis UJ, Young RH. Appendiceal mucinous neoplasms: a clinicopathologic analysis of 107 cases. *Am J Surg Pathol*. 2003; 27(8): 1089-103.
18. Gao J, Chu Z, Chen J, Zheng Y, Huang X, Hu K. Retrospective analysis of 9 cases of appendiceal mucocele in 3,071 cases of appendicitis. *Biomed Rep*. 2022; 17(1): 55.
19. Singh MP. A general overview of mucocele of appendix. *J Family Med Prim Care*. 2020; 9(12): 5867-5871.