

A Unique Case of HPV- and EBV-Positive Non-Keratinizing Squamous Cell Carcinoma Located in the Tonsil

Christian Righini^{1,2,3}, Jérémie Ménager⁴ and Hugo Gil^{*}

¹Service Hospitalo-Universitaire d'ORL et Chirurgie Cervico-Faciale, CHU Grenoble Alpes (CHUGA), France

²UGA/UMR/CNRS 5309/INSERM 1209, Institut Albert Bonniot, Grenoble, France

³Department of Anatomic and Cytopathology, Hôpital Nord, CHU Grenoble Alpes (CHUGA), France

⁴Department of Anatomic and Cytopathology, Hôpital Nord, CHU Grenoble Alpes (CHUGA), France

*Corresponding author:

Hugo Gil,
Department of Anatomic and Cytopathology,
Hôpital Nord, CHU Grenoble Alpes (CHUGA),
France

Received: 05 Jan 2026

Accepted: 28 Jan 2026

Published: 03 Feb 2026

J Short Name: COS

Copyright:

©2026 Hugo Gil, This is an open access article distributed under the terms of the Creative Commons Attribution License, which permits unrestricted use, distribution, and build upon your work non-commercially.

Citation:

Hugo Gil. A Unique Case of HPV- and EBV-Positive Non-Keratinizing Squamous Cell Carcinoma Located in the Tonsil. Clin Surg. 2026; 11(3): 1-4

1. Abstract

Non-keratinizing squamous cell carcinomas of the oropharynx associated with HPV (Human Papilloma Virus) account for 25% of all oropharyngeal carcinomas (including the base of the tongue, tonsils, and adenoids). Transmitted through sexual contact, the anatomical features of the palatine tonsils explain the specific tropism of HPV for this organ, in contrast to EBV (Epstein-Barr Virus), which is implicated in the carcinogenesis of nasopharyngeal non-keratinizing squamous cell carcinomas. We report the case of an 84-year-old Caucasian woman diagnosed with a non-keratinizing squamous cell carcinoma of the palatine tonsil associated with an EBV/HPV-16 co-infection. This is the first reported case of such a co-infection in the literature.

2. Introduction

Non-keratinizing squamous cell carcinomas of the oropharynx associated with HPV account for 25% of all oropharyngeal carcinomas, primarily involving the base of the tongue, palatine tonsils, and adenoids [1,2]. According to the 2017 WHO classification of head and neck tumors, HPV-16, a highly oncogenic virus, is detected in 90% of HPV-driven non-keratinizing squamous cell carcinomas of the oropharynx. The cryptic structure of palatine tonsils facilitates HPV tropism. EBV has historically been linked to undifferentiated nasopharyngeal carcinomas (UCNT). Recent meta-analyses suggest a frequent association between EBV and oral cavity squamous cell carcinomas, although this relationship remains controversial [3,4]. While co-infections of HPV and EBV have been documented in oropharyngeal squamous cell carcinomas

[5], no such cases have been specifically reported in the palatine tonsils. Here, we describe the case of an 84-year-old Caucasian woman with a non-keratinizing squamous cell carcinoma of the palatine tonsil associated with EBV/HPV-16 co-infection.

3. Case Report

An 84-year-old woman with a history of smoking (10 pack-years), hypertension, and newly diagnosed untreated type 2 diabetes presented with a progressively enlarging left submandibular mass. Examination revealed a 14×7 mm lesion on the lower pole of the left palatine tonsil and a subdiaphragmatic lymph node, confirmed via 18FDG PET-CT imaging (Figure 1).

Under general anesthesia, panendoscopy ruled out synchronous lesions. Biopsy of the left tonsil revealed a non-keratinizing carcinoma with syncytial architecture, large hyperchromatic nuclei, and abundant lymphocytic stroma (Figure 2). EBER in situ hybridization confirmed EBV positivity (Figure 3A), and p16 immunohistochemistry was diffusely positive (Figure 3B). HPV-16 was confirmed through in situ hybridization and genotyping. The final diagnosis was HPV-16-induced non-keratinizing squamous cell carcinoma with EBV co-infection. The patient underwent extended left oropharyngectomy and cervical lymphadenectomy. Pathological examination revealed a 20 mm tumor and two metastatic lymph nodes with capsular rupture, classified as pT2 N1 R+. EBV integration into tumor cells was confirmed via EBER staining (Supplemental Figures S1-S4). Adjuvant radiotherapy was recommended but declined by the patient. She remains in locoregional remission at one-year follow-up.

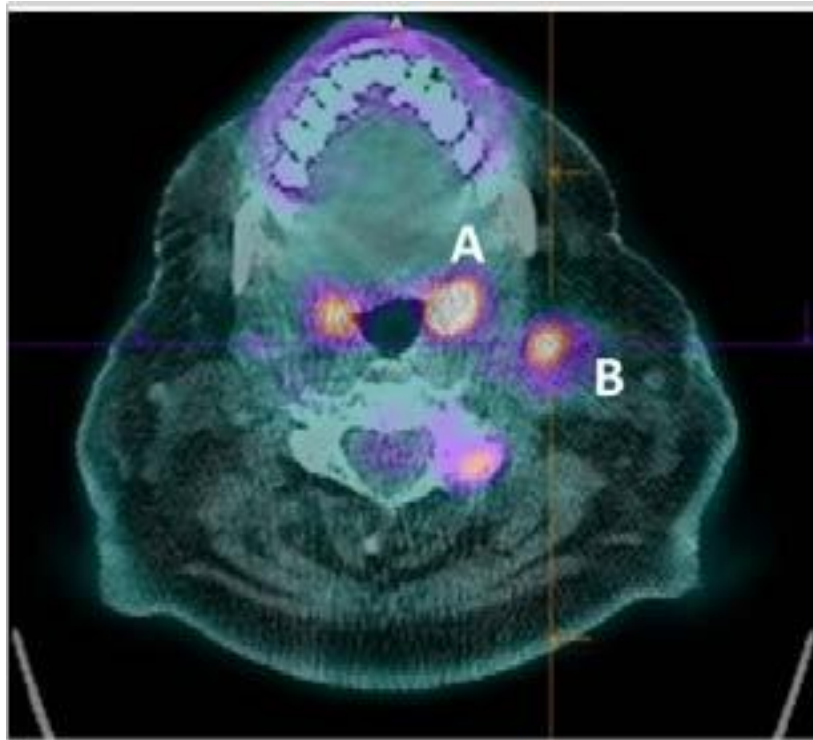


Figure 1: TEP-TDM au 18FDG A) hypermetabolisme intense de l'amygdale gauche (SUVmax=14) B) adénopathie sous digastrique gauche (SUVmax=6).

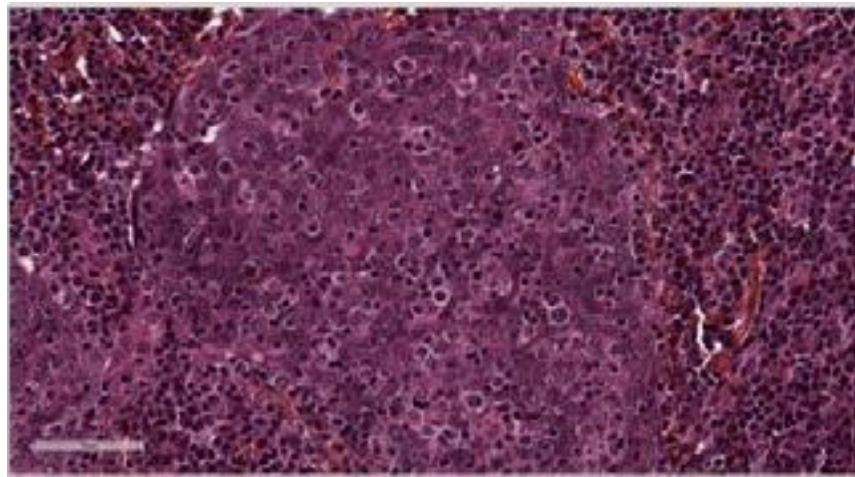


Figure 2 : Aspect histologiquepathologique de la biopsie de l'amygdale gauche au fort grossissement (x200), coloration HES.

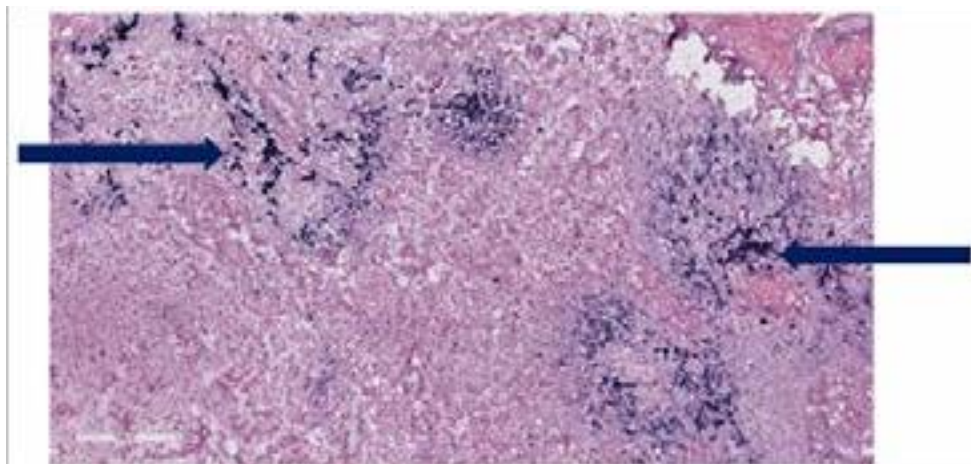


Figure 3A : recherche d'EBV par hybridation in situ, grossissement x 100, enutilisant la sonde EBER (coloration bleue positive, flèches).

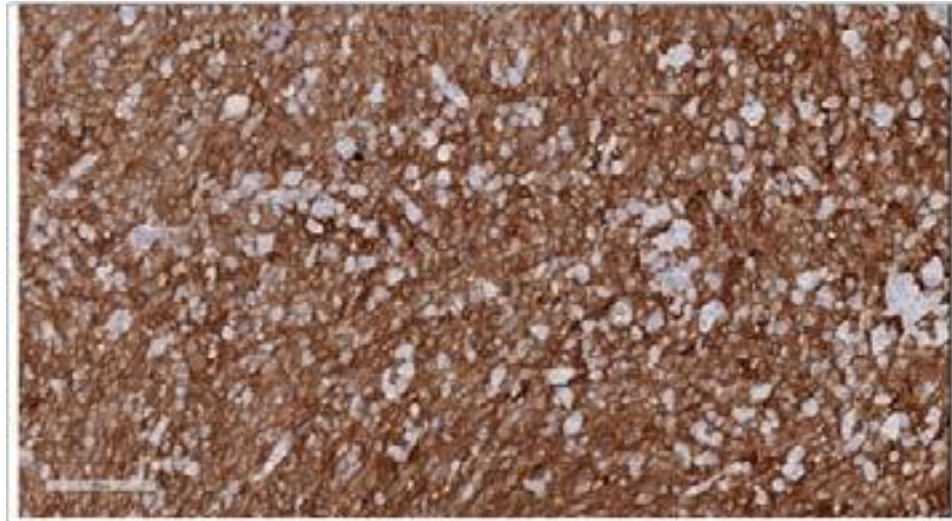


Figure 3B: Recherche d'HPV par immunohistochimie p16, grossissement Gx200 (coloration brune positive).

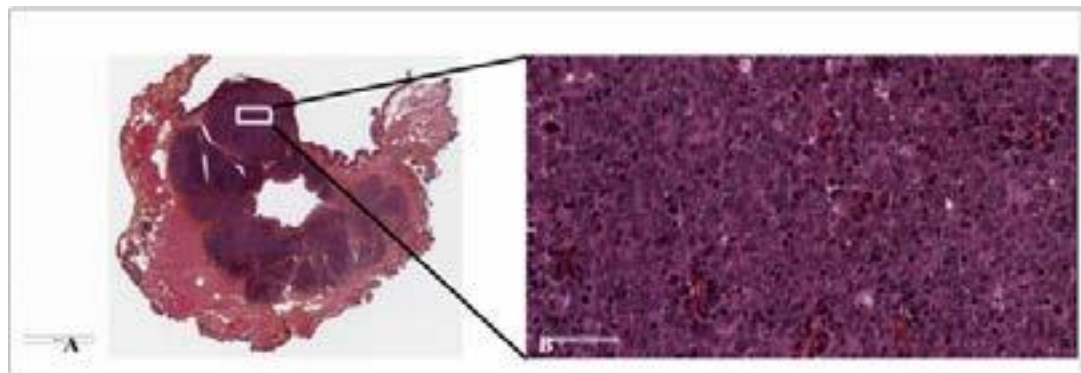


Figure S1: Amygdale gauche, coloration HES: faible grossissement (A; x16) et fort grossissement (B; x200).

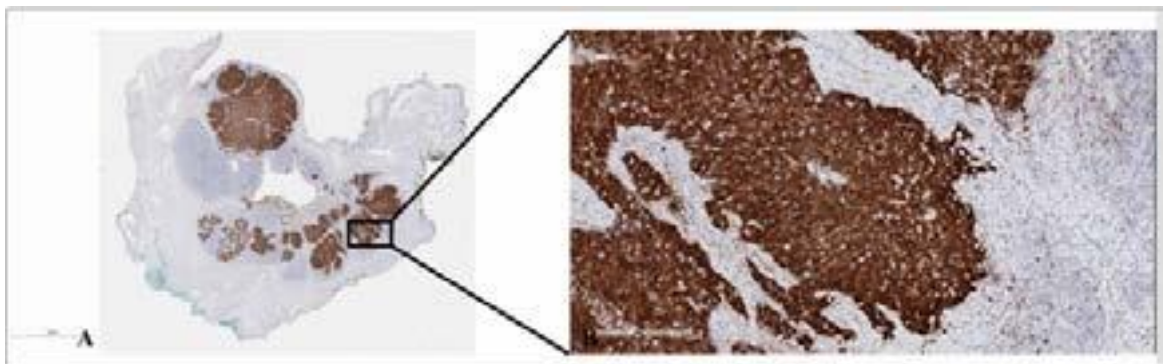


Figure S2: Amygdale gauche, IHC anti-p16: faible grossissement (A; x16) et fort grossissement (B; x200).

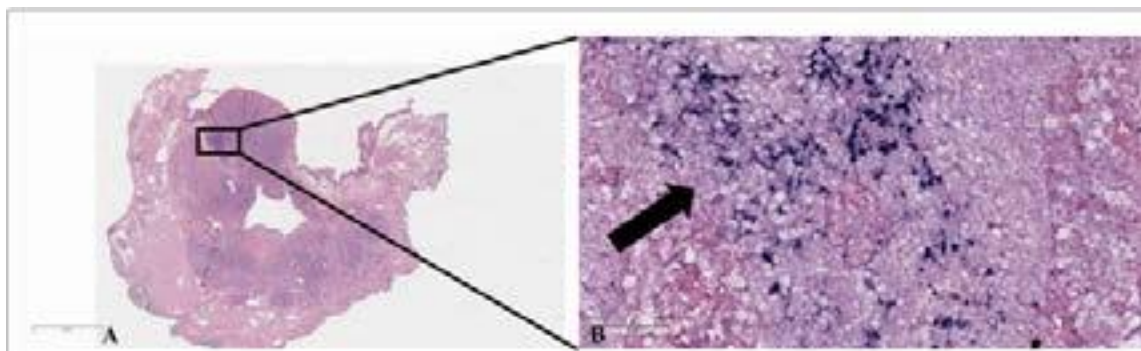


Figure S3: Hybridation in situ EBV positive (flèche) avec la sonde EBER: faible grossissement (A; x16) et fort grossissement (B; x200).

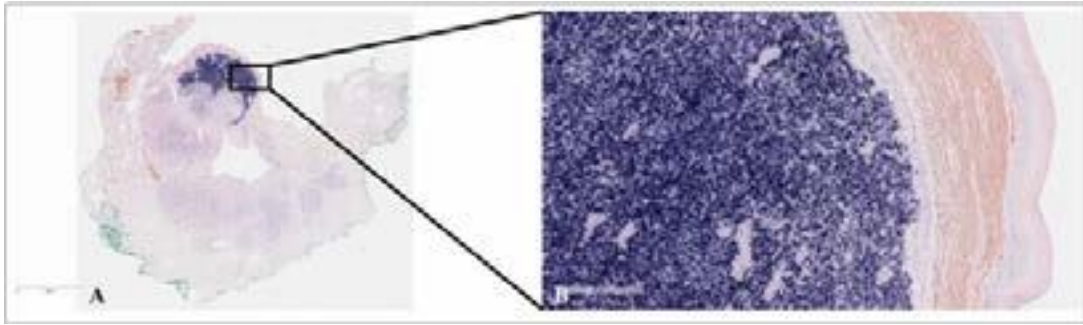


Figure S4: Hybridation in situ avec la sonde HPV16: faible grossissement (A; x16) et fort grossissement (B; x200).

4. Discussion

This is the first reported case of HPV-16 and EBV co-infection in a non-keratinizing squamous cell carcinoma localized to the palatine tonsil. The unique histological similarities between the palatine tonsils and nasopharynx may explain the potential for EBV-driven carcinogenesis in the tonsils. Previous studies have reported HPV/EBV co-infections in other oropharyngeal sites but not specifically in the tonsils [5,6]. HPV-driven oropharyngeal cancers are known to have better prognoses compared to their non-HPV counterparts, as reflected in the inclusion of HPV status in the 2017 TNM classification system [13]. The interaction between HPV and EBV in tumorigenesis warrants further investigation to better understand its prognostic and therapeutic implications.

7. Conclusion

We present the first reported case of an 84-year-old woman with HPV-16 and EBV co-infection in a non-keratinizing squamous cell carcinoma of the palatine tonsil. The patient achieved locoregional remission following surgical treatment without adjuvant therapy.

References

1. Stein AP, Saha S, Kraninger JL. Prevalence of Human Papillomavirus in Oropharyngeal Cancer. *Cancer J*. 2015;21(3):138-46.
2. Rettig EM, D'Souza G. Epidemiology of Head and Neck Cancer. *Surg Oncol Clin N Am*. 2015;24(3):379-96.
3. She Y, Nong X, Zhang M. Epstein-Barr virus infection and oral squamous cell carcinoma risk: A meta-analysis. *Plos One*. 2017;12(10):e0186860.
4. Cruz I, Brule AJCVD, Brink AATP. No direct role for Epstein-Barr virus in oral carcinogenesis: A study at the DNA, RNA and protein levels. *Int J Cancer*. 2000;86(3):356-61.
5. Broccolo F, Ciccarese G, Rossi A. Human papillomavirus (HPV) and Epstein-Barr virus (EBV) in keratinizing versus non-keratinizing squamous cell carcinoma of the oropharynx. *Infect Agents Cancer*. 2018;13(1):32.
6. Nguyen S, Kong T, Berthelet E. A Unique Case of Primary EBV-Positive, HPV-Negative Nasopharyngeal Carcinoma Located in the Tonsil. *Head Neck Pathology*. 2021;15(3):1017-22.
7. Niedobitek G, Hansmann ML, Herbst H. Epstein-Barr virus and carcinomas: Undifferentiated carcinomas but not squamous cell carcinomas of the nasopharynx are regularly associated with the virus. *J Pathology*. 1991;165(1):17-24.
8. Heck JE, Berthiller J, Vaccarella S. Sexual behaviours and the risk of head and neck cancers: a pooled analysis in the International Head and Neck Cancer Epidemiology (INHANCE) consortium. *Int J Epidemiol*. 2010;39(1):166-81.
9. Rassekh CH, Rady PL, Arany I. Combined Epstein-Barr Virus and Human Papillomavirus Infection in Nasopharyngeal Carcinoma. *Laryngoscope*. 1998;108(3):362-7.
10. Tyan YS, Liu ST, Ong WR. Detection of Epstein-Barr virus and human papillomavirus in head and neck tumors. *J Clin Microbiol*. 1993;31(1):53-6.
11. Jiang R, Ekshyyan O, Moore-Medlin T. Association between human papilloma virus/Epstein-Barr virus coinfection and oral carcinogenesis. *J Oral Pathol Med*. 2015;44(1):28-36.
12. Guidry JT, Myers JE, Bienkowska-Haba M. Inhibition of Epstein-Barr Virus Replication in Human Papillomavirus-Immortalized Keratinocytes. *J Virol*. 2019;93(2).
13. Ang KK, Harris J, Wheeler R. Human Papillomavirus and Survival of Patients with Oropharyngeal Cancer. *New Engl J Medicine*. 2010;363(1):24-35.